

KANO

cath 1

ssd (kano city)

female

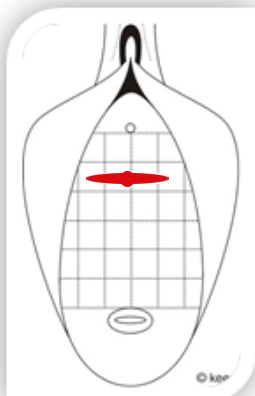
14 yr

29/01-90

diagnosis: PI, scar tissue with minute **IIAa** UVF???, **leaking urine for 25 days** which started immediately following obstructed labor for 3 days in hospital SB male, married 14 mth ago pre(menarche 2 mth later), not living with husband, no h/o drop foot
EUO/AVWSF 2 cm, AVWSF/C 4 cm

29/01-90 FOLEY Ch 16 for 6 wk

26.02.90 not leaking at all healed cath removed bladder drill
16/03-90 not leaking at all, no incontinence, normal miction
insp/ healed, no stress incontinence



minute fistula

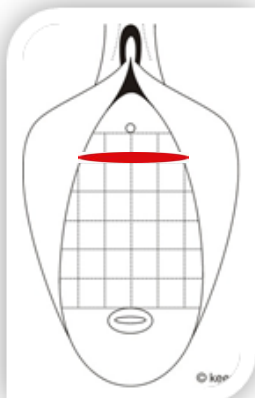
jmr (kano city) female 28 yr 20/03-90

diagnosis: PII (0 alive), severe UV-stricture with overflow incontinence?, scarred avw adherent to symphysis, leaking urine for 2 yr which started immediately following obstructed first labor for 3 days in hospital SB male, married 15 yr ago pre(menarche 3 mth later), still living with husband, normal menstruation, no operation, no h/o drop foot type **IIAa** avw trauma EUO/SAVW 2 cm, SAVW/C 10 cm

20/3-90 dilatation thru H12 and FOLEY Ch for 4-6 wk; for further dilatation and gv testing

17.04.90 not leaking at all cath removed dilatation bladder drill

04/05-90 not leaking at all, no incontinence, normal miction insp/ healed, no stress incontinence



bssd (kano city) female 14 yr 30/07-90

diagnosis: PI, necrotic vesicovaginal fistula **IIAa** midline bladder neck, **leaking urine for 19 days** which started 1 day following obstructed labor for 1 day, in hospital a live male which died shortly afterwards, married 16 mth ago pre(menarche 2 mth later), not with husband, drop foot L (grade 2) EUO/F 5 cm, F/C 4 cm

30/07-90 FOLEY Ch 18; if she really develops a fistula then for closure

27/08-90 clean \pm 8 mm 0 vesicovaginal fistula midline bladder neck; EUO/F 5 cm, F/C 4 cm; application of 1x supramid cross suture anesthetic

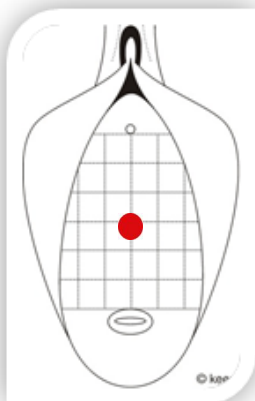
24.09.90 leaking residual 0.8 cm fistula

30/09-90 operation: VVF-repair at 70 days vvf 150

14.10.90 not leaking at all cath removed bladder drill

27/02-91 not leaking at all, no incontinence, normal miction insp/ healed, good elevation, no stress incontinence

30/11-91 **amenorrhea for 6 mth** not leaking at all **instructions**



0.8 cm 0

KANO

cath 4

hakh (kano city)

female

16 yr

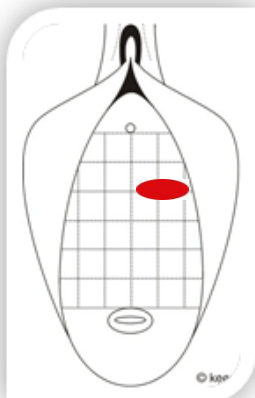
06/08-90

diagnosis: PII (1 alive), necrotic **IIAa** avw L bladder neck, **leaking urine for 23 days** which started 6 days following obstructed last labor for 5 days, in hospital SB male, married 3.5 yr ago pre(menarche 2 mth later), not living with husband, no h/o drop foot; full bladder EUO/AVWN 2,5 cm, AVWN/C 4 cm

06/08-90 FOLEY Ch 22

20.08.90 not leaking at all insp/ healed cath removed bladder drill

27/08-90 not leaking at all, no incontinence, normal miction insp/ healed, no stress incontinence



KANO

cath 5

hab (kano)

female

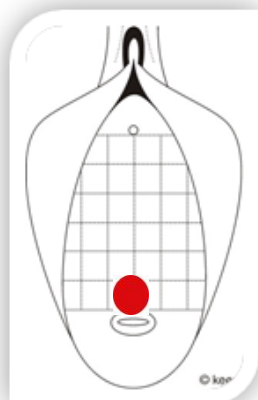
19 yr

06/08-90

diagnosis: PIV (0 alive), \pm 1.5 cm 0 avw defect just in front of cervix I, leaking urine for 3 mth which started immediately following CS b.c.o. obstructed last labor for 2 days, live male infant which died same day, married 6 yr ago pre(menarche 2 mth later), not living with husband, no menstruation, drop foot L (grade 3); N.B. still decubitus ulcer sacrum; full bladder EUO/AVWD 10 cm, AVWD/C 0 cm

06/08-90 FOLEY Ch 22

10/09-90 not leaking at all insp/ healed catheter removed



1.5 cm 0

KANO

cath 6

sar (kano) female 28 yr 07/08-90

diagnosis: PII (0 alive), ± 5 mm 0 vesicovaginal fistula I midline bladder base, **leaking urine for 2 mth** which started immediately following obstructed last labor for 3 days, in hospital SB female, married 15 yr ago post(men arche 1 mth earlier), not living with husband, no h/o drop foot EUO/F 6 cm, F/C 7 cm

07/08-90 adaptation anesthetic closure with 1x supramid cross suture and FOLEY Ch 22

10.09.90 not leaking at all cath removed bladder drill

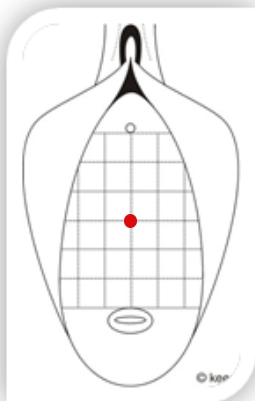
24/09-90 not leaking at all, no incontinence, normal miction so insp/ healed, no stress incontinence

second obstetric fistula completely ok until PIII (0 alive) sb male at home
18/01-93 operation: VVF-repair VVF 494

03.05.93 not leaking at all, no incontinence, normal miction insp/ healed, good elevation, no stress incontinence

12.07.93 idem

23.08.93 not leaking at all, no incontinence, normal miction healed, no stress



0.5 cm 0

KANO
genuine intrinsic_stress incontinence 13.05.13

cath 7

aalm (kano city) female 15 yr 31/07-90

diagnosis: PI, stress incontinence, leaking urine for 3 mth when standing/ walking but not when sitting/lying unless coughing which started immediately following obstructed labor for 2 days, in hospital a live male, married 2 yr ago pre(menarche 1 mth later), still living with husband, no h/o drop foot; also slight UV-stricture

31/7-90 dilatation of slight uv-stricturte thru H10 and FOLEY Ch 16

14.08.90 not leaking at all insp_gv/ not leaking, incontinence + cath removed

urine stress incontinence grade II

02/10-90 operation: anterior colposuspension

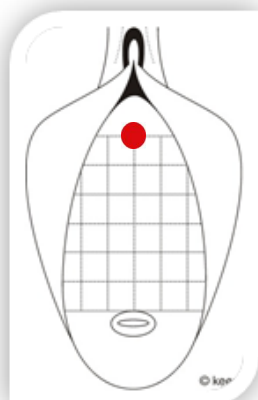
VVF 159

08.10.90 started to bleed yesterday insp/ complete abortion
4 pints of blood ergometrine/syntocinon

09.10.90 not bleeding at all

16.10.90 not leaking at all cath removed bladder drill

14/11-90 not leaking at all, no incontinence, normal miction
insp/ healed, good elevation, stress incontinence \pm



symb (kano) female 21 yr 19/08-90

diagnosis: PIV (0 alive), severe UV stricture with \pm 2 mm 0 urethrovesicovaginal **IIAa** fistula midline, leaking urine for 9 mth which started immediately following obstructed last labor for 4 days, in hospital a SB male, married 10 yr ago pre(menarche 1.5 yr later), still living with husband, no menstruation, bilateral drop foot for 2 mth, severe vagina shortening, cervix opening at vault
EUO/F 2.5 cm, F/C 2.5

surgeon: Kees WAALDIJK

operation: dilatation and 1x supramid

duration: 5 min

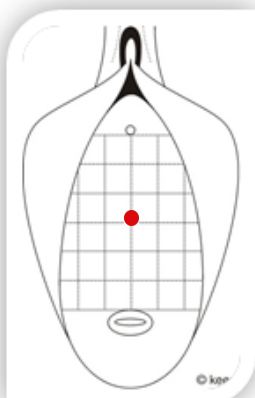
anesthesia: spinal L3/L4 and L4/L5 with 4 ml resp 3 ml bupivacaine 0.5%

easy dilatation from H5 thru H12, FOLEY Ch 22; then it is noted that there is also a 2 mm 0 fistula (probably opened up by dilatation), 1x supramid cross suture

0.5 cm fistula

30/09-90 operation: UVF/VVF-repair vvf 151

- 14.10.90 ?leaking? cath removed bladder drill
- 22.10.90 leaking/incontinence & miction healed, no stress
- 19.12.90 not leaking, incontinence \pm , miction healed, no stress
- 19.01.91 not leaking at all, no incontinence, normal miction
insp/ **both** healed, no stress incontinence
- 13.02.91 idem
- 22.05.91 not leaking at all, no incontinence, normal miction healed, no stress



0.2 cm

aagd (kano city)

female

16 yr

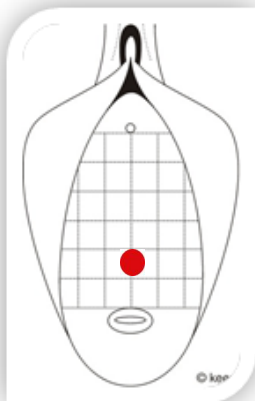
20/08-90

diagnosis: PII (1 alive), \pm 1 cm 0 necrotic vesicovaginal fistula midline bladder base
I, leaking urine for 12 days which started 2 days following obstructed
last labor for 2 days, in hospital a live male, married 3 yr ago
pre(menarche 4 mth later), still living with husband, no drop foot
EUO/F 7 cm, F/C 2 cm

20/8-90 FOLEY Ch 22; later for suturing when clean

05/09-90 adaptation leaking urine for 28 days
now clean \pm 5 mm 0 fistula; 1x supramid cross suture anesthetic

22.10.90 not leaking at all insp/ healed cath removed so
28/10-90 not leaking at all, no incontinence, normal miction
insp/ healed, no stress incontinence



1 cm 0

KANO

cath 10

titm (kano city)

female

15 yr

05/09-90

diagnosis: PI, ± 1 cm 0 urethrovesicovaginal fistula **IIAa**, **leaking urine for 2 mth which started 17 days** following obstructed labor for 2 days in hospital SB male, married 2 yr ago pre(menarche 3 mth later) not living with husband, no menstruation, no h/o drop foot
EUO/F 2 cm, F/C 6 cm

anesthesia: spinal L3/L4 with 4 ml bupivacaine 0.5%

05/09-90 adaptation

anesthetic

2x supramid cross sutures and FOLEY Ch 18

22..10.90 not leaking at all insp/ 1 cm fistula **IIAa**

30/10-90 operation: UVVF-repair

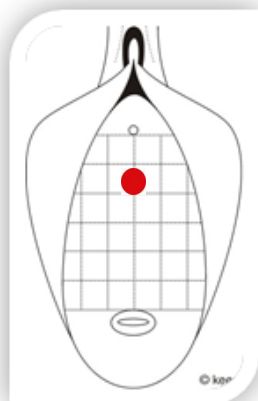
VVF 183

13.11.90 not leaking at all cath removed bladder drill

19.11.90 not leaking at all, no incontinence, normal miction
insp/ healed, good elevation, no stress incontinence

28.11 + 05.12 + 16.01 + 27.02.91 idem

11.07.91 not leaking at all, no incontinence, normal miction healed, no stress



1 cm 0

takb (kano city)

female

14 yr

05/09-90

diagnosis: PI, ± 2x1 cm urethrovesicovaginal **IIAa** fistula, **leaking urine for 24 days** which started immediately following obstructed labor for 1 day, in hospital live female, married 2 yr ago pre(menarche 6 mth later), still living with husband, no h/o drop foot
EUO/F 2 cm, F/C 6 cm

05/09-90

adaptation

1x supramid longitudinal cross suture and FOLEY Ch 20

anesthetic

residual 2x1 cm fistula

15/10-90

operation: UVVF-repair

vvf 170

09.11.90 not leaking at all cath removed bladder drill

15.11.90 not leaking at all, no incontinence, normal miction

insp/ healed, good elevation, no stress incontinence

05.12 + 27.02 + 10.04.91 idem

12.06.91 not leaking at all, no incontinence, normal miction

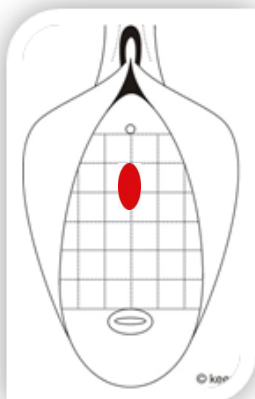
healed, no stress

17/06-92

amenorrhea for 5 mth

not leaking at all

instructions



2x1 cm

KANO

cath 12

aag (kano)

female

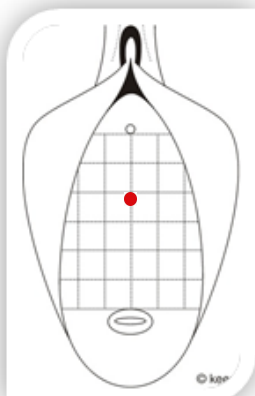
30 yr

05/09-90

diagnosis: PIX (3 alive), minute vesicovaginal fistula **IIAa** at midline bladder neck, **leaking urine for 54 days** which started 5 days following obstructed last labor for 1 day, in hospital SB male, married 18 yr ago pre(menarche 1 yr later), not lwith husband, no menstruation, no h/o drop foot
EUO/F 4 cm, F/C 6 cm

05/09-90 FOLEY Ch 22

08/10-90 not leaking at all catheter removed
insp/ healed



minute fistula

vabb (kano city)

female

18 yr

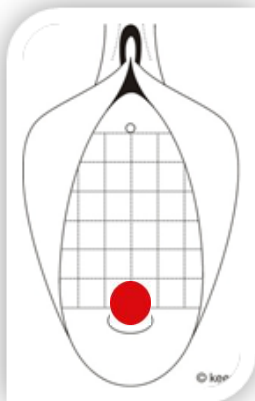
30/09-90

diagnosis: PII (0 alive), \pm 2.5 cm CS-vesicocervicovaginal fistula I, **leaking urine for 33 days which started 6 days** following CS(-hysterectomy) b.c.o. obstructed last labor for 1 day, SB female, married 4 yr ago post(menarche 1 yr earlier), still living with husband, no menstruation, no h/o drop foot, only some cervix remnants left posteriorly, no cervix canal
EUO/F 10 cm, F/C? 0 cm

30/9-90 adaptation

4x everting supramid and FOLEY Ch 18; free urine flow (no loin pain);
only adaptation anesthetic

- 22.10 + 05.11.90 not leaking at all cath removed bladder drill
- 05.12.90 not leaking at all, no incontinence, normal miction
insp/ healed, no stress incontinence
- 19.12 + 23.01.90 idem
- 15.08.91 not leaking at all, no incontinence, normal miction healed, no stress



2.5 cm

adldk (kano city)

female

12 yr

08/10-90

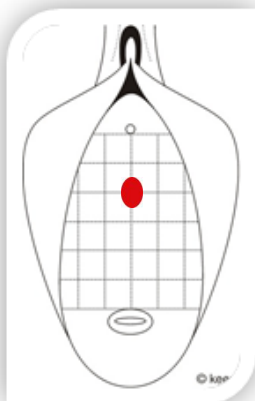
diagnosis: P0, ± 1.5x1 cm urethrovaginal fistula, **leaking urine of 20 days** which started immediately following yankan gishiri by unguzoma b.c.o. some "growth" inside vagina (ba hanya??), married 7 mth ago pre (still no menarcho, but breasts and pubic hair), not living with husband
EUO/F 2 cm, F/C 4 cm

08/10-90 adaptation

2x longitudinal supramid cross sutures and FOLEY Ch 18 anesthetic

16/11-90 not leaking at all ?healed? cath removed bladder drill

06.12.90 not leaking at all, no incontinence, normal miction
insp/ healed, no stress incontinence



1.5x1 cm

hamdk (kano city)

female

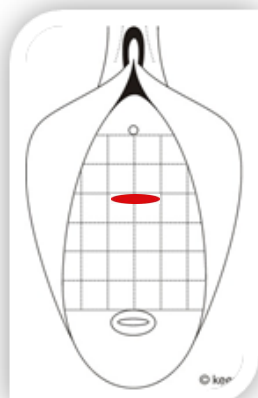
16 yr

08/10-90

diagnosis: PI, scar tissue at bladder neck with minute vesicovaginal **IIAa** fistula? fixed to symphysis, leaking urine for 4 mth which started immediately following obstructed labor for 2 days, in hospital SB male, married 3 yr ago pre(menarche 5 mth later), not living with husband, no menstruation, drop foot R (grade 2)
EUO/SAVW 4 cm, SAVW/C 6 cm

08/10-90 FOLEY Ch 18

22.10.90 not leaking at all cath removed bladder drill
29/10-90 not leaking at all, no incontinence, normal miction
insp/ healed, no stress incontinence menstruation



KANO

cath 16

rsb (kano city)

female

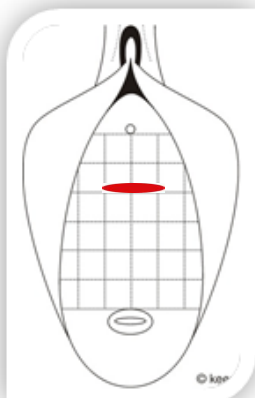
17 yr

30/10-90

diagnosis: PI, total urine stress incontinence or overflow incontinence, scarred avw over bladder neck and fixed to symphysis, **leaking urine day/ night for 2 mth** which started immediately following obstructed labor for 2 days, in hospital a live female, married 4 yr ago post(menarche 3 mth earlier), not living with husband, no menstruation, no h/o drop foot, no UV-stricture EUO/SAVW 3 cm, SAVW/C 6 cm

30/10-90 FOLEY Ch 18 for 4 wk; full bladder!!!

05.11 + 05.12.90	not leaking at all	cath removed	bladder drill
19.12.90	not leaking at all, no incontinence, normal miction insp/ healed, no stress incontinence		
30.01.91	idem		
22.04.91	not leaking at all, no incontinence, normal miction		healed, no stress



KANO

cath 17

from atonic bladder into urine stress incontinence

hmb (kano) female 32 yr 05/11-90

diagnosis: PVII (3 alive), overflow incontinence due to atonic bladder, **leaking urine for 3 wk** which started 7 days following obstructed last labor for 1 day, at home live female, married 20 yr ago pre(menarche 1 yr later), still living with husband, no h/o drop foot; bladder totally overfilled

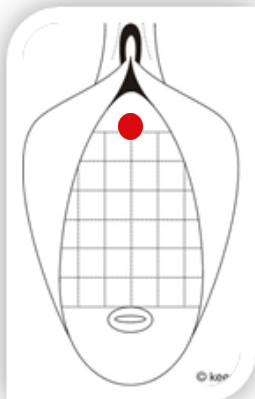
5/11-90 FOLEY Ch 18 for 4 wk

urine stress incontinence grade II

08/04-91 operation: colposuspension

VVF 238

- 08.05.91 not leaking at all cath removed bladder drill
- 22.05.91 not leaking at all, no incontinence, normal miction
insp/ healed, good elevation, no stress incontinence
- 19.06.91 idem
- 19.09.91 not leaking at all, no incontinence, normal miction



mun (bauchi)

female

15 yr

16/11-90

diagnosis: PI, \pm 2 cm 0 urethrovesicovaginal fistula midline bladder neck **IIAa**, very small proximal rectovaginal fistula, **leaking urine/passing stools per vaginam for 20 days** which started immediately following obstructed labor for 5 days, at home SB male, married 3 yr ago pre(menarche 7 mth later), not with husband, drop foot R (grade 2) and L (grade 4) EUO/F 3 cm, F/C 4 cm

16/11-90

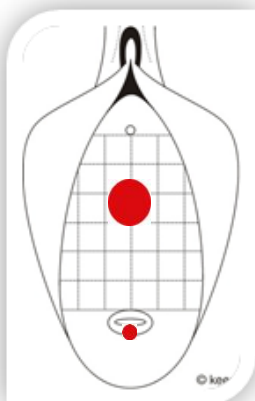
adaptation

rvf will heal spontaneously

3x transverse supramid cross sutures and FOLEY Ch 20

anesthetic

both healed



2 cm

Zmb

female

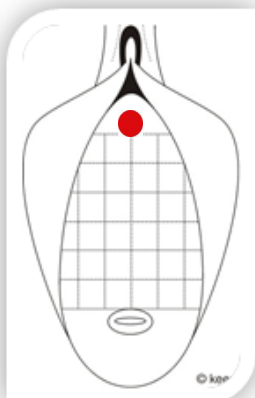
12 yr

07/03-91

diagnosis: P0, overflow incontinence due to UV-stricture, leaking urine for 6 mth which started 3 days following rape, not married, no menarche yet, developing breasts, scanty pubic hair

07/03-91 dilatation thru H10 and FOLEY Ch 18

15/04-91 not leaking at all catheter removed



KANO
development of ^ avw trauma 13.05.13

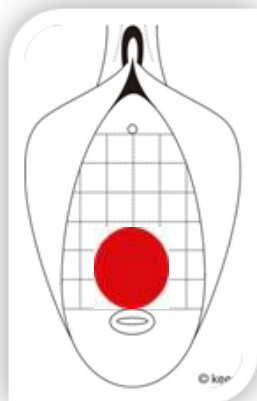
cath 20

bigm (kano city) female 14 yr 08/04-91

diagnosis: PI, \pm 4 cm triangular healing vesicovaginal fistula bladder base/neck, **leaking urine for 30 days** which started immediately following obstructed labor for 6 days, in hospital SB male, married 2 yr ago pre(menarche 6 mth later), still living with husband, no h/o drop foot; gv: no leakage but incontinence
EUO/F 5 cm, F/C 0 cm

08/04-91 FOLEY Ch 18 for 6 wk

15.05 + 22.05.91 not leaking at all cath removed bladder drill
19/06-91 not leaking at all, no incontinence, normal miction
insp/ healed, no stress incontinence



4 cm

KANO

cath 21

tum (kano)

female

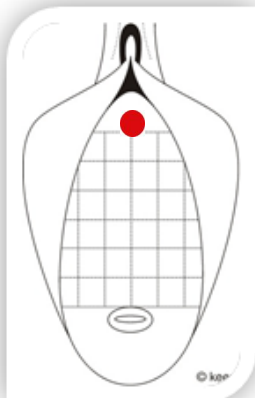
21 yr

22/04-91

diagnosis: PIII (0 alive), overflow incontinence due to atonic bladder, leaking urine for 3 mth which started 1 day following obstructed last labor for 1 day, in hospital SB male, married 8 yr ago pre(menarche 2 mth later), not living with husband, no menstruation, drop foot R (grade 3)

22/04-91 FOLEY Ch 18 for 4 wk

19/06-91 not leaking at all cath removed bladder drill



mayk (kano city)

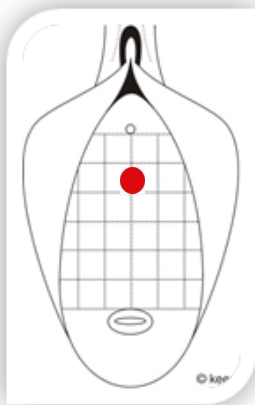
female 15 yr

10/10-91

diagnosis: PI, \pm 5 mm 0 urethrovesicovaginal fistula midline **IIAa** bladder neck, **leaking urine for 14 days** which started 3 days following an obstructed labor for 4 days, in hospital SB male, married 1.5 yr ago post(menarche 2 mth earlier), not living with husband, no h/o drop foot
EUO/F 3 cm, F/C 7 cm

10/10-91 FOLEY Ch 18

12.11.92 not leaking at all healed cath removed bladder drill
19.11.91 not leaking at all, no incontinence, normal miction
insp/ healed, no stress incontinence
19.01.92 not leaking at all, no incontinence, normal miction healed, no stress



0.5 cm

adb (kano)

female

15 yr

12/11-91

diagnosis: PI, ± 5 mm 0 urethrovesicovaginal fistula **IIAa** midline bladder neck, leaking urine for 3 mth which started 14 days following an obstructed labor for 1 day, at home SB male, married 2 yr ago pre (menarche 2 mth later), not living with husband, no menstruation, no h/o drop foot
EUO/F 3.5 cm, F/C 5 cm

12/11-91

adaptation

2x supramid adaptation sutures and FOLEY Ch 18

anesthetic

residual 0.5 cm fistula

30/12-91

operation: VVF-repair

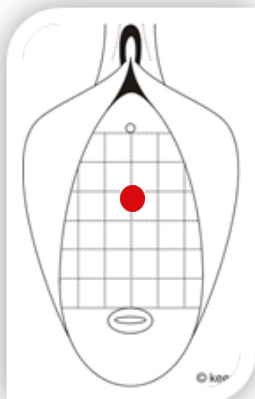
vvf 252

13.01.92 not leaking at all cath removed bladder drill

21.01.92 not leaking at all, no incontinence, normal miction

insp/ healed, moderate elevation, no stress incontinence

23.02.92 not leaking at all, no incontinence, normal miction healed, no stress



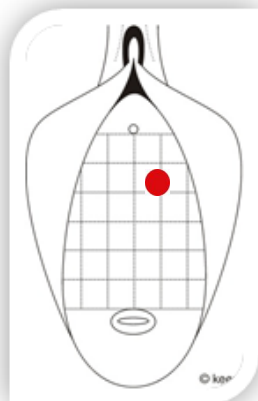
0.5 cm

jkk (kano) female 15 yr 12/11-91

diagnosis: PI, ± 5 mm 0 urethrovesicovaginal fistula L bladder neck **IIAa**, leaking urine for 3 mth which started 20 days following forceps delivery b.c.o. obstructed labor for 1 day, live male which died 1 hr later, married 3 yr ago pre(menarche 1 yr later), not living with husband, no menstruation, drop foot L (grade 3)
EUO/F 3 cm, F/C 8 cm

12/11-91 adaptation
2x supramid adaptation sutures and FOLEY Ch 18 anesthetic

16.12.91 not leaking at all cath removed bladder drill
30.12.91 not leaking at all, no incontinec, normal miction
insp/ healed, no stress incontinence menstruation
14.01.92 idem
01.03.92 not leaking at all, no incontinence, normalmiction healed, no stress



0.5 cm

fsg (kano)

female

24 yr

15/11-91

diagnosis: PIII (1 alive), ± 1 cm 0 vesicovaginal fistula **IIAa** midline bladder neck, **leaking urine for 1 mth which started 9 days** following CS b.c.o. obstructed last labor (ruptured uterus) for 3 days, SB male, married 12 yr ago pre(menarche 6 mth later), not living with husband, no menstruation (uterus was repaired), drop foot L (grade 3-4); leaking started upon removal of catheter so she might have had the fistula long before
EUO/F 4 cm, F/C 5 cm

15/11-91 adaptation

2x supramid adaptation sutures and FOLEY Ch 18

anesthetic

residual 0.1 cm fistula

30/12-91 operation: VVF-repair

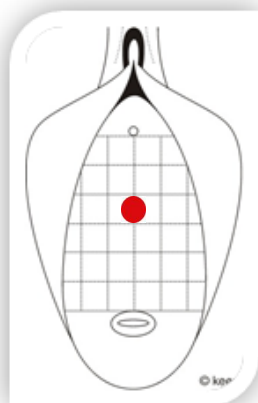
vvf 253

13.01.92 not leaking at all cath removed bladder drill

21.01.92 not leaking at all, no incontinence, normal miction
insp/ healed, good elevation, no stress incontinence

01.03.92 idem

06.07.92 not leaking at all, no incontinence, normal miction healed, no stress



1 cm

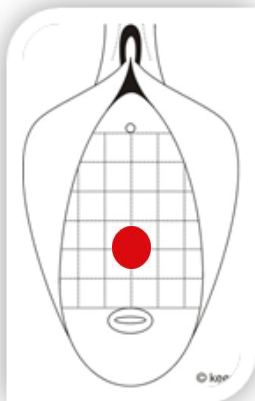
"closure" of avw by everting supramid

znb (kano city) female 15 yr 23/12-91

diagnosis: PI, ± 2 cm 0 vesicovaginal fistula R and midline bladder base I, leaking urine for 3 mth which started 5 days following obstructed labor for 3 days, in hospital SB female, married 2 yr ago post(menarche 2 mth earlier), not living with husband, no menstruation, no h/o drop foot
EUO/F 6 cm, F/C 2 cm

23/12-91 adaptation by everting supramid
3x everting supramid and FOLEY Ch 18 anesthetic

- 03.02.92 not leaking at all cath removed bladder drill
- 04/02-92 not leaking, no incontinence, normal miction
insp/ healed, !urine in vaginae!
- 25.02.92 insp_gv: 2 cm fistula
- 25/02-92 operation: VVF-repair vvf 317**
- 26.03.92 not leaking at all cath removed bladder drill
- 06.04.92 not leaking at all, no incontinence, normal miction
insp/ healed, good elevation, no stress incontinence
- 14.07.92 idem
- 18.10.92 not leaking at all, no incontinence, normal miction healed, no stress
- 19/04-93 **amenorrhea for 4 mth** not leaking at all **incontinence**



2 cm

bar (jigawa)

female

31 yr

23/12-91

diagnosis: PI, ± 5 mm 0 vesicovaginal fistula **IIAa** at L bladder neck, **leaking urine for 2 mth** which started immediately following obstructed labor for 3 days, in hospital SB female, married 18 yr ago pre(menarche 2 mth later), not living with husband, no menstruation, no h/o drop foot
EUO/F 5 cm, F/C 6 cm

23/11-91 adaptation

3x everting supramid and FOLEY Ch 18

anesthetic

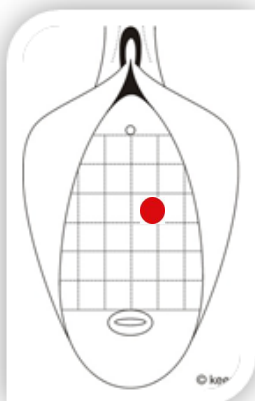
01/02-92 pat has been blocking catheter leaking insp/ **fistula**

04/02-92 operation: VVF-repair

vvf 290

18.02.92 not leaking at all cath removed bladder drill

24/02-92 not leaking at all, no incontinence, normal miction
insp/ healed, good elevation, no stress incontinence



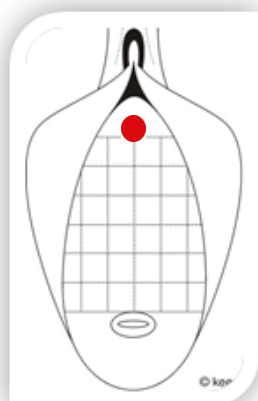
0.5 cm

fig (kano) female 26 yr 23/12-91

diagnosis: PI, total urine stress incontinence, slight UV-stricture, leaking urine for 2 yr which started immediately following obstructed labor for 2 days, N.B. at home live female, married 15 yr ago pre(menarche 2 yr later), not living with husband, normal menstruation, no h/o drop foot; N.B. operated 1x in ZARIA and 1x in KATSINA d.d. 19/6-86 b.c.o. yankan gishiri

23/12-91 easy dilatation and FOLEY Ch 18; gv: no leakage but overflow or stress incontinence

26/01-92 pat insisted 10 days ago that catheter had to be removed sent home



KANO

cath 30

bdkh (kano city) female 31 yr 30/12-91

diagnosis: PV (4 alive), ± 8 mm 0 vesicovaginal fistula with granulations at R bladder base, **leaking urine for 2 mth** which started 3 days following obstructed last labor for 2 days, in hospital SB male married 20 yr ago pre(menarche 2 yr later), still living with husband, no menstruation, drop foot L for 1 mth (now grade 5) type I
EUO/F 6 cm, F/C 5 cm 156.0 cm

30/12-91 adaptation 3x everting supramid and FOLEY Ch 18 anesthetic

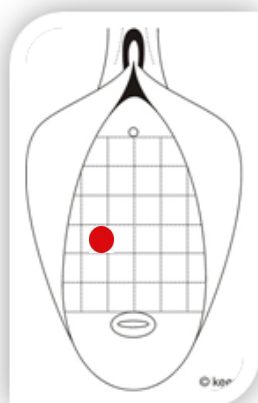
13.01 + 11.02.92 not leaking at all cath removed bladder drill
24/02-92 not leaking at all, no incontinence, normal miction
insp/ healed, no stress incontinence

second obstetric fistula completely ok until PVI (5 alive) live female home
30.09.93 cath + ps cath 256

17.10 + 31.10.93 not leaking at all cath removed bladder drill
07.11.93 not leaking at all, no incontinence, normal miction
insp/ healed, good elevation, no stress incontinence
21.11.93 idem
17.04.94 not leaking at all, no incontinence, normal miction healed, no stress

third obstetric fistula completely ok until PVIII (7 alive) live female at home
23/09-96 operation: UVVF-repair VVF 1372

07.10 + 21.10.96 not leaking at all cath removed bladder drill
28.10.96 not leaking at all, no incontinence, normal miction
insp/ healed, good elevation, no stress incontinence
11.12.96 idem
13.05.97 not leaking at all, no incontinence, normal miction healed, no stress



0.8 cm

KANO

cath 31

aum (kano) female 22 yr 07/01-92

diagnosis: PVI (3 alive), small \pm 1 mm 0 vesicovaginal fistula I at vagina vault, **leaking urine for 35 days** which started 4 days following CS(-hysterectomy) b.c.o. obstructed last labor for 2 days, live female, married 10 yr ago pre(menarche 1 yr later), still livving with husband, no menstruation, no h/o drop foot; fistula demonstrated by gv EUO/F 12 cm, F/V 0 cm 158.0 cm

07/01-92 FOLEY Ch 18

17.02.92 not leaking at all urine in vaginae cath removed drill
22/03-92 once in a while lekaing $\pm\pm$ with full bladder, normal miction insp/ healed, **no** urine in vaginae, no stress incontinence

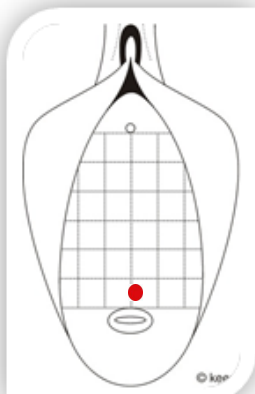
07/09-92 leaking **??sex??**
residual 0.5 cm fistula

22/12-92 operation: VVF-repair VVF 474

12.01.93 not leaking at all cath removed bladder drill

25.01.93 not leaking at all, no incontinence, normal miction insp/ healed, poor elevation, no stress incontinence

03.05.93 not leaking at all, no incontinence, normal miction healed, no stress



minute fistula

aurk (kano city)

female

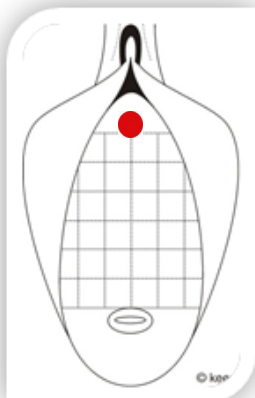
15 yr

07/01-92

diagnosis: PI, total urine stress incontinence, **leaking urine for 1 mth** which started 1 mth following obstructed labor for 1 day, in hospital live male, married 2 yr ago pre(menarche 3 mth later), not living with husband, no menstruation (lactation), no h/o drop foot 154.0 cm

07/01-92 FOLEY Ch 18

03.02.92 not leaking at all cath removed bladder drill
23/02-92 not leaking at all, no incontinenc, normal miction
insp/ healed, no stress incontinence



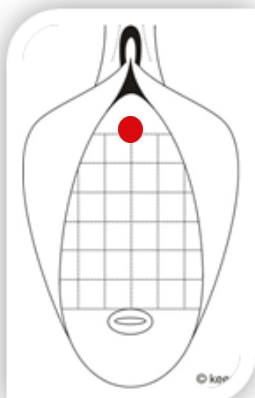
tmt (kano) female 14 yr 13/01-92

diagnosis: PI, overflow incontinence due to atonic bladder, pt is not able to pass urine herself, **leaking urine for 20 days** which started 2 days following obstructed labor for 1 day, in hospital an SB male, married 1 yr ago post(menarche 2 mth earlier), not living with husband, no h/o drop foot; bladder completely overfilled, > 1000 ml urine 154.0 cm

13/1-92 FOLEY Ch 18

11.02.92 not leaking at all cath removed bladder drill
01/03-92 not leaking at all, no incontinence, normal miction
insp/ healed, no stress incontinence

04/10-92 **amenorrhea for 4 mth** not leaking at all **instructions**



KANO

cath 34

simb (kano)

female

15 yr

14/01-92

diagnosis: PI, ± 2 cm 0 urethrovesicovaginal fistula with circumferential defect **IIAb**, **leaking urine for 31 days** which started 10 days following craniotomy b.c.o. obstructed labor for 2 days, SB female, married 2 yr ago pre(menarche 4 mth later), not living with her husband, no menstruation, drop foot R (grade 3) and L (grade 3)
EUO/F 3 cm, F/C 6 cm 148.0 cm

14/01-92 adaptation

5x everting supramid and FOLEY Ch 18

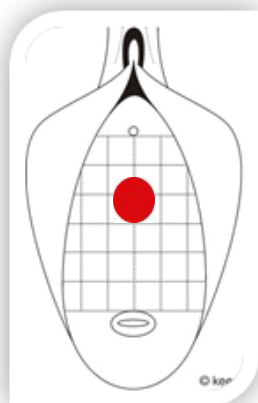
anesthetic

17.02.92 not leaking at all cath removed bladder drill
02/03-92 not leaking, no incontinence, normal miction
insp/ healed, ?urine in vaginae?, no stress incontinence

14/07-92 now leaking & normal miction **??sex??**
residual 2 cm **fistula**

23/07-92 operation: "circumferential" UVVF-repair vuf 381

16.08.92 not leaking at all cath removed bladder drill
23.08.92 not leaking at all, no incontinence, normal miction
insp/ healed, good elevation, no stress incontinence
21.09.92 not leaking at all, no incontinence, normal miction healed, no stress



2 cm

KANO

cath 35

aud (kano)

female

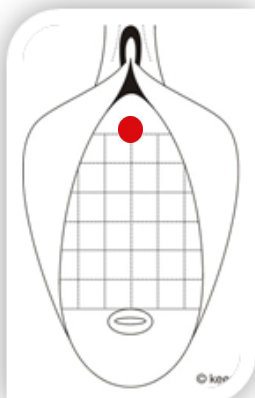
14 yr

19/01-92

diagnosis: PI, overflow incontinence due to atonic bladder, **leaking urine continuously for 2 mth** which started immediately following obstructed labor for 2 days, at home SB male, married 1 yr ago post(menarche 1 mth earlier), not with husband, no menstruation, no h/o drop foot; bladder completely overfilled with > 1500 ml urine 149.0 cm

14/1-92 FOLEY Ch 18

17.02.92 not leaking at all cath removed bladder drill
18.02.92 not leaking at all, no incontinence, normal miction
insp/ healed, no stress incontinence
22.03.92 not leaking at all, no incontinence, normal miction healed, no stress



freshening and everting "closure" of avw

uad (kano city) female 22 yr 28/01-92

diagnosis: PIII (2 alive), ± 3x1 cm avw defect over urethra with 1 cm 0 UVF and 1 mm 0 UVF, **leaking urine for 49 days** which started immediately following yankan gishiri by unguzoma b.c.o. cystocele (something came out), married 10 yr ago pre(menarche 6 mth later), not living with husband
EUO/AVWD 1 cm, AVWD/C 8 cm 157.0 cm

28/01-92 primary suturing anesthetic
freshening, 6x everting longitudinal supramid and FOLEY Ch 18

residual 3x1 cm fistula

16/03-92 operation: urethra reconstruction **vvf 323**

30.03.92 not leaking at all cath removed bladder drill
15.04.92 not leaking at all, no incontinence, normal miction
insp/ healed, good elevation, no stress incontinence
06.09.92 not leaking at all, no incontinence, normal miction healed, no stress

new now obstetric fistula completely ok until PIV (3 alive) live female at home

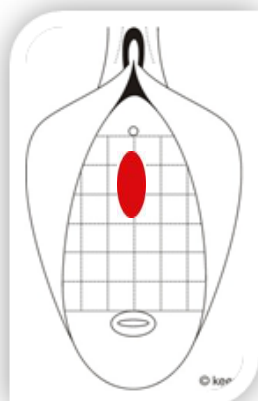
01/03-94 operation: VVF-repair **vvf 748**

15.03.94 not leaking at all cath removed bladder drill
20.03.94 not leaking at all, no incontinence, normal miction
insp/ healed, good elevation, no stress incontinence
03.04 + 01.05.04 idem
03.07.04 not leaking at all, no incontinence, normal miction healed, no stress

third obstetric fistula completely ok until PV (4 alive) live female at home

21.06.99 operation: uvvf-repair obst 2nd yankan gishiri **vvf 1876**

04.07 + 18.07.04 not leaking at all cath removed bladder drill
03.08.99 not leaking at all, no incontinence, normal miction
insp/ healed, good elevation, no stress incontinence
16.08 + 22.10.99 idem
09.01.00 not leaking at all, no incontinence, normal miction healed, no stress



3x1 cm

sahs (jigawa)

female

17 yr

02/02-92

diagnosis: PI, ± 2x0.5 cm urethrovesicovaginal fistula **IIAa** with avw stricture, leaking urine for 4 mth which started immediately following obstructed labor for 2 days, in hospital SB male, married 4 yr ago pre(menarche 5 mth later), not living with husband, no menstruation, drop foot L (grade 2)
 EUO/F 3 cm, F/C 6 cm 149.5 cm

02/02-92

primary suturing

4x everting supramid and FOLEY Ch 18

anesthetic

residual 1 cm fistula

13/04-92

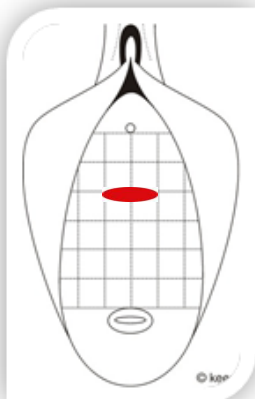
operation: UVVF-repair

vvf 336

28.04.92 not leaking at all cath removed bladder drill

13.07.92 not leaking, incontinence ++, normal miction healed, stress ++

23/09-92 not leaking, incontinence ++, normal miction
 insp/ healed, good elevation, no stress incontinence



2x0.5 cm

nb pat had a cerebrovascular accident and is not fit for anesthesia

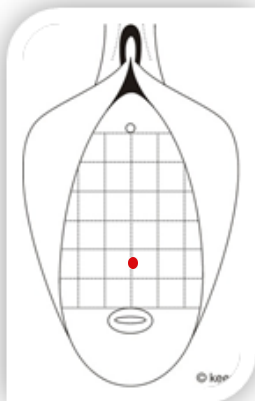
fag (zamfara) female 61 yr 18/02-92

diagnosis: PVI (3 alive), ± 2 mm 0 vesicovaginal fistula I midline bladder base, leaking urine for 25 yr which started immediately following obstructed last labor for 2 days, at home SB female, married 50 yr ago pre(menarche 2 yr later), still living with her husband, menopause 15 yr ago, no h/o drop foot;
EUO/F 7 cm, F/C 2 cm 160.5 cm

18/02-93 primary suturing
freshening, 3x everting supramid and FOLEY Ch 18 anesthetic

11.03.92 cath out x 11/7 not leaking at all, no incontinenexe, normal miction
Insp/ healed

06/04-92 not leaking at all, no incontinence, normal miction
insp/ healed, no stress incontinence



0.2 cm

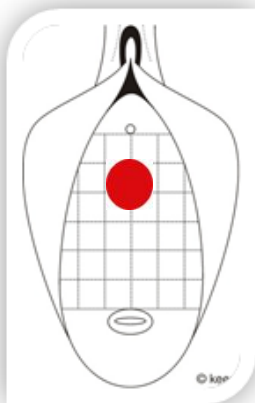
dddt (kano) female 25 yr 18/02-92

diagnosis: PIII (0 alive), ± 3 cm 0 urethrovesicovaginal fistula with circumferential defect, **leaking urine for 33 days** which started 11 days following CS b.c.o. obstructed last labor for 2 days, SB male, married 15 yr ago pre(menarche 2 yr later), not living with husband, drop foot R (grade 4); atonic bladder as well type **IIAb**
EUO/F 2 cm, F/C 7 cm 143.0 cm

18/02-92 primary suturing
freshening, 5x everting supramid and FOLEY Ch 18; this is only a try as well as for bladder atony anesthetic

22/03-92 catheter out this morning leaking ± & normal miction
healed still overflow incontinence FOLEY Ch 18

09/06-92 not leaking at all, no incontinence, normal miction
insp/ healed, no stress incontinence



3 cm

KANO
vucvf without ever cs

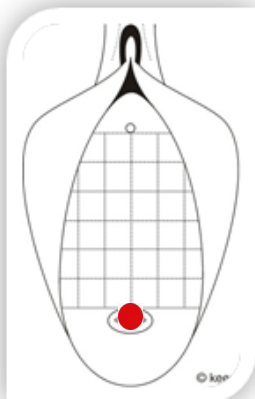
cath 40

hadt (kano city) female 31 yr 18/02-92

diagnosis: PVIII (6 alive), vesico(utero)cervicovaginal fistula I as demonstrated by 50 ml gv which comes little out of cervix opening, **leaking urine for 21 days** which started 20 days following obstructed last labor for 1 day, at home SB female, married 18 yr ago pre(menarche 5 mth later), still living with husband, drop foot R (grade 4) 163.0 cm
N.B. pat never had CS but still now VUCVF!!!
EUO/F 8 cm, F/C 0 cm

18/02-92 FOLEY Ch 18

11.03 + 06.04.92 not leaking at all cath removed bladder drill
15.04.92 not leaking at all, no incontinence, normal miction
insp/ healed, no stress incontinence
09/06-92 not leaking at all, no incontinence, normal miction
insp/ healed, no stress incontinence
!menstruation but no blood in urine!



KANO

cath 41

agw (kano)

female

28 yr

18/02-92

diagnosis: PVII (4 alive), \pm 1 cm 0 vesicovaginal fistula L bladder neck **IIAa**, leaking urine for 3 mth which started 11 days following an obstructed last labor for 3 days, in hospital live male, married 17 yr ago pre(menarche 2 yr later), still living with husband, no menstruation (lactation), no h/o drop foot
EUO/F 5 cm, F/C 2 cm 150.0 cm

18/02-92

primary suturing

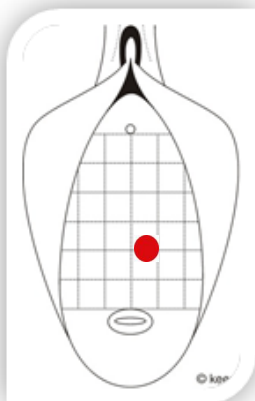
freshening, 3x everting supramid and FOLEY Ch 18

anesthetic

11.03 + 15.04.92

not leaking at all

catheter removed



1 cm

KANO

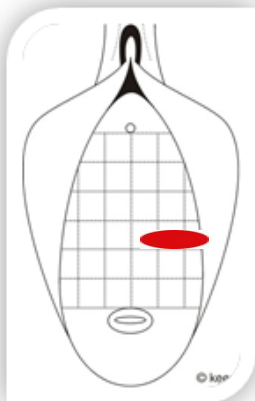
cath 42

magi (kano) female 18 yr 18/02-92

diagnosis: PIII (0 alive), ± 2.5x1 cm vesicovaginal **IIAa** fistula L bladder neck **leaking urine for 46 days** which started immediately following obstructed last labor for 3 days, in hospital a live male, married 6 yr ago pre(menarche 1 yr later), not with husband no menstruation, drop foot L (grade 4)
EUO/F 5 cm, F/C 3 cm 148.5 cm

18/02-92 primary suturing
5x everting supramid and FOLEY Ch 18 anesthetic

07.04.92 not leaking at all cath removed bladder drill
15/04-92 not leaking at all, no incontinence, normal miction
insp/ healed, good elevation, no stress incontinence
09/06-92 now leaking insp_gv/ minimal leakage **?early sex?**
28/07-92 operation: VVF-repair vvf 386
11.08.92 not leaking at all cath removed bladder drill
17.08.92 not leaking at all, no incontinence, normal miction
insp/ healed, good elevation, no stress incontinence
23.09.92 idem
18.01.93 not leaking at all, no incontinence, normal mition healed, no stress



2.5x1 cm

mmi (katsina)

female

15 yr

24/02-92

diagnosis: PI, \pm 3x2 cm urethrovesicovaginal fistula with circumferential defect **IIAb**, **leaking urine for 52 days** which started immediately following obstructed labor for 1 day, in hospital SB male, married 2 yr ago post(menarche 6 mth earlier), not living with husband, no menstruation, drop foot R (grade 3)

EUO/F 2 cm, F/C 6 cm

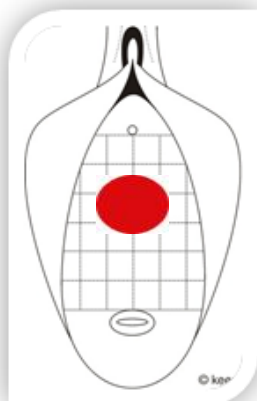
155.5 cm

24/02-92 primary suturing

freshening, 5x everting supramid and FOLEY Ch 18

anesthetic

11.03 + 06.04.92 leaking healed cath removed bladder drill
06.07.92 not leaking, incontinence \pm (fluor), normal miction
insp/ healed, good elevation, no stress incontinence



3x2 cm

KANO

cath 44

bhg (kano city)

female

16 yr

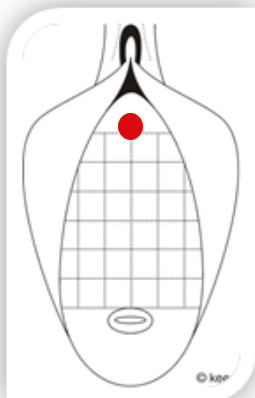
24/02-92

diagnosis: PII (0 alive), total urine stress incontinence??, **leaking urine for 50 days** which started immediately following obstructed last labor for 2 days, in hospital SB male, married 3 yr ago pre(men arche 5 mth later), not living with husband, no menstruation, drop foot R (grade 4); gv: no leakage, no atonic bladder 150.0 cm
healing phase of atonic bladder??????????????

24/2-92 insp_gv/ no leakage, no atonic bladder

FOLEY Ch 18

11/03-92 not leaking at all



KANO

cath 45

sukm (kano city)

female

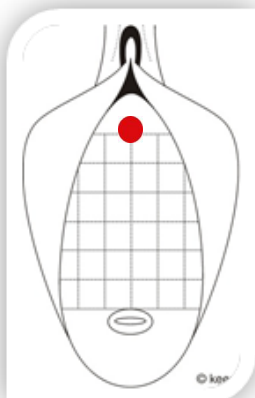
28 yr

02/03-92

diagnosis: PVII (2 alive), overflow incontinence due to an atonic bladder, **leaking urine for 48 days** which started immediately following obstructed last labor for 1 day, in hospital SB female, married 15 yr ago post(menarche 2 mth earlier), not living with husband no menstruation, no h/o drop foot; bladder overdistended (dilator cannot reach bladder wall), > 2000 ml urine
148.5 cm

02/03-92 FOLEY Ch 18

22.03 + 06.04.92 not leaking at all cath removed bladder drill
06/07-92 not leaking at all, no incontinence, normal miction
insp/ healed, no stress incontinence



utgg (kano city)

female 15 yr

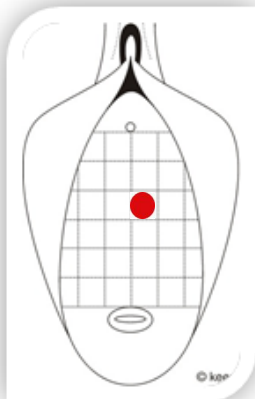
16/03-92

diagnosis: PI, stress incontinence??, **leaking urine on and off for 50 days** which started immediately following craniotomy b.c.o. obstructed labor for 1 day, in hospital SB female, married 2 yr ago pre(menarche 3 mth later), not living with husband, no menstruation, no h/o drop foot; traumatized avw **IIAa** over bladder neck; gv: no leakage/no spilling
EUO/AVWT 4 cm 148.0 cm

16/03-92 FOLEY Ch 18

06.04.92 not leaking at all

17/06-92 not leaking at all, no incontinence, normal miction insp/ healed, no stress incontinence



mam (kano city)

female 31 yr

16/03-92

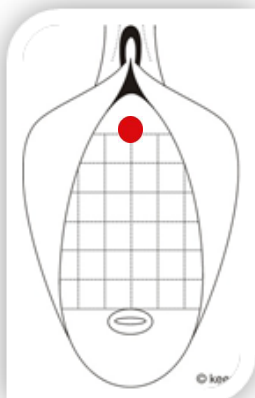
diagnosis: PI, urine stress incontinence with slight UV-stricture, **leaking urine for 43 days** which started 1 day following obstructed labor for 5 days, in hospital SB female, married 19 yr ago pre(menarche 1 yr later), not living with husband, no menstruation no h/o drop foot; 3x2 cm traumatized avw midline bladder base

EUO/AVWT 6 cm, AVWT/C 0 cm

158.0 cm

16/03-92 easy dilatation and FOLEY Ch 18

06/04-92 not leaking at all



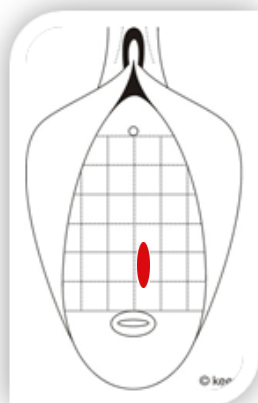
bmb (kano city) female 15 yr 17/03-92

diagnosis: PI, multiple small fistulas L bladder base in 2 cm long scar of yankan gishiri by ungozoma b.c.o. obstructed labor for 3 days, **leaking urine immediately for 28 days**, then in hospital a live male, married 2 yr ago post(menarche 3 mth earlier), not living with husband, no menstruation, no h/o drop foot
EUO/S 6 cm, S/C 1 cm 150.0 cm

17/03-92 primary suturing
freshening, 3x everting supramid and FOLEY Ch 20 anesthetic

06.04.92 not leaking at all

09/09-92 not leaking at all, no incontinence, normal miction
insp/ healed, no stress incontinence



2 cm

uuz (kano city) female 15 yr 17/03-92

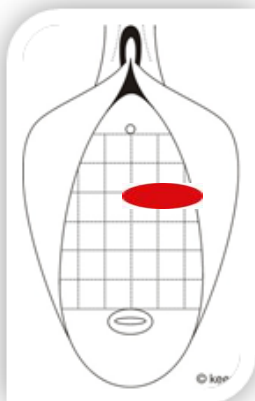
diagnosis: PII (0 alive), ± 3x1 cm urethrovesicovaginal fistula midline/L bladder neck
IIAa, leaking urine for 28 days which started 12 days following obstructed last labor for 2 days, in hospital SB male married 4 yr ago pre(menarche 6 mth later), not living with her husband, no menstruation, no h/o drop foot
EUO/F 3 cm, F/C 6 cm 147.5 cm

17/03-92 primary suturing
3x everting supramid and FOLEY Ch 20 anesthetic

06.04.92 not leaking at all

09.06.92 not leaking at all, no incontinence, normal miction
insp/ healed, good elevation, no stress incontinence

06.09.92 not leaking at all, no incontinence, normal miction healed, no stress



3x1 cm

mis (kano city)

female

15 yr

23/03-92

diagnosis: PI, vesicovaginal fistula R bladder base I (5 mm 0?, may be bigger) , **leaking urine for 2 mth** which started immediately following obstructed labor for 3 days (also yankan gishiri by unguzoma, but the fistula looks more like necrotic), in hospital SB female, married 3 yr ago pre(menarche 1 yr later), not living with husband, normal menstruation, drop foot R (grade 2) and L (grade 3), vagina stenosis/shortening
 EUO/F 5 cm, F/C 0 cm 153.0 cm

23/3-92 FOLEY Ch 18; suturing is not possible

residual 0.5 cm fistula

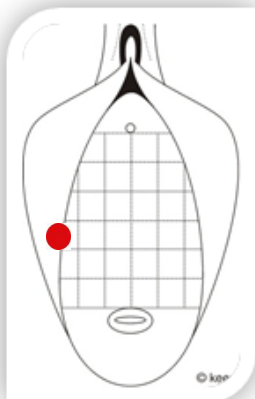
25/01-93 operation: VVF-repair

VVF 496

05.04.93 not leaking at all, no incontinence, normal miction
 insp/ healed, good elevation, no stress incontinence

06.06 + 12.07.93 idem

22.08.93 not leaking at all, no incontinence, normal miction healed, no stress



0.5 cm

KANO

cath 51

krr (kano)

female

16 yr

06/04-92

diagnosis: PI \pm 2.5 cm 0 urethrovesicovaginal fistula **IIAa** slightly to L, leaking urine for 2 mth which started 40 days following obstructed labor for 2 daus, in hospital SB male, married 3 yr ago pre(men arche 3 mth later), not living with husband, no menstruation, no h/o drop foot
EUO/F 3 cm, F/C 6 cm 156.5 cm

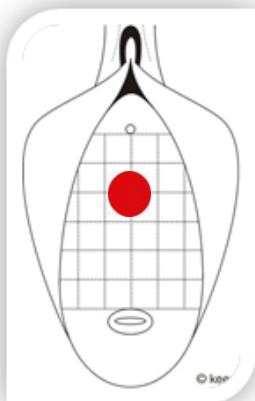
06/04-92

primary suturing

4x everting supramid and FOLEY Ch 16

anesthetic

09.06.92 not leaking at all cath removed bladder drill
14/07-92 not leaking, incontinence $\pm\pm$, normal miction
insp/ healed, no stress incontinence



2.5 cm

KANO

cath 52

hmk (jigawa)

female

41 yr

06/04-92

diagnosis: PXI (6 alive), \pm 5 mm 0 vesicovaginal fistula midline bladder neck **IIAa**,
leaking urine for 3 mth which started 3 days following obstructed last labor
for 3 days, at home SB male, married 30 yr ago pre(menarche 2 yr later),
still living with husband, no menstruation, no h/o drop foot
EUO/F 5 cm, F/C 5 cm 144.0 cm

06/04-92

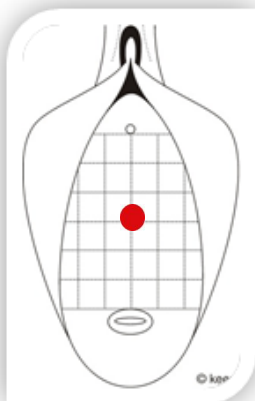
primary suturing

freshening, 4x everting supramid and FOLEY Ch 18

anesthetic

17/06-92

not leaking at all, no incontinence, normal miction
insp/ healed, no stress incontinence



0.5 cm

KANO

cath 53

idtk (kano)

female

26 yr

14/04-92

diagnosis: PIX (3 alive), ± 2 cm 0 vesicovaginal fistula **IIAa** at L bladder neck and slight bladder base prolapse, leaking urine for 2 mth which started 30 days following obstructed labor for 1 day, in hospital SB female, married 15 yr ago pre(menarche 2 yr later) still living with husband, no menstruation, drop foot L (grade 4-5)
EUO/F 4 cm, F/C 4 cm

145.5 cm

14/04-92 primary suturing

freshening, 3x everting supramid and FOLEY Ch 20

anesthetic

residual multiple fistulas

20/07-92 operation: VVF-repair

vvf 376

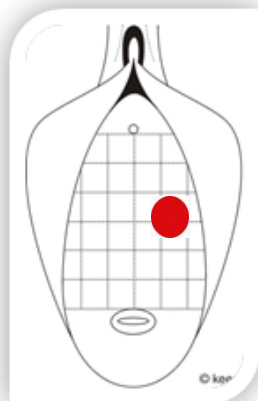
03.08.92 not leaking at all cath removed bladder drill

11.08.92 not leaking at all, no incontinence, normal miction
insp/ healed, good elevation, no stress incontinence

25.08.92 idem

23.09.92 not leaking at all, no incontinence, normal miction healed, no stress

19/09-93 **amenorrhea for 5 mth** not leaking at all **instructions**



2 cm

alg (kano)

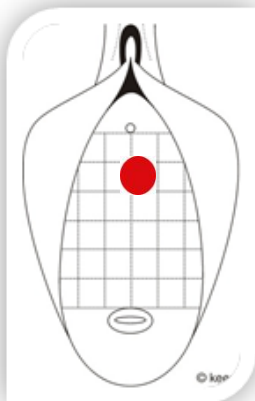
female

21 yr

14/04-92

diagnosis: PI, \pm 1.5 cm 0 urethrovesicovaginal fistula L bladder neck **IIAb** with small circumferential defect/urethra block, **leaking urine for 41 days** which started immediately following craniotomy b.c.o. obstructed labor for 2 days, SB male, married 9 yr ago pre(menarche 1 yr later), not living with husband, no menstruation, drop foot R (grade 2) and L (grade 3)
EUO/F 2 cm, F/C 8 cm 146.0 cm

14/04-92 primary suturing anesthetic
deblocking of urethra, 3x everting supramid and FOLEY Ch 20



1.5 cm

KANO

cath 55
RVF

aamh (kano) female 15 yr 09/06-92

diagnosis: PI, ± 1.5 cm 0 vesicovaginal fistula **IIAa** slightly L bladder neck, **leaking urine for 66 days** which started immediately following obstructed labor for 3 days, in hospital SB male, married 2 yr ago pre(menarche 2 mth later), not living with husband, no menstruation, drop foot R (grade 3) and L (grade 1); also rectovaginal fistula with sphincter ani rupture
EUO/F 5 cm, F/C 2 cm 150.0 cm

09/06-92 primary suturing
freshening, 4x everting supramid and FOLEY Ch 20 anesthetic

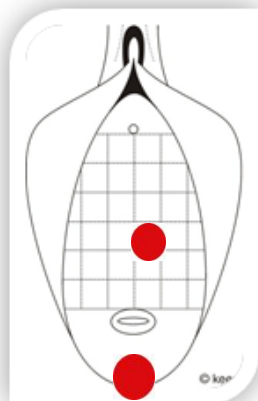
residual 1.5 cm fistula

03/08-92 operation: VVF-repair vvf 391

17.08.92 leaking healed cath removed bladder drill

23/09-92 leaking & normal miction
insp/ completely healed, urine in vaginae

05/10-92 gv for 5 min: no leakage, urine in vaginae ??ureter fistula??



fimb (kano)

female

15 yr

09/06-92

diagnosis: PI, \pm 1 cm 0 urethrovesicovaginal fistula midline and fixed to symphysis with a circumferential defect/urethra block **IIAb, leaking urine for 1 mth** which started immediately following obstructed labor for 2 days, in hospital an SB male, married 3 yr ago pre(menarche 1 yr later), not living with husband, no menstruation drop foot R (grade 2) and L (grade 0); granulations +
 EUO/F 2.5 cm, F/C 8 cm 144.0 cm

09/06-92 primary suturing

deblocking, 3x everting supramid and FOLEY Ch 18

anesthetic

residual 1 cm fistula

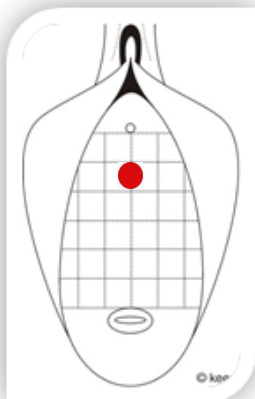
03/08-92 operation: "circumferential" UVVF-repair

vvf 392

17.08.92 not leaking at all cath removed bladder drill

01.09.92 not leaking, incontinence +, normal miction healed, stress +

29/09-92 not leaking, incontinence \pm , normal miction
 insp/ healed, good elevation, no stress incontinence



1 cm

zbg (kano)

female

14 yr

09/06-92

diagnosis: PI, \pm 6 mm 0 urethrovesicovaginal fistula **IIAa** at midline, **leaking urine for 54 days** which started 2 days following obstructed labor for 2 days, in hospital SB male, married 1 yr ago pre(menarche 1 mth later, menstruated only 1x), not living with husband, no menstruation, drop foot R (grade 2-3), no RVF
 EUO/F 2 cm, F/C 10 cm 145.0 cm

09/06-92 primary suturing

2x everting supramid and FOLEY Ch 18

anesthetic

residual 1 cm fistula

03/08-92 operation: UVVF-repair

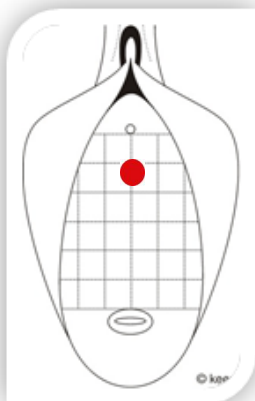
vvf 393

17.08.92 not leaking at all cath removed bladder drill

25.08.92 not leaking at all, no incontinence, normal miction
 insp/ healed, good elevation, no stress incontinence

05.10.92 idem

27.12.92 not leaking at all, no incontinence, normal miction healed, no stress



0.6 cm

ayk (jigawa)

female

15 yr

09/06-92

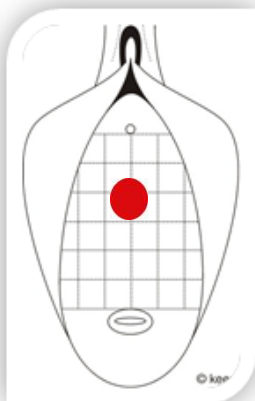
diagnosis: PI, \pm 2 cm 0 urethrovesicovaginal fistula **IIAa** midline bladder neck, **leaking urine for 2 mth** which started 2 days following obstructed labor for 2 days, in hospital an SB male, married 2 yr ago pre(menarche 4 mth later), not living with husband, no menstruation, drop foot R (grade 3) and L (grade 4)
 EUO/F 3 cm, F/C 5 cm 147.5 cm

09/06-92 primary suturing
 freshening, 4x everting supramid and FOLEY Ch 20 anesthetic

residual 1 cm fistula

03/08-92 operation: UVVF-repair **vvf 394**

17.08.92 not leaking at all cath removed bladder drill
 25.08.92 not leaking at all, no incontinence, normal miction
 insp/ healed, good elevation, no stress incontinence
 23.09.92 not leaking at all, no incontinence,normal miction healed, no stress



2 cm

rhdk (kano city)

female

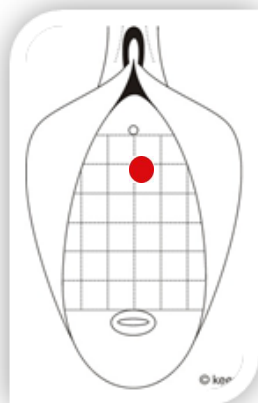
22 yr

09/06-92

diagnosis: PIII (2 alive), \pm 1 cm 0 urethrovesicovaginal fistula **IIAa** slightly at L bladder neck, **leaking urine for 2 mth** which started 7 days following obstructed labor for 1 day, in hospital SB male, married 10 yr ago pre(menarche 1 yr later), still living with husband, normal menstruation, drop foot R (grade 3), no RVF
 EUO/F 2 cm, F/C 7 cm 153.0 cm

09/06-92 primary suturing
 freshening, 3x everting supramid and FOLEY Ch 20 anesthetic

01.07.92 not leaking at all cath removed bladder drill
 22.07.92 not leaking at all, no incontinence, normal miction
 insp/ healed, good elevation, no stress incontinence
 23.08.92 not leaking at all, no incontinence,normal miction healed, no stress



1 cm

KANO

cath 60

sjw (kano)

female

12 yr

09/06-92

diagnosis: P0, ± 1.5x0.5 cm urethrovesicovaginal fistula **IIAa** midline, leaking urine for 3 mth which started immediately following yankan gishiri by wanzami b.c.o. "ba hanya", married 13 mth ago pre-(no menarche yet, but breasts well developed), not living with husband, no RVF, vagina o.k.
EUO/F 3 cm, F/C 4 cm 149.0 cm

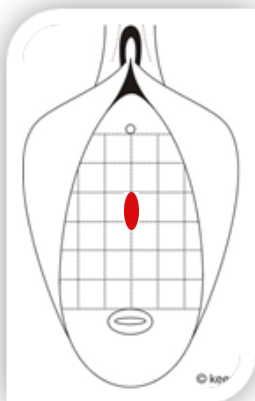
09/06-92

primary suturing

3x everting supramid and FOLEY Ch 20

anesthetic

22.07.92 cath out 2 days after ps not leaking at all bladder drill
27/07-92 not leaking at all, no incontinence, normal miction
insp/ ??healed?? yes



1.5x0.5 cm

aazk (kano city)

female

39 yr

16/06-92

diagnosis: PV (4 alive), ± 5 cm 0 urethrovesicovaginal fistula **IIAb** with circumferential defect, **leaking urine for 25 days** (at 17 days not yet completely clean) which started 2 days following CS b.c.o. obstructed last labor for 1 day, SB female, married 27 yr ago pre (menarche 1 yr later), still living with husband, drop foot R (garde 4) and L (grade 3), no menstruation, no RVF

EUO/F 2 cm, F/C 3 cm

147.5 cm

16/06-92 primary suturing

7x everting supramid and FOLEY Ch 20

anesthetic

residual 4 cm fistula

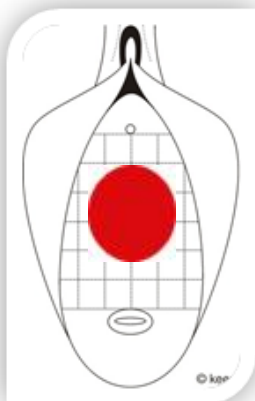
10/08-92 operation: circumferential UVVF-repair

vvf 399

25.08.92 not leaking at all cath removed bladder drill

01.09 + 06.10.92 not leaking, incontinence ±, normal miction

insp/ healed, moderate elevation, stress incontinence ±



5 cm

KANO

cath 62

trj (kano city)

female

26 yr

16/06-92

diagnosis: PIV (2 alive), \pm 2 cm urethrovesicovaginal fistula **IIAb** with circumferential defect, leaking urine for 4 mth which started immediately following obstructed last labor for 1 day, in hospital SB male, married 13 yr ago pre(menarche 3 mth later), still living with husband, no menstruation, drop foot R (grade 4), no RVF
EUO/F 3 cm, F/C 5 cm 152.5 cm

16/06-92 primary suturing

freshening, 5x everting supramid and FOLEY Ch 18

anesthetic

residual 1 cm fistula

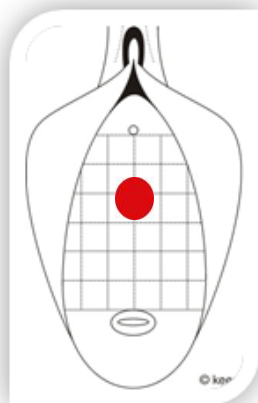
10/08-92 operation: UVVF-repair

vvf 400

25.08.92 not leaking at all cath removed bladder drill

01/09-92 not leaking at all, no incontinence, normal miction

insp/ healed, good elevation, stress incontinence \pm



2 cm

smku (kano city)

female

15 yr

16/06-92

diagnosis: PI, \pm 2 mm 0 vesicovaginal fistula **IIAa** midline bladder neck, **leaking urine for 67 days** which started 3 days following obstructed labor for 2 days, in hospital SB male, married 3 yr ago pre(men arche 1 yr later), not living with husband, no menstruation, no RVF, drop foot L for 1 mth (still grade 4)

EUO/F 4 cm, F/C 6 cm

142.0 cm

16/06-92 primary suturing

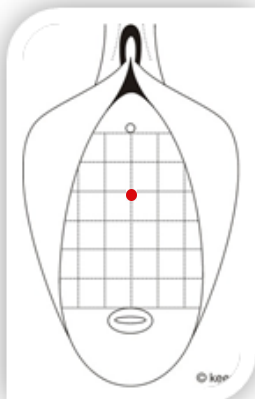
freshening, 2x everting supramid and FOLEY Ch 18

anesthetic

27/07-92 catheter out for 3 wk

not leaking at all, no incontinence, normal miction

insp/ healed, no stress incontinence ?minute VVF at base? no



0.2 cm

aagd (kano city)

female

33 yr

17/06-92

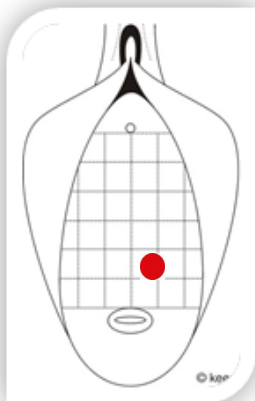
diagnosis: PVII (3 alive), \pm 5 mm 0 retracted vesicovaginal fistula I at L bladder base, leaking urine for 3 mth which started 19 days following CS-laparotomy b.c.o. obstructed last labor (ruptured uterus) for 2 days, SB male, married 20 yr ago pre(menarche 2 mth later), not living with husband, no menstruation, no h/o drop foot, no RVF
 EUO/F 9 cm, F/C 2 cm 146.5 cm

17/06-92 primary suturing

freshening, 4x everting supramid and FOLEY Ch 18

anesthetic

- 22.07 + 27.07.92 not leaking at all cath removed bladder drill
- 03.08.92 not leaking at all, no incontinence, normal miction
 insp/ healed, good elevation, no stress incontinence
- 23.08 + 18.10.92 idem
- 20.12.92 not leaking at all, no incontinence, normal miction healed, no stress
- 19/04-93 **amenorrhea for 4 mth** not leaking at all **instructions**



0.5 cm

zar (kano)

female

28 yr

17/06-92

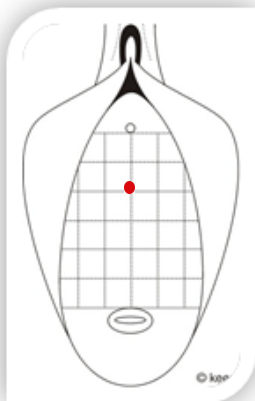
diagnosis: PI, \pm 1 mm 0 vesicovaginal fistula **IIAa** midline bladder neck, **leaking urine for 2.5 mth** which started 9 days following craniotomy b.c.o. obstructed labor for 5 days, SB male, married 15 yr ago pre(menarche same month), not living with husband, drop foot R (grade 1), no menstruation, no RVF
 EUO/F 4 cm, F/C 8 cm 151.5 cm

17/06-92 primary suturing

freshening, 3x everting supramid and FOLEY Ch 20

anesthetic

- 22.07 + 27.07.92 not leaking at all cath removed bladder drill
- 03.08.92 not leaking at all, no incontinence, normal miction
 insp/ healed, good elevation, no stress incontinence
- 23.08 + 18.10.92 idem
- 20.12.92 not leaking at all, no incontinence, normal miction healed, no stress



0.1 cm

bags (kano city)

female

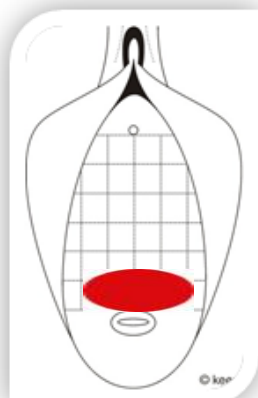
31 yr

28/06-92

diagnosis: PVI (2 alive), overflow incontinence due to atonic bladder with 3x2 cm traumatized avw I over the bladder base, leaking urine for 3 mth which started 7 days following obstructed last labor for 2 days in hospital SB male, married 20 yr ago pre(menarche 2 yr later) still living with husband, no menstruation, no RVF, drop foot R (grade 2-3); EUO/BW 15 cm, > 1500 ml urine
EUO/AVWT 6 cm 166.5 cm

28/6-92 FOLEY Ch 18

11/08-92 not leaking at all, no incontinence, normal miction healed, no stress



hizk (kano city)

female

15 yr

29/06-92

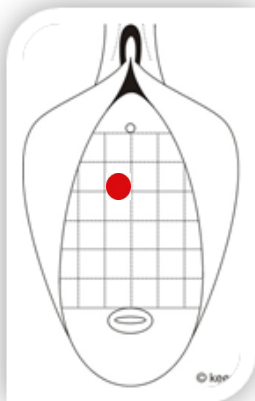
diagnosis: PI, **scarred/retracted** \pm 8 mm 0 urethrovesicovaginal fistula **IIAa** slightly to R bladder neck, **leaking urine for 2 mth** that started 21 days following obstructed labor for 1 day, at home SB female, married 2 yr ago pre(men arche 5 mth), not living with husband, no menstruation, no h/o drop foot, no RVF
EUO/F 3.5 cm, F/C 7 cm 150.0 cm

29/06-92 primary suturing

freshening, 3x everting supramid and FOLEY Ch 18

anesthetic

28.07 + 10.08.92 not leaking at all healed cath removed bladder drill
17/08-92 not leaking at all, no incontinence, normal miction
insp/ ??healed?? yes, no stress incontinence



0.8 cm

KANO

cath 68

documented 29.06 + 14.07 + 01.09 + 27.12.92

rygm (kano city) female 19 yr 29/06-92

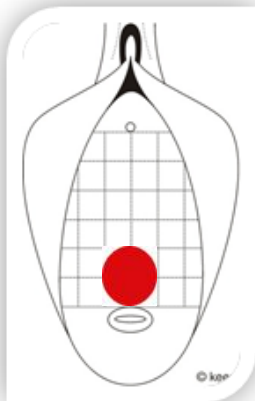
diagnosis: PII (1 alive), 1.5 cm 0 vesicovaginal fistula L bladder base I not clean at tip of 3 cm ^ avw structure, **leaking urine for 27 days** which started 8 days following obstructed last labor for 3 days, in hospital SB female, married 6.5 yr ago pre(menarche 4 mth later), still living with husband no menstruation, drop foot R (grade 2) and L (grade 3), no RVF
EUO/F 7 cm, F/C 0 cm 162.0 cm

29/6-92 FOLEY Ch 16; later for primary suturing

14/07-92 primary suturing

now clean ± 1.5 cm fistula, EUO/F 7 cm, F/C 3 cm 162.0 cm
pat is not drinking enough, bladder flushed out, freshening, 4x everting supramid and FOLEY Ch 18 anesthetic

25.08.92 not leaking at all cath removed bladder drill
01.09.92 not leaking at all, no incontinence, normal miction
insp/ healed, poor elevation, no stress incontinence
06.10.92 idem
27.12.92 not leaking at all, no incontinence, normal miction healed, no stress



3 cm

hgy (kano city) female 19 yr 29/06-92

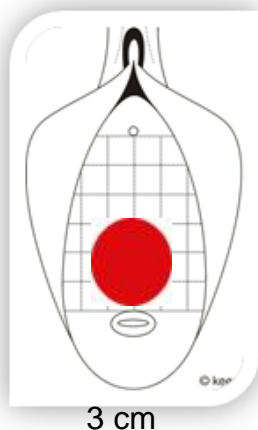
diagnosis: PII (1 alive), **extensive** ± 3 cm 0 urethrovesicovaginal fistula **IIAb** with circumferential defect, scarring ++ and fixed to symphysis, leaking urine for 3 mth which started 40 days following obstructed last labor for 2 days, in hospital SB male, married 7 yr ago pre(menarche 1 yr later), still living with husband, no menstruation, drop foot R (grade 0) and L (grade 1), no RVF
EUO/F 3 cm, F/C 0 cm 155.5 cm

26/06-92 primary suturing
freshening, 5x everting supramid and FOLEY Ch 18 anesthetic

25/08-92 not leaking, incontinence ±, normal miction
insp/ healed, good elevation, no stress incontinence

second obstetric fistula completely ok until PIV (1 alive) sb male in hospital
04/07-00 operation: circumferential UVVF-repair vvf 2066
21.07.00 not leaking at all cath removed bladder drill
28.07.00 not leaking at all, no incontinence, normal miction
insp/ healed, good elevation, no stress incontinence
19.10.100 idem
21.01.01 not leaking at all, no incontinence, normal miction healed, no stress

third obstetric fistula completely ok until PV (2 alive) live female at home
15/01-03 operation: L ureter/circum UVVF-repair vvf 2813
09.02.03 not leaking at all cath removed bladder drill
06.03.03 not leaking at all, no incontinence, normal miction
insp/ healed, good elevation, no stress incontinence
04.05.03 idem
29.06.03 not leaking at all, no incontinence, normal miction healed, no stress



rmg (kano)

female 14 yr

29/06-92

diagnosis: PI, ± 1 cm 0 urethrovesicovaginal fistula **IIAa** at midline, **leaking urine for 2 mth** which started immediately following obstructed labor for 3 days, in hospital SB male, married 3 yr ago pre(men arche 2 yr later), not living with husband, no menstruation, no RVF, drop foot R (grade 3) and L (grade 3)

EUO/F 1.5 cm, F/C 8 cm

150.5 cm

29/06-92 primary suturing

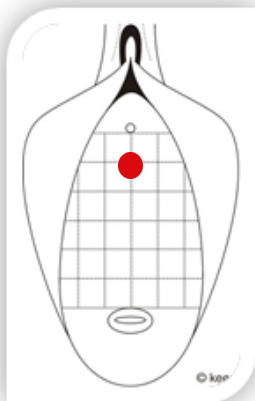
freshening, 4x everting supramid and FOLEY Ch 18

anesthetic

28.07 + 10.08.92 cath out today not leaking at all bladder drill

17.08.92 not leaking at all, no incontinence, normal miction
insp/ healed, good elevation, no stress incontinence

06.10.92 not leaking at all, no incontinence, normal miction healed, no stress



1 cm

tar (kano) female 16 yr 29/06-92

diagnosis: PII (0 alive), extensive \pm 5 cm 0 urethrovesicovaginal fistula **IIAa** bladder neck/base, **leaking urine for 24 days** which started immediately following obstructed labor for 2 days, in hospital SB male, married 3 yr ago post(menarche 3 mth earlier), not living with husband, no menstruation, drop foot R (grade 3), no RVF poor condition
EUO/F 3 cm, F/C 0 cm 146.5 cm

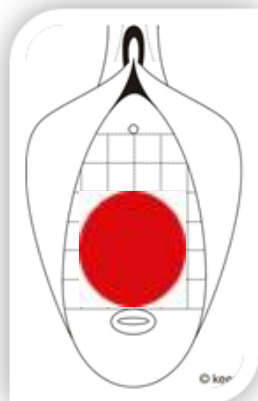29/06-92 primary suturing anesthetic
5x everting supramid, FOLEY Ch 18; not too much can be expected

23/08-92 breakdown poor general condition
residual 2.5 cm fistula

17/01-93 operation: bilateral ureters/UVVF-repair **vvf 487**

05.04.03 not leaking at all, no incontinence, normal miction
insp/ healed, good elevation, no stress incontinence

06.06.03 not leaking at all, no incontinence, normal miction healed, no stress



5 cm

sadnr (kano city)

female

16 yr

29/06-92

diagnosis: PII (0 alive), \pm 5 mm 0 avw defect **IIAa** with seeping thru and incontinence, **leaking urine for 20 days which started 10 days** following obstructed last labor for 2 days, in hospital an SB female, married 4 yr ago pre(menarche 1 yr later), still living with husband, no menstruation, no h/o drop foot, no RVF post eclamptic slowed down
EUO/AVWD 1 cm, AVWD/C 7 cm 159.5 cm

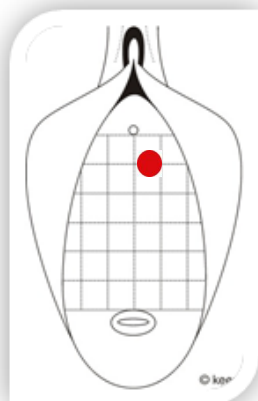
29/06-92 primary suturing

1x everting supramid and FOLEY Ch 18

anesthetic

28.07.92 cath out x 3/7 not leaking at all bladder drill

15/09-92 not leaking at all, no incontinence, normal miction
insp/ healed, good elevation, no stress incontinence



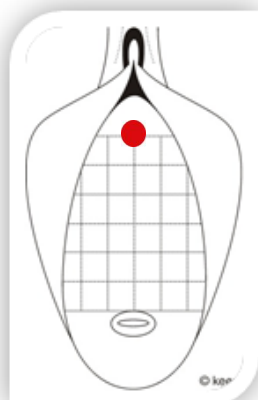
0.5 cm

hub (kano city) female 16 yr 29/06-92

diagnosis: PI, overflow incontinence??? due to atonic bladder???, **leaking urine for 20 days** which started immediately following obstructed labor for 1 day, in hospital a live male, married 3 yr ago post(menarche 1 mth earlier), not living with husband, no menstruation, drop foot R (grade 3), no RVF
EUO/BW 12 cm, bladder full (>500 ml urine) 153.0 cm

29/6-92 FOLEY Ch 18

10/08-92 overflow incontinence FOLEY Ch 18



msbr (kano city) female 15 yr 29/06-92

diagnosis: PI, extensive avw defect with 2 cm 0 urethrovesicovaginal fistula midline **IIAa, leaking urine for 36 days** which started 7 days following obstructed labor for 4 days, in hospital SB male, married 1.5 yr ago post(menarche 1 mth earlier), not living with husband, no menstruation, drop foot R (grade 3), no RVF
EUO/F 2.5 cm, F/C 5 cm 149.5 cm

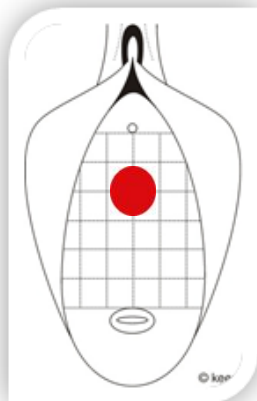
29/06-92 primary suturing
freshening, 7x everting supramid and FOLEY Ch 18 anesthetic

25/01-93 gv: minute fistula
26/01-93 operation: UVVF-repair vvf 501

05.04.93 not leaking at all, no incontinence, normal miction
insp/ healed, good elevation, no stress incontinence

24.05.93 idem

22.08.93 not leaking at all, no incontinence, normal miction healed, no stress



2 cm

lgd (kano city)

female

14 yr

29/06-92

diagnosis: PI, ± 3 cm 0 vesicovaginal fistula L bladder base/neck **IIAa, leaking urine for 20 days which started 2 days** following obstructed labor for 2 days, in hospital SB male, married 1 yr 4 mth ago pre (menarche 4 mth later), not living with husband, no RVF, no h/o drop foot, no menstruation
 EUO/F 5 cm, F/C 2 cm 152.5 cm

29/06-92 primary suturing

4x everting supramid and FOLEY Ch 18

anesthetic

residual 2 cm fistula

25/08-92 operation:catheterization L ureter/VVF-repair

vvf 416

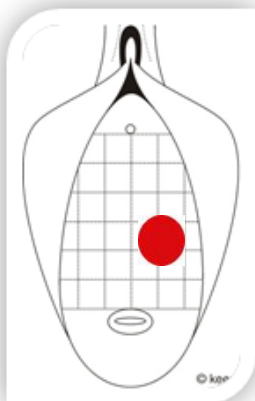
08.09.92 not leaking at all cath removed bladder drill

23.09.92 not leaking at all, no incontinence, normal miction

insp/ healed, good elevation, no stress incontinence

06.10.92 not leaking at all, no incontinence, normal miction

healed, no stress



3 cm

lab (jigawa)

female

15 yr

29/06-92

diagnosis: PI, **extensive** ± 2.5x1 cm vesicovaginal fistula **IIAa** midline/L, **leaking urine for 30 days** which started 7 days following obstructed labor for 2 days, at home SB male, married 2 yr ago pre(menarche 3 mth later), not living with husband, no menstruation, no RVF, drop foot R (grade 4), severe vagina shortening/stenosis, cervix at vagina vault
 EUO/F 4 cm, F/C 0 cm 146.5 cm

29/06-92 primary suturing

freshening, 5x everting supramid and FOLEY Ch 18

anesthetic

residual 1.5x1 cm fistula

07/09-92 operation: VVF-repair

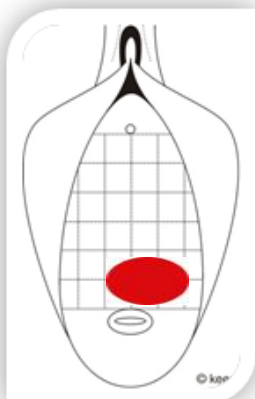
vvf 427

21.09.92 not leaking at all cath removed bladder drill

29.09.92 not leaking at all, no incontinence, normal miction
 insp/ healed, good elevation, no stress incontinence

16.10 + 17.01.93 idem

24.05.93 not leaking at all, no incontinence, normal miction healed, no stress



2.5x1 cm

jsgs (kano city)

female

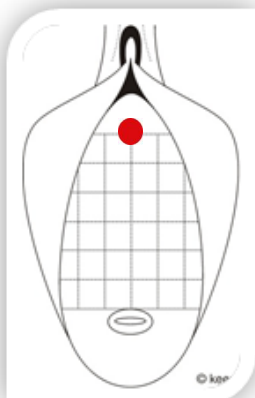
15 yr

29/06-92

diagnosis: PI, stress incontinence grade II, only **leaking urine when standing/walking for 25 days** which started immediately following obstructed labor for 1 day, at home live female, married 3 yr ago pre(menarche 1 yr later), not living with husband, no menstruation, no h/o drop foot, no RVF, not leaking at night 148.0 cm

29/6-92 FOLEY Ch 18

04.08.92 not leaking at all cath removed bladder drill
11/08-92 not leaking at all, no incontinence, normal miction
insp/ healed, no stress incontinence



KANO
second obstetric leakage

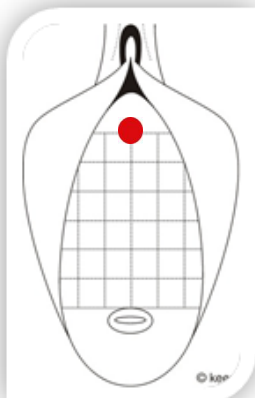
cath 78

bis (kano city) female 22 yr 28/06-92

diagnosis: PVI (0 alive), overflow incontinence due to atonic bladder???, leaking urine for 3 mth which started immediately following obstructed last labor for 1 day, in hospital SB male, married 10 yr ago pre(menarche 1 yr later), not living with husband, normal menstruation, no h/o drop foot, no RVF; N.B. VVF-repair after first delivery 142.5 cm

28/6-92 FOLEY Ch 18; eventually check by gv

03.08.92 not leaking at all cath removed bladder drill
17/08-92 not leaking at all, no incontinence, normal miction
insp/ healed, no stress incontinence



nsd (kano city)

female

16 yr

06/07-92

diagnosis: PI, \pm 2 mm 0 vesicovaginal fistula **IIAa** midline bladder neck, **leaking urine for 36 days** which started 16 days following obstructed labor for 1 day, at home a live male which died same day, married 3 yr ago post(menarche 3 mth earlier), not living with husband, no menstruation, no h/o drop foot, no RVF
 EUO/F 5 cm, F/C 5 cm 153.5 cm

06/07-92 primary suturing
 freshening, 3x everting supramid and FOLEY Ch 18 anesthetic

residual 0.2 cm fistula

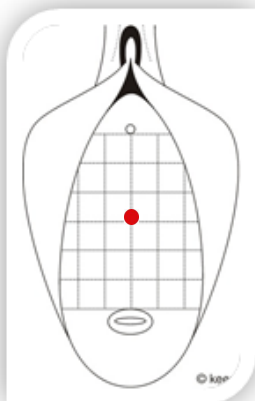
31/08-92 operation: VVF-repair **vvf 418**

14.09.92 not leaking at all cath removed bladder drill

21.09.92 not leaking at all, no incontinence, normal miction
 insp/ healed, good elevation, no stress incontinence

06.10.92 idem

05.04.93 not leaking at all, no incontinence, normal miction healed, no stress



0.2 cm

KANO

cath 80

sab (kano)

female

14 yr

06/07-90

diagnosis: PI, \pm 2 mm 0 retracted vesicovaginal fistula I at midline bladder base, **leaking urine for 2 mth which started 15 days** following obstructed labor for 2 days, in hospital SB male, married 1 yr ago pre(menarche 2 mth later), not living with husband, no RVF, drop foot R for 1 mth (still grade 4) and L (grade 3)
EUO/F 7 cm, F/C 4 cm

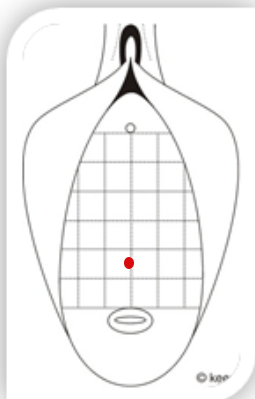
147.0 cm

06/07-92 primary suturing

freshening, 3x everting supramid and FOLEY Ch 18

anesthetic

17.08.92 not leaking at all cath removed bladder drill
25/08-92 not leaking at all, no incontinence, normal miction
insp/ healed, good elevation, no stress incontinence



0.2 cm

KANO

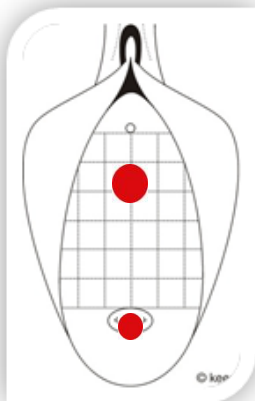
cath 81
rvf

mam (kano city) female 15 yr 06/07-92

diagnosis: PI, \pm 2.5 cm 0 urethrovesicovaginal fistula and circumferential defect **IIAb**, **leaking urine for 18 days** which started 2 days following obstructed labor for 2 days, in hospital SB male, married 2 yr ago pre(menarche 2 mth later), not living with husband, no menstruation, drop foot R (grade 2) and L (grade 1), proximal RVF??
EUO/F 2 cm, F/C 6 cm, AB/AU 0,5 cm 148.0 cm

06/07-92 primary suturing
5x everting supramid and FOLEY Ch 18 anesthetic

25/08-92 not leaking at all, no incontinence, normal miction insp/ healed, no stress incontinence



2.5 cm

KANO
second obstetric leakage

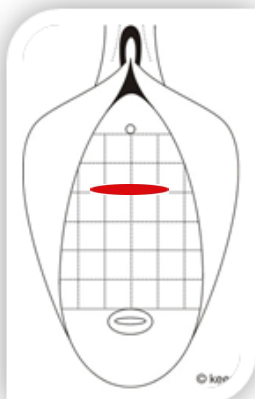
cath 82

surg (kano city) female 32 yr 13/07-92

diagnosis: PVI (2 alive), overflow incontinence due to UV-stricture, **leaking urine for 2 mth** which started immediately following obstructed last labor for 1 day, at home SB female, married 20 yr ago pre(menarche 1 yr later), still living with husband, normal menstruation 1x, no h/o drop foot, no RVF; N.B. scar over bladder neck of VVF-repair after 5th delivery 150.0 cm

13/7-92 dilatation thru H8 and FOLEY Ch 18

25.08.92 cath out x 3/7 not leaking at all bladder drill
08.09.92 not leaking at all, no incontinence, normal miction
insp/ healed, good elevation, no stress incontinence
06/10-92 not leaking at all, no incontinence, normal miction
insp/ healed, no stress incontinence **no uv-stricture**



hhg (kano)

female

18 yr

13/07-92

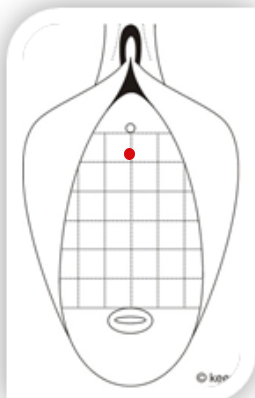
diagnosis: PI, totally stenosed/shortened urethra with minute urethrovaginal fistula **IIBa**, leaking urine for 4 mth which started immediately following obstructed labor for 2 days, at home SB female, married 5 yr ago pre (menarche 5 mth later), not living with husband, no menstruation, drop foot R for 1 mth (now grade 5), no RVF, moderate vagina stenosis with cx at vault

EUO/F 1 cm, F/C 6 cm

154.0 cm

13/7-92 dilatation thru H10 and FOLEY Ch 18

- 25.08.92 not leaking at all cath removed bladder drill
- 01.09.92 not leaking at all, no incontinence, normal miction insp/ healed, no stress incontinence
- 06.10.92 not leaking at all, no incontinence, normal miction dilatation uv-stric
- 02.12.92 idem repeat dilatation
- 18.01.93 not leaking at all, no incontinence, normal miction healed, no stress



minute fistula

KANO
development ^ avw structure 13.05.13

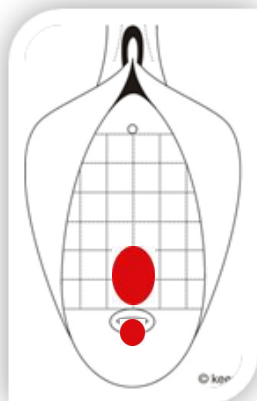
cath 84
rvf

ruk (kano) female 33 yr 13/07-92

diagnosis: PI, \pm 3x2 cm avw defect I with seeping thru at the top, **leaking urine for 40 days** which started 1 day following craniotomy b.c. o. obstructed labor for 2 days, SB male, married 20 yr ago pre(menarche 3 mth later), still living with husband, no menstruation, drop foot R (grade 3) and L (grade 3), proximal RVF??
EUO/F 6 cm, F/C 0 cm 151.0 cm

13/07-92 primary suturing anesthetic
freshening, 2x longitudinal evertng supramid and FOLEY Ch 18

25.08.92 not leaking at all cath removed bladder drill
01.09.92 not leaking at all, no incontinence, normal miction
insp/ healed, good elevation, no stress incontinence
23.09.92 not leaking at all, no incontinence, normal miction healed, no stress



3x2 cm

hsmb (kano)

female

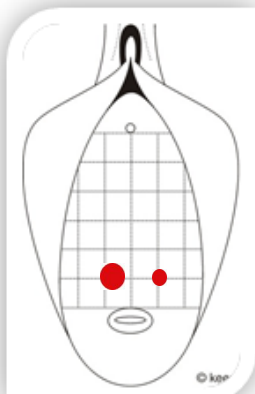
16 yr

13/07-92

diagnosis: PI, one \pm 1 cm 0 vesicovaginal fistula R bladder base and also one \pm 5 mm 0 vesicovaginal fistula L bladder base, **leaking of urine for 24 days** which started immediately following obstructed labor for 2 days, in hospital SB male, married 3 yr ago pre (menarche 4 mth later), not living with husband, no RVF, no menstruation, drop foot R (grade 2)
 EUO/F 5 cm, F/C 1 cm **within ^ avw structure** 154.5 cm

13/07-92 primary suturing anesthetic
 freshening 2x, everting supramid 2x resp 1x and FOLEY Ch 20

25.08.92 not leaking at all cath removed bladder drill
 01.09.92 not leaking at all, no incontinence, normal miction
 insp/ healed, good elevation, no stress incontinence
 06.10 + 01.12.92 idem
 27.12.92 not leaking at all, no incontinence, normal miction healed, no stress



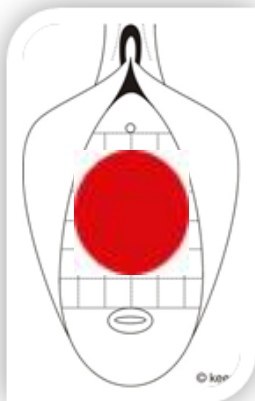
multiple fistulas

hsdr (kano) female 14 yr 13/07-92

diagnosis: PI, extensive \pm 6 cm 0 urethrovesicovaginal fistula **IIAb** with circumferential defect, **leaking urine for 29 days** which started immediately following obstructed labor for 5 days, in hospital SB female, married 1 yr ago pre(menarche 3 mth later), not living with husband, no menstruation, drop foot R (grade 4) and L (grade 2), no RVF; at 7/7-92 still some necrotic tissue
EUO/F 1.5 cm, F/C 2 cm, AB/AU 2 cm 155.0 cm

13/07-92 primary suturing
freshening, 7x everting supramid and FOLEY Ch 20 anesthetic

27/07-92 balloon in fistula



6 cm

hsgg (jigawa)

female

16 yr

14/07-92

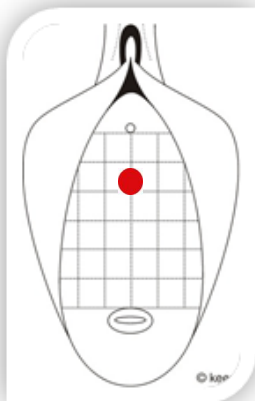
diagnosis: PI, ± 5 mm 0 urethrovesicovaginal fistula **IIAa** midline with granulations at R bladder neck, **leaking urine for 2 mth which** started 8 days following obstructed labor for 3 days, at home live male, married 3 yr ago pre(menarche 2 mth later), not living with husband, no menstruation, drop foot R (grade 4), no RVF
 EUO/F 2 cm, F/C 8 cm 153.0 cm

14/07-92 primary suturing

freshening, 3x everting supramid and FOLEY Ch 18

anesthetic

- 25.08.92 not leaking, incontinence cath removed bladder drill
- 01.09.92 not leaking at all, no incontinence, normal miction
 insp/ healed, good elevation, no stress incontinence
- 23.09.92 idem
- 27.12.92 not leaking at all, no incontinence, normal miction healed, no stress



0.5 cm

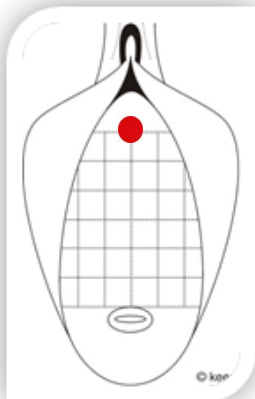
KANO
traumatic sacral plexus trauma

cath 88
rvf

agtn (kano) female 20 yr 01/07-92

diagnosis: PIII (1 alive), total urine/stool incontinence, **leaking urine for 40 days** which started following road traffic accident, married 8 yr ago pre(menarche 1 yr later), not living with husband 152.0 cm

01/07-92 FOLEY Ch 18

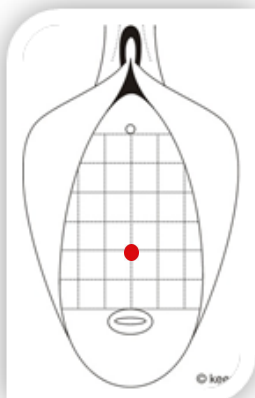


zabk (kano) female 14 yr 20/07-92

diagnosis: PI, overflow? incontinence due to atonic bladder?? (EUO/BW only 10 cm and 0.5 liter of urine), **leaking urine for 20 days** which started 10 days following obstructed labor for 1 day, in hospital live male which died 5 days later, married 2 yr ago pre(men arche 1 yr later), not living with husband, no menstruation, no h/o drop foot, no RVF
minute < 0.1 cm 0 vesicovaginal fistula midline type I
EUO/AVWD 7 cm, AVWD/C 3 cm 152.0 cm

20/7-92 FOLEY Ch 18

- 31.08.92 cath out x 1/7 not leaking at all bladder drill healed, no stress incontinence, normal fluor
- 04.10.92 not leaking at all, no incontinence, normal miction insp/ healed dimple bladder base, no stress incontinence
- 01.12.92 idem
- 18.01.93 not leaking at all, no incontinence, normal miction healed, no stress healed with dimple



minute fistula

KANO

cath 90
rvf

hszr (kano) female 18 yr 20/07-92

diagnosis: PII (1 alive), ± 2.5x1 cm urethrovesicovaginal fistula R bladder neck **IIAa**, also proximal rectovaginal fistula, **leaking urine and passing stools per vaginam for 60 days** which started 7 days following obstructed labor for 7 days, in hospital SB male, married 5 yr ago pre(menarche 5 mth later), still living with husband, drop foot L (grade 3), no menstruation, severe vagina stenosis; when seen 17/6-92 necrotic vagina
EUO/F 3 cm, F/C 3 cm 157.0 cm

20/07-92 primary suturing anesthetic
freshening, difficult 3x everting supramid and FOLEY Ch 18

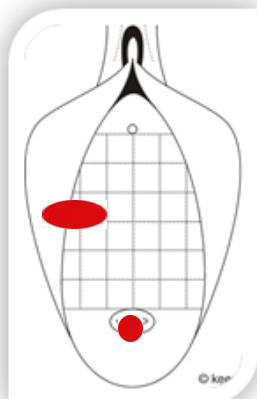
23/09-92 not leaking, incontinence ±, normal miction
gv: small 0.8 cm **fistula** at R

06/10-92 operation: UVVF-repair **VVF 457**

20.10.92 not leaking at all cath removed bladder drill

17.01.93 not leaking at all, no incontinence, normal miction
insp/ healed, good elevation, no stress incontinence

19.04.93 not leaking at all, no incontinence, normal miction healed, no stress



2.5x1 cm

KANO

cath 91

better closure of avw to prevent small residual fistulas

mmyk (kano city)

female

15 yr

20/07-92

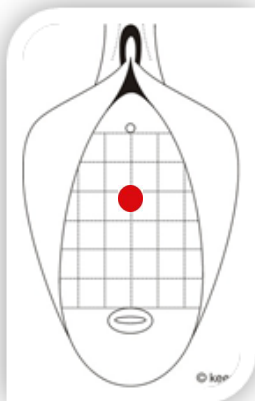
diagnosis: PI, \pm 5 mm avw defect **IIAa** with seeping thru, **leaking urine for 19 days** which started immediately following craniotomy b.c.o. obstructed labor for 1 day, in hospital SB male, married 2 yr ago pre(menarche 3 mth later), not living with husband, no menstruation, drop foot R (grade 4) and L (grade 3), no RVF
 EUO/F 4 cm, F/C 7 cm 151.5 cm

20/07-92 primary suturing

anesthetic

freshening, 3x everting supramid, 2x chromic catgut; FOLEY Ch18

- 31.08.92 not leaking at all cath removed bladder drill
- 08.09.92 not leaking at all, no incontinence, normal miction
 insp/ healed, good elevation, no stress incontinence
- 06.10 + 01.12.92 idem
- 18.01.,93 not leaking at all, no incontinence, normal miction healed, no stress



0.5 cm

bik (kano city)

female

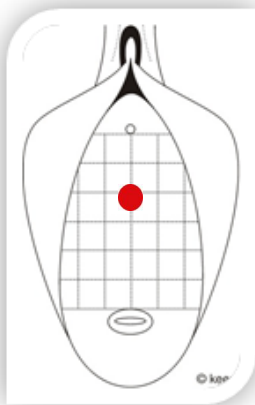
14 yr

20/07-92

diagnosis: PI, \pm 1 cm 0 necrotic vesicovaginal fistula **IIAa** at L bladder neck, **leaking urine for 21 days** which started immediately following obstructed labor for 5 days, in hospital SB male, married 2 yr ago pre(menarche 1 yr later), not living with husband, no RVF, no menstruation, drop foot L (grade 4) EUO/F 3 cm, F/C 6 cm 154.5 cm

20/7-92 FOLEY Ch 18; later for primary suturing

03.08.92 not leaking at all insp/ seems healed, granulations catheter removed
gv: no leakage



1 cm

ausn (kano)

female

14 yr

22/07-92

diagnosis: PI, extensive \pm 6 cm 0 urethrovesicovaginal fistula **IIAb** with circumferential defect, **leaking urine for 22 days** which started 1 day following obstructed labor for 3 days, in hospital SB male, married 2 yr ago pre(menarche 1 yr later), still living with husband, no menstruation, drop foot R (grade 3-4), no RVF
 EUO/F 1.5 cm, F/C 2.5 cm 139.0 cm

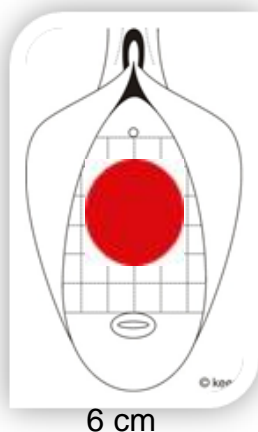
22/07-92 primary suturing anesthetic
 freshening, 5x everting supramid, 4x chromic catgut; FOLEY Ch20 N.B.
 necrotic pvw and lateral vagina walls, perhaps it was too early

31.08.92 not leaking at all cath removed bladder drill
 06.10 + 01.12.92 not leaking at all, no incontinence, normal miction
 insp/ healed, good elevation, no stress incontinence

second obstetric fistula completely ok until PII (0 alive) sb male by cs
21/12-93 operation (MMSH_Sa): UVVF-repair
 completely ok until

26/03-00 **new leakage** for 2 yr PIII (0 alive) in hospital SB female
 insp/ poor elevation, **stress incontinence +++** R=4-5 L=4-5
bladder drill

however, 23/10-02 third/fourth obstetric fistula
23/10-02 operation: closure/urethralization/suspension VVF 2761
 10.11 + 17.11.02 not leaking at all cath removed bladder drill
 22.12 + 16.02.03 not leaking, incontinence \pm , normal miction healed, stress \pm
 23.02.03 not leaking at all, no incontinence, normal miction
 insp/ healed, good elevation, stress incontinence \pm
 25.05.03 not leaking at all, no incontinence, normal miction healed, stress \pm



KANO cath 94
documented 22.07 + 04.08 + 14.09 + 29.09 + 11.01.93 rvf

rmk (kano city) female 14 yr 22/07-92

diagnosis: PI, **necrotic** ± 4 cm 0 urethrovesicovaginal fistula **IIAa**, also proximal rectovaginal fistula, **leaking urine/passing stools pv for 14 days** which started immediately following an obstructed labor for 4 days, in hospital SB male, married 1.5 yr ago pre(menarche 7 mth later), not living with her husband, no menstruation, drop foot R (grade 4) and L (grade 3)
EUO/F 2 cm, F/C 3 cm 144.0 cm

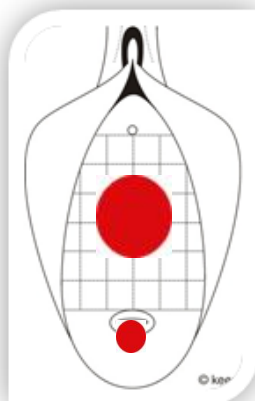
22/7-92 FOLEY Ch 20; later for primary suturing

04/08-92 primary suturing leaking for 27 days
freshening, bladder closure, avw closure by 5x supramid and 4x chromic catgut, FOLEY Ch 18 anesthetic
residual multiple minute fistulas

11/01-93 operation: UVVF-repair rvf healed vvf 482
26.01.93 not leaking at all cath removed bladder drill

12.04.93 not leaking at all, no incontinence, normal miction stools ok
insp/ **both** healed, good elevation, no stress incontinence

15.06.93 not leaking at all, normal miction, stools ok **both** healed, no stress



4 cm

KANO

cath 95

aur (kano city)

female

15 yr

23/07-92

diagnosis: PI, extensive \pm 5 cm 0 urethrovesicovaginal fistula **IIAb** with circumferential defect, leaking urine for 3 mth which started 3 days following obstructed labor for 1 day, in hospital a SB female, married 2 yr ago pre(menarche 3 mth later), not living with her husband, no menstruation, drop foot R (grade 3) and L (grade 3) no RVF
EUO/F 2.5 cm, F/C 1 cm 151.0 cm

23/07-92 primary suturing anesthetic
freshening, 5x everting supramid, 4x chromic catgut; FOLEY Ch18

23/09-92 not leaking, incontinence \pm . normal miction
gv: residual 2 cm **fistula** midline/L

06/10-92 operation: UVVF-repair **VVF 455**

03/05-93 not leaking, incontinence \pm , normal miction
gv: leakage L

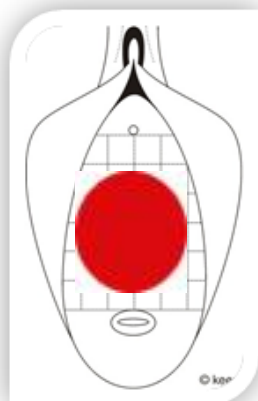
18/10-93 operation: UVVF-repair **VVF 663**

01.11.93 not leaking at all cath removed bladder drill

07.11.93 not leaking at all, no incontinence, normal miction
insp/ healed, good elevation, no stress incontinence

21.11 + 30.01 + 10.04.94 idem

05.06.94 not leaking at all, no incontinence, normal miction healed, no stress



5 cm

zycc (jigawa)

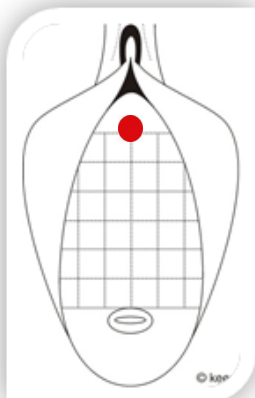
female

15 yr

04/08-92

diagnosis: PI, total stress incontinence, **leaking urine day and night for 7 days** when lying/sitting/standing/walking, cannot pass urine herself which started 7 days following obstructed labor for 3 days, in hospital SB male, married 2 yr ago pre(menarche 1 mth later), not living with husband, no menstruation, no h/o drop foot, no RVF; incontinence demonstrated by lying/coughing, normal bladder capacity (EUO/BW 10 cm) 153.5 cm

04/08-92 FOLEY Ch 18



KANO
documented 24.08 before/after + 21.09.92

cath 97

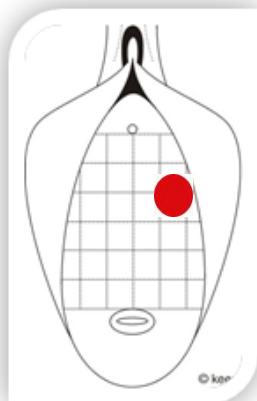
wyg (kano) female 20 yr 04/08-92

diagnosis: PII (0 alive), \pm 2 cm 0 necrotic fistula with seeping thru at L bladder neck
IIAa, leaking urine for 18 days which started 1 day following obstructed
last labor for 1 day, at home a SB male, married 7 yr ago pre(menarche 2
mth later), not living with husband, no menstruation, drop foot R (grade 1-
2), no RVF
EUO/F 3 cm, F/C 5 cm 149.0 cm

04/08-92 FOLEY Ch 18; later for primary suturing

24/08-92 early closure now clean \pm 1 cm 0 UVVF at L bladder neck
leaking urine for 38 days
freshening, minimal dissection, transverse bladder closure with inverting
chromic catgut, transverse avw closure with everting chromic catgut/3x
supramid, FOLEY Ch 18; free urine flow, good bladder capacity
(EUO/BW 10 cm), good elevation, EUO/B 3 cm anesthetic

21.09.92 cath put x 4/7 not leaking at all bladder drill
29.09.92 not leaking at all, no incontinence, normal miction
insp/ healed, good elevation, no stress incontinence
01.12.92 idem
18.01.93 not leaking at all, no incontinence, normal miction healed, no stress



2 cm

KANO

cath 98

zhyr (kano)

female

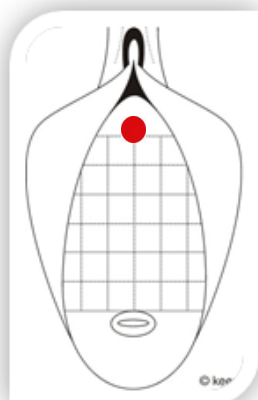
15 yr

14/09-92

diagnosis: PI, overflow incontinence due to atonic bladder, **leaking urine for 26 days** which started 4 days after obstructed labor for 1 day, at home live female, married 4 yr ago pre(menarche 17 mth later), not with husband, no menstruation, no RVF, no h/o drop foot; bladder overdistended (EUO/BW 17 cm), bladder overfilled (> 1.5 liter urine) 160.0 cm

14/9-92 FOLEY Ch 18

12.10.92 not leaking at all cath removed bladder drill
19/10-92 not leaking at all, no incontinence, normal miction EUO/BW 10 cm
insp/ healed, no stress incontinence



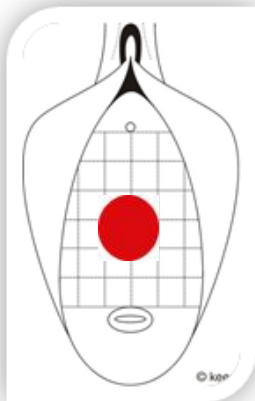
from now onwards a "full" repair in fresh fistulas if vagina anesthetic

sahcc (jigawa) female 15 yr 10/08-92

diagnosis: PI, extensive ± 1.5 cm 0 urethrovesicovaginal fistula **IIAa, leaking urine for 28 days** which started immediately following obstructed labor for 2 days, in hospital SB female, married 2 yr ago pre(menarche 4 mth later), not living with husband, no menstruation, drop foot L (grade 4), no RVF EUO/F 1.5 cm, F/C 1 cm 147.0 cm

10/08-92 early closure
freshening, minimal dissection, transverse bladder/urethra closure with inverting chromic catgut (both urethra/bladder hypertrophic), transverse avw closure with everting chromic catgut and 2x supramid, FOLEY Ch 18; free flow of urine, good bladder capacity (EUO/BW 11 cm), elevation??, EUO/B 2 cm anesthetic

31.08 + 14.09.92 not leaking at all cath removed bladder drill
21.09.92 not leaking at all, no incontinence, normal miction
insp/ healed, moderate elevation, no stress incontinence
06.10 + 01.12.92 idem
03.05.93 not leaking at all, no incontinence, normal miction healed, no stress
slight vagina stenosis



1.5 cm

KANO
catheter x 4 wk; then 3 wk; then 2wk

cath 100

bgni (kano city) female 14 yr 17/08-92

diagnosis: PI, \pm 2 cm 0 vesicovaginal fistula **IIAa** midline bladder neck, **leaking urine for 30 days** which started 16 days following CS b.c.o. obstructed labor for 1 day, live female which died 2 days later married 2 yr ago pre(menarche 6 mth later), still living with husband, no menstruation, no h/o drop foot, no RVF
EUO/F 4 cm, F/C 5 cm 151.5 cm

17/08-92 early closure

freshening, minimal dissection, transverse bladder closure with inverting chromic catgut, transverse avw closure with everting chromic catgut/3x supramid, FOLEY Ch 20; free urine flow, good bladder capacity (EUO/BW 12 cm), good elevation, EUO/B 4 cm anesthetic

01.09 + 14.09 not leaking at all cath removed bladder drill
21/09-92 not leaking at all, no incontinence, normal miction
insp/ healed, good elevation, no stress incontinence

second obstetric fistula completely ok until PII (1 alive) live male vacuum

17.10.94 primary suturing cath 348

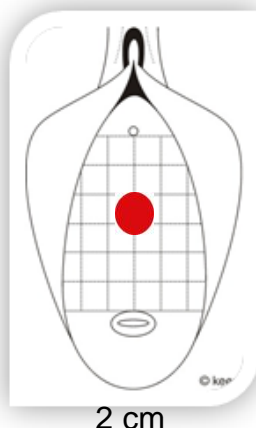
30.10 + 13.11.94 not leaking at all cath removed bladder drill
20.11.94 not leaking at all, no incontinence, normal miction
insp/ healed, good elevation, no stress incontinence
11.12.94 not leaking at all, no incontinence, normal miction healed, no stress

delivered 2x at home and then 1x by cs

third obstetric fistula completely ok until PV (2 alive) sb female by cs

13.11.00 operation: uvvf-repair vvf 2134

04.12 + 11.12.00 not leaking at all cath removed bladder drill
18.12.00 not leaking at all, no incontinence, normal miction
insp/ healed, good elevation, no stress



KANO
suprapubic mass

cath 101

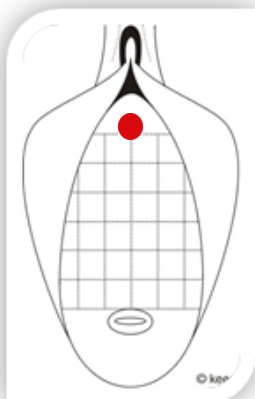
mktwdk (jigawa) female 22 yr 18/08-92

diagnosis: PIV (2 alive), overflow incontinence due to atonic bladder, **leaking urine for 14 days** which started immediately following obstructed last labor for 1 day, in hospital stillborn male infant, married 10 yr ago pre(menarche 2 mth later), not living with husband, no h/o drop foot, no menstruation, bladder overfilled (>1.5 liter), no RVF, EUO/BW 16 cm, feels like abdominal mass 153.0 cm

18/8-92 FOLEY Ch 18

31.08 + 08.09.92 cath removed by pat not leaking at all bladder drill
23/05-93 not leaking at all, no incontinence, normal miction
insp/ healed, good elevation, no stress incontinence

23/08-93 **amenorrhea for 5 mth** not leaking at all **instructions**



KANO

cath 102

documented 24.08 + 08.09 before/after + 06.10 + 18.01.93

hzmb (kano) female 35 yr 24/08-92

diagnosis: PIV (3 alive), ± 3 cm 0 **necrotic** urethrovesicovaginal fistula **IIAa, leaking urine for 4 days** which started 14 days following craniotomy b.c.o. obstructed labor for 2 days, in hospital stillborn male infant, married 25 yr ago pre(menarche 9 yr later, she became pregnant for the first time 15 yr after marriage), still living with husband, no h/o drop foot, no RVF
EUO/F 2.5 cm, F/C 6 cm 145.0 cm

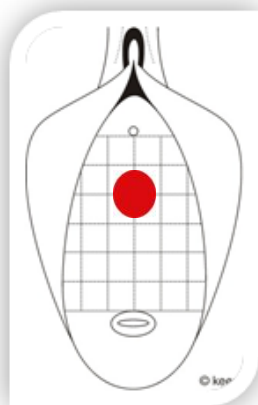
24/8-92 FOLEY Ch 18; later for primary suturing

08/09-92 early closure leaking urine for 19 days
± 1 cm 0 UVVF now within 3 cm 0 avw defect; removal of minimal necrosis, freshening, minimal dissection, transverse closure of bladder/urethra with inverting chromic catgut, avw closure with everting chromic catgut and 3x supramid; good bladder capacity (EUO/BW 10 cm), good elevation, EUO/B 3 cm anesthetic

22.09 + 06.10.92 cath out x 4/7 not leaking at all bladder drill
27.10.92 not leaking at all, no incontinence, normal miction
insp/ healed, moderate elevation, no stress incontinence

01.11.92 idem

18.01.93 not leaking at all, no incontinence, normal miction healed, no stress



3 cm

KANO
second obstetric fistula, documented 29.09.92

cath 103
rvf

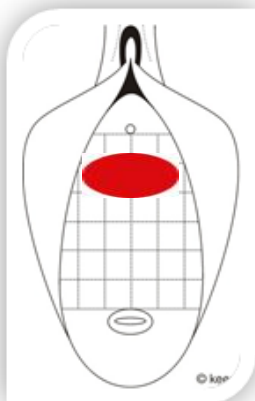
zsg (kano) female 24 yr 24/08-92

diagnosis: PII (1 alive), ± 4x2 cm urethrovesicovaginal fistula with circumferential defect **IIBb**, ± 8x4 cm area pvw loss with stricture but no RVF, **leaking urine for 17 days** which started immediately following cesarean section (she was leaking after first delivery as well which healed spontaneously) b.c.o. obstructed last labor for 1 day, a live female infant, married 12 yr ago pre(menarche 1 yr later), not living with husband, no h/o drop foot, no menstruation
 EUO/F 1 cm, F/C 4 cm 146.0 cm

24/08-92 early closure

freshening, minimal dissection, transverse closure with inverting chromic catgut, transverse avw closure with everting chromic catgut and 4x supramid, FOLEY Ch 20; good bladder capacity (EUO/BW 12 cm), good elevation, EUO/B 3 cm anestheti

07.09.92 cath put x 7/7 not leaking at all foley ch 18
 21.09.92 not leaking at all cath removed bladder drill
 21.09.92 not leaking at all, no incontinence, normal miction
 insp/ completely healed, no stress
 29/09-92 not leaking, no incontinence, normal miction pvw stricture
 insp/ healed, good elevation, no stress incontinence



4x2 cm

maprpb (kano city)

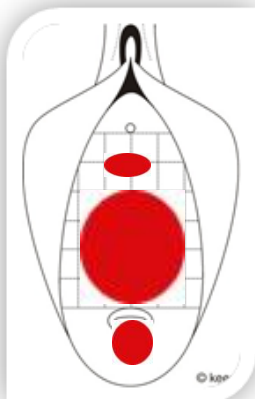
female 14 yr

24/08-92

diagnosis: PI, overflow incontinence due to atonic bladder with 1.5x1 cm necrotic avw **IIAa** (UVVF with seeping thru?), totally traumatized avw, severely traumatized proximal pwv, **leaking urine but not stools for 5 days** which started 1 day following obstructed labor for 1 day, in hospital a live male infant which died 1 day later, married 11 mth ago post(menarche 1 mth earlier), not living with husband, no h/o drop foot, bladder overfilled with >1 liter, EUO/BW 18 cm, but urine in vaginae +++
EUO/AVWN 1,5 cm 154.0 cm

24/8-92 FOLEY Ch 18; later for very good inspection

23.09 + 06.10.92 not leaking at all cath removed bladder drill
01/12-92 not leaking at all, no incontinence, normal miction
insp/ still **traumatized** avw, no stress incontinence



1.5x1 cm

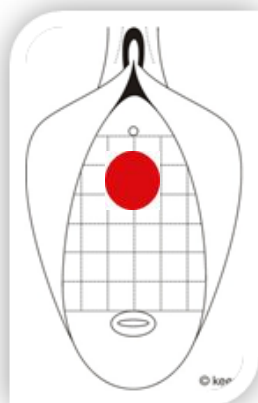
rmyg (kano) female 15 yr 24/08-92

diagnosis: PI, \pm 3 cm 0 necrotic urethrovesicovaginal fistula R/midline **IIAa, leaking urine for 12 days** which started immediately following obstructed labor for 2 days, at home stillborn male infant, married 3 yr ago pre(menarche 13 mth later), not living with husband, no h/o drop foot, no menstruation, also RVF, partial loss of labia minora, broken sphincter ani
EUO/F 2 cm, F/C 8 cm 153.0 cm

07/09-92 early closure

freshening, minimal dissection (also from R pubic bone), transverse closure with inverting chromic catgut, transverse avw closure with everting chromic catgut and 3x supramid, FOLEY Ch 18; moderate bladder capacity (EUO/BW 9 cm), good elevation, EUO/B 3 cm anesthetic

23.09 + 05.10.92 not leaking at all cath removed bladder drill
12.10.92 not leaking, incontinence +, normal miction healed, stress +
07/11-92 not leaking, incontinence \pm , normal miction
insp/ healed, good elevation, stress incontinence \pm



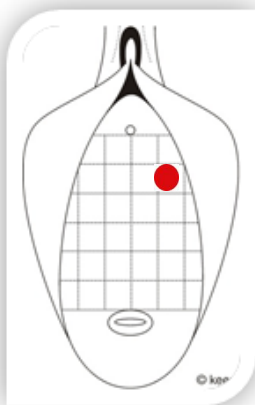
3 cm

hrk (kano) female 14 yr 25/08-92

diagnosis: PI, ± 1 cm 0 urethrovesicovaginal **IIAa** fistula L, **leaking urine for 21 days which started 15 days** following forceps delivery b.c.o. obstructed labor for 3 days, stillborn male infant, married 1 yr ago pre(menarche 3 mth later), not living with husband, drop foot R (grade 4), no menstruation, no RVF, open episiotomy L
EUO/F 2 cm, F/C 7 cm 144.0 cm

25/08-92 early closure
freshening, minimal dissection, transverse closure with inverting chromic catgut, transverse avw closure with everting chromic catgut and 3x everting supramid, FOLEY Ch 16; good bladder capacity (EUO/BW 14 cm), good elevation, EUO/B 4 cm anesthetic

07.09 + 20.09.92 not leaking at all cath removed bladder drill
05.10.92 not leaking at all, no incontinence, normal miction
insp/ healed, good elevation, no stress incontinence
18/01-93 not leaking, incontinence ±, normal miction EUO/BW 13 cm
insp/ healed, good elevation, no stress incontinence
moderate vagina stenosis



1 cm

KANO

cath 107

huk (kano city)

female

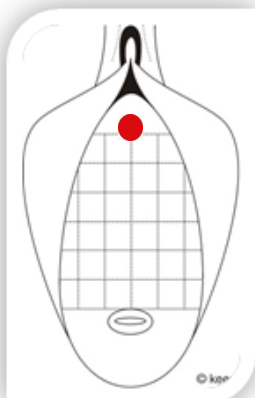
14 yr

25/08-92

diagnosis: PI, overflow incontinence due to atonic bladder, **leaking urine for 34 days** which started immediately following obstructed labor for 4 days, in hospital (eclampsia) stillborn female infant, married 1 yr ago pre(menarche 2 mth later), not living with husband, no h/o drop foot, no menstruation, also stool incontinence for 10 days, bladder overfilled (abdominal mass), avw bulging into vagina, EUO/BW 15 cm 161.0 cm

25/8-92 FOLEY Ch 18

08.09+ 22.09.92 not leaking at all cath removed bladder drill
28/10-92 not leaking at all, no incontinence, normal miction EUO/BW 10 cm
insp/ healed, no stress incontinence



hmkb (kano city)

female 18 yr

31/08-92

diagnosis: PII (0 alive), ± 4 cm 0 urethrovesicovaginal fistula **IIAb** with circumferential defect, **leaking urine for 24 days** which started immediately following laparotomy b.c.o. obstructed labor for 2 days, stillborn male infant, married 6 yr ago pre(menarche 1 yr later), not living with husband, no h/o drop foot, no RVF; N.B. also CS for first delivery
EUO/F 1.5 cm, F/C 5 cm 153.0 cm

31/08-92 early closure

freshening, minimal dissection, transverse closure with inverting chromic catgut, transverse avw closure with everting chromic catgut and 4x supramid, FOLEY Ch 18; good bladder capacity (EUO/BW 10 cm), reasonable elevation, EUO/B 2 cm

residual 4 cm fistula

also RVF

28/09-92 operation: circumferential UVVF-repair

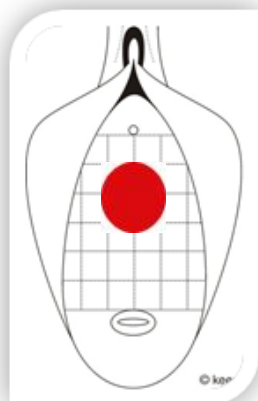
vvf 444

12.10.92 not leaking at all cath removed bladder drill

19.10.92 not leaking at all, no incontinence, normal miction
insp/ healed, poor elevation, no stress incontinence

20.12 + 17.01.93 idem

05.04.93 not leaking at all, no incontinence, normal miction healed, no stress



4 cm

mhdK (kano city)

female

23 yr

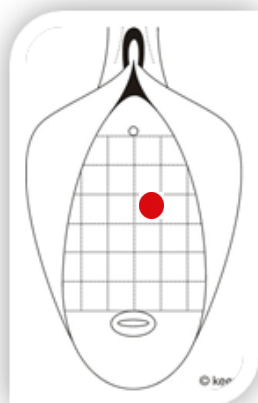
31/08-92

diagnosis: PIV (3 alive), \pm 1 cm 0 urethrovesicovaginal fistula slightly L bladder neck
IIAa, leaking urine for 15 days which started immediately following obstructed last labor for 2 days, in hospital stillborn male infant, married 12 yr ago pre(menarche 2 yr later), still living with husband, no h/o drop foot, no RVF, no menstruation
 EUO/F 3 cm, F/C 4 cm 150.0 cm

31/08-92 early closure

freshening, minimal dissection, transverse closure with inverting chromic catgut, transverse avw closure with everting chromic catgut and 3x supramid, FOLEY Ch 18; good bladder capacity (EUO/BW 11 cm), good elevation, EUO/B dist 4 cm anesthetic

14.09 + 28.09.92 not leaking at all cath removed bladder drill
 05.10.92 not leaking at all, no incontinence, normal miction
 insp/ healed, good elevation, no stress inontinence
 09.11.92 idem
 20.11.92 not leaking at all, no incontinence, normal miction healed, no stress



1 cm

KANO

cath 110

shuu (kano city)

female

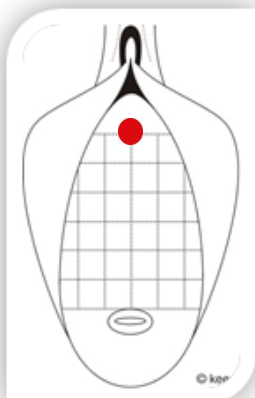
15 yr

31/08-92

diagnosis: PI, overflow incontinence due to atonic bladder, **leaking urine for 14 days which started 15 days** following obstructed labor for 1 day, in hospital stillborn female infant, married 2 yr ago post(menarche 3 mth earlier), not living with husband, no h/o drop foot, no menstruation, EUO/BW 15 cm, bladder overfilled 155.0 cm

31/8-92 FOLEY Ch 18

28.09.92 not leaking at all cath removed bladder drill
18/10-92 not leaking at all, no incontinence, normal miction EUO/BW 10 cm
insp/ healed, no stress incontinence

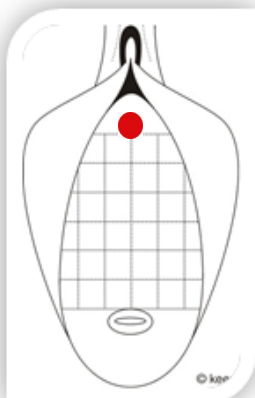


ark(kano) female 27 yr 28/07-92

diagnosis: PII (0 alive), overflow incontinence due to UV-stricture, bladder totally overfilled, leaking urine for 7 yr which started immediately following obstructed first labor for 2 days, at home stillborn male infant, married 15 yr ago pre(menarche 1 yr later), not living with husband, normal menstruation, drop foot R for 1 yr (now grade 5), no RVF, operated 2x (abdominally as well) 146.0 cm

28.07.92 gentle gradual dilatation thru H10 and FOLEY Ch 18

31.08.92 not leaking at all gv: no leakage/no spilling cath removed bladder drill



KANO

cath 112

mmydg (kano)

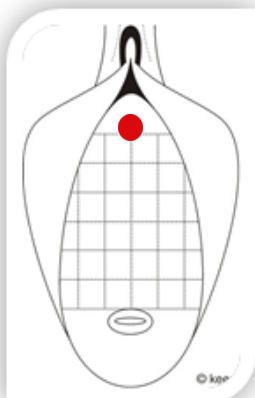
female 22 yr

31/08-92

diagnosis: PII (1 alive), overflow incontinence due to UV-stricture, bladder overfilled, leaking urine for 6 yr which started immediately following obstructed first labor for 2 days, at home stillborn male infant, married 10 yr ago pre(menarche 1 yr later), not living with husband, drop foot L (grade 3), normal menstruation, no RVF, operated 1x 157.0 cm

31/8-92 gentle gradual dilatation thru H10 and FOLEY Ch 18 later gv

14.08 + 28/09-92 not leaking at all cath removed bladder drill



aazk (kano city)

female

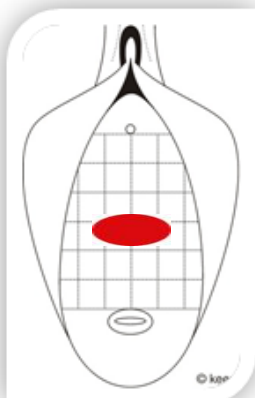
15 yr

01/09-92

diagnosis: PII (0 alive), ± 3x1 cm vesicovaginal fistula with circumferential defect **IIAb** and fixed to symphysis, **leaking urine for 31 days** which started immediately following obstructed last labor for 3 days, in hospital stillborn female infant, married 3 yr ago pre (menarche 9 mth later), not living with husband, no RVF, no h/o drop foot, normal menstruation
 EUO/F 4 cm, F/C 3 cm, AB/AU 0.5 cm 149.0 cm

01/09-92 primary suturing anesthetic
 freshening, minimal dissection, transverse avw closure with 5x everting supramid (more is not possible as access very poor), FOLEY Ch 18; good bladder capacity (EUO/BW 12 cm), good elevation, EUO/B 5 cm

15.09 + 29.09.92 not leaking at all cath removed bladder drill
 18.10.92 not leaking at all, no incontinence, normal miction
 insp/ healed, good elevation, no stress incontinence
 09.11.92 not leaking at all, no incontinence, normal miction healed, no stress



3x1 cm

hsyk (kano city) female 38 yr 01/09-92

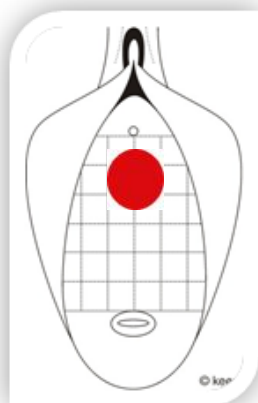
diagnosis: PVIII (6 alive), \pm 2.5 cm 0 urethrovesicovaginal fistula **IIBb** with circumferential defect, proximal rectovaginal fistula, **leaking urine/passing stools per vaginam for 59 days** which started immediately following obstructed last labor for 4 days, in hospital stillborn female infant, married 25 yr ago pre(menarche 3 mth later), still living with husband, no menstruation, drop foot R (grade 1) and L (grade 4); when seen 13/7 everything necrotic
EUO/F 1 cm, F/C 6 cm 158.0 cm

01/09-92 early "closure"
freshening, minimal dissection of avw, adaptation of bladder onto "urethra" with inverting chromic catgut, transverse avw closure with 4x everting supramid, FOLEY Ch 18; good bladder capacity (EUO/BW 12 cm), good elevation, EUO/B 2 cm anesthetic
not very much can be expected

residual 1 cm fistula

28/12-92 operation: UVVF-repair vvf 477

- 12.01.93 not leaking at all cath removed bladder drill
- 13.04.93 not leaking, incontinence \pm , normal miction **bladder drill**
insp/ healed, good elevation, stress incontinence \pm
- 11.05 + 13.06 + 15.06.93 idem insp_gv/ healed, not leaking, stress \pm
- 03.10.93 not leaking, incontinence \pm , normal miction healed, stress \pm



2.5 cm

tubl (kano)

female

20 yr

07/09-92

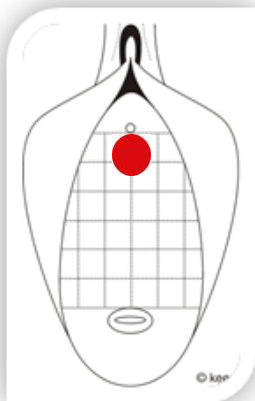
diagnosis: PI, \pm 2 cm 0 urethrovaginal fistula **IIBa, leaking urine for 40 days** which started immediately following obstructed labor for 5 days in hospital stillborn male infant, married 7 yr ago pre(menarche 3 mth later), not living with husband, no menstruation, no h/o drop foot, no RVF
 EUO/F 0.5 cm, F/C 8 cm 151.0 cm

07/09-92 early "closure"

freshening, minimal dissection, fixation of bladder/urethra opening onto distal symphysis, transverse avw closure with everting chromic catgut and 2x supramid, FOLEY Ch 18; moderate bladder capacity (EUO/BW 8 cm), elevation?, EUO/B 2 cm anesthetic

not very much can be expected

15.09 + 06.10.92 not leaking at all cath removed bladder drill
 12.10.92 not leaking at all, no incontinence, normal miction
 insp/ small residual fistula, no stress incontinence



2 cm

ria (jigawa)

female

31 yr

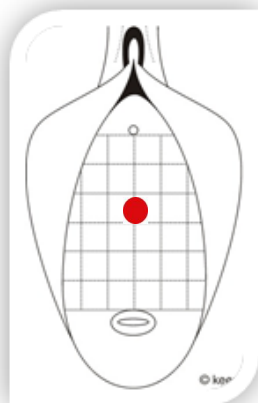
08/09-92

diagnosis: PVIII (4 alive), \pm 1 cm 0 vesicovaginal fistula **IIAa** midline bladder neck, **leaking urine for 30 days** which started immediately following obstructed last labor for 1 day, at home stillborn male infant, married 20 yr ago pre(menarche 2 yr later), not living with husband, no menstruation, no h/o drop foot, no RVF
 EUO/F 5 cm, F/C 6 cm 154.0 cm

08/09-92 early closure

freshening, minimal dissection, transverse bladder closure with inverting chromic catgut, transverse avw closure with everting chromic catgut/3x supramid, FOLEY Ch 18; good bladder capacity (EUO/BW 12 cm), good elevation, EUO/B 4 cm anesthetic

15.09 + 06.10.92 not leaking at all cath removed bladder drill
 18.10.92 not leaking at all, no incontinence, normal miction
 insp/ healed, good elevation, no stress incontinence
 20.12.92 not leaking at all, no incontinence, normal miction healed, no stress



1 cm

hmg (jigawa)

female

25 yr

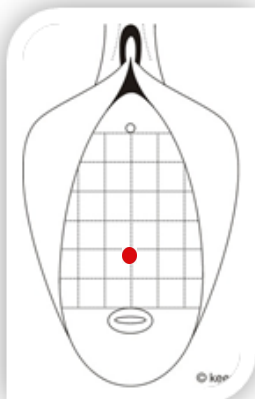
08/09-92

diagnosis: PIV (2 alive), \pm 3 mm vesicovaginal fistula I midline bladder base, **leaking urine for 35 days** which started immediately following obstructed last labor for 2 days, at home a live male infant, married 12 yr ago post(menarche 2 mth earlier), not living with husband, no menstruation, no h/o drop foot, no RVF, cystocele
 EUO/F 8 cm, F/C 3 cm 151.0 cm

08/09-92 early closure

freshening, minimal dissection, transverse bladder closure with inverting chromic catgut, transverse avw closure with everting chromic catgut/3x supramid, FOLEY Ch 18; good bladder capacity (EUO/BW 10 cm, cystocele ++, EUO/B 2.5 cm anesthetic

25.09 + 06.10.92 cath out x 2/7 cath removed bladder drill
 12.10.92 not leaking at all, no incontinence, normal miction
 insp/ healed, poor elevation/cystocele, no stress incontinence
 18.10.92 idem
 20.12.92 not leaking at all, no incontinence, normal miction healed, no stress



0.3 cm

KANO

cath 118

documented 14.09 + 21.09 + 28.09 + 12.10.92

ayd (kano city)

female

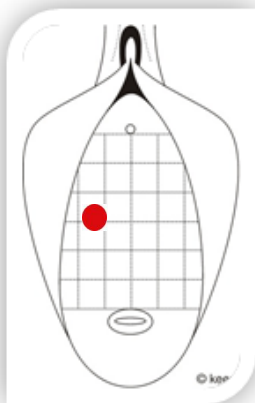
15 yr

14/09-92

diagnosis: PI, \pm 1 cm 0 necrotic avw midline bladder neck with fistula?? and stress incontinence **IIAa, leaking urine for 14 days** which started immediately following obstructed labor for 1 day, in hospital a live female infant which died the same day, married 4 yr ago pre(menarche 2 yr later), still living with husband, no h/o drop foot, no menstruation, no RVF; 100 ml gv: no leakage but color is shining thru (necrotic??) bladder
 EUO/F 5 cm, F/C 5 cm 143.0 cm

14/9-92 FOLEY Ch 18; good bladder capacity (EUO/BW 11 cm)
 review in 1 wk

20.09 + 28.09 + 12.10.92 not leaking at all cath removed bladder drill
 01/12-92 not leaking at all, no incontinence, normal miction
 insp/ healed, good elevation, no stress incontinence



1 cm

KANO

cath 119

hadw (kano city)

female

15 yr

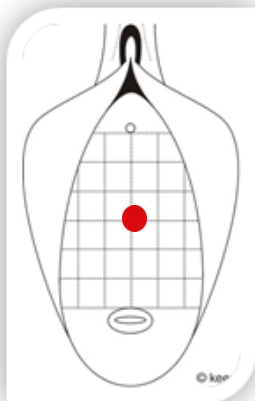
22/09-92

diagnosis: PI, ± 1 cm 0 **necrotic** avw **IIAa** at midline bladder neck with seeping thru, **leaking urine for 14 days** which started immediately following obstructed labor for 3 days, in hospital stillborn male infant, married 2 yr ago post(menarche 3 mth earlier), still living with husband, drop foot R (grade 3), no menstruation, no RVF;
 EUO/F 4 cm, F/C 4 cm 152.5 cm

22/9-92 FOLEY Ch 18; later for primary suturing though I would not be surprised if it heals off spontaneously

28/09-92 primary suturing freshening, transverse avw closure by 2x chromic catgut/3x supramid, FOLEY Ch 18; free urine flow, EUO/BW 12 cm, good elevation, EUO/B 4 cm anesthetic

- 12.10 + 19.10.92 cath out x 2/7 not leaking at all bladder drill
- 09.11.92 not leaking at all, no incontinence, normal miction
 insp/ healed, good elevation, no stress incontinence
- 01.12.92 idem
- 03.05.93 not leaking at all, no incontinence, normal miction healed, no stress



1 cm

KANO

cath 120

kmdknr (kano city)

female

16 yr

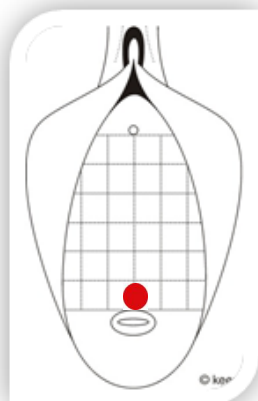
22/09-92

diagnosis: PI, \pm 5 mm 0 vesicovaginal fistula I midline bladder base just in front of cervix, **leaking urine for 22 days which started 19 days** following obstructed labor for 4 days, in hospital stillborn female infant, married 3 yr ago post(menarche 5 mth earlier), not living with husband, no menstruation, no RVF, no h/o drop foot
EUO/F 10 cm, F/C 0 cm 172.0 cm

22/09-92 early closure

freshening, minimal dissection, longitudinal bladder closure with inverting chromic catgut, transverse avw closure with everting chromic catgut/3x supramid, FOLEY Ch 18; good bladder capacity (EUO/BW 10 cm), reasonable elevation, EUO/B 4 cm anesthetic

- 05.10 + 19.10.92 cath put x 2/7 not leaking (only at night) bladder drill
- 27.10.92 not leaking at all, no incontinence, normal miction
insp/ healed, good elevation, no stress incontinence
- 01.12 + 18.01.93 idem
- 19.04.93 not leaking at all, no incontinence, normalmiction healed, no stress



0.5 cm

KANO

cath 121

saadn (kano city)

female

18 yr

28/09-92

diagnosis: PI, \pm 2 mm 0 vesicovaginal fistula? I midline bladder base, **leaking urine for 24 days which started 14 days** following CS b.c.o. obstructed labor for 2 days, stillborn male infant, married 1 yr ago post(menarche 4 mth earlier), not living with husband, no h/o drop foot, no menstruation (lochia), no RVF

when she passes stools she passes urine as well
EUO/F 10 cm, F/C 0 cm

149.5 cm

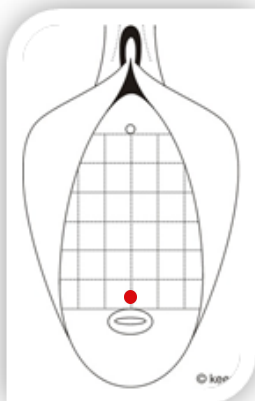
28/9-92 FOLEY Ch 18; later for gv

12.10 + 09.11.92 not leaking at all cath removed bladder drill

17.11.92 not leaking at all, no incontinence, normal miction
insp/ healed, good elevation, no stress incontinence

01.12.92 idem

26.04.93 not leaking at all, no incontinence, normal miction healed, no stress



0.2 cm

KANO

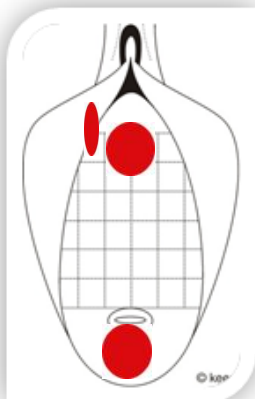
cath 122
RVF

bag (kano) female 24 yr 28/09-92

diagnosis: PI, overflow incontinence due to atonic bladder (with distal urethra loss IIBa??), **leaking urine for 14 days** which started immediately following obstructed labor for 2 days, in hospital stillborn male infant, married 12 yr ago pre(menarche 1 yr later), not living with husband, no menstruation, drop foot R (grade 4), no RVF, bladder overfilled (> 1 liter)
paraurethra tear at R actually distally from "euo"
necrotic avw/pvw 145.0 cm

28/9-92 FOLEY Ch 18; later for very good inspection

12.10 + 27.10.92 not leaking at all cath removed bladder drill
09.11.92 not leaking at all, no incontinence, normal miction
insp/ healed, good elevation, no stress incontinence
17.11.92 idem
02.12.92 not leaking at all, no incontinence, normal miction healed, no stress



KANO
documented 28.09.92 before/after

cath 123

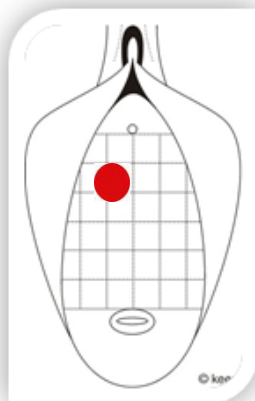
ask (kano city) female 15 yr 28/09-92

diagnosis: PI, \pm 2 cm 0 urethrovesicovaginal fistula **IIAa** slightly at R bladder neck, **leaking urine for 29 days** which started immediately following obstructed labor for 3 days, in hospital stillborn male infant, married 1.5 yr ago post(menarche 3 mth earlier), not living with husband, no menstruation, no h/o drop foot, no RVF
EUO/F 2 cm, F/C 6 cm 146.5 cm

28/09-92 early closure

freshening, minimal dissection, transverse bladder closure with inverting chromic catgut, transverse avw closure with everting chromic cat gut and 3x supramid, FOLEY Ch 18; good bladder capacity (EUO/BW 10 cm), reasonable elevation, EUO/B 3 cm anesthetic

12.10 + 09.11.92 leaking small cath removed bladder drill
17.11.92 leaking small, normal miction healed, stress +
07.12.92 idem
03/08-93 not leaking, occasionally incontinence \pm , normal miction insp/ healed, moderate elevation, stress incontinence +



2 cm

KANO

cath 124

sdg (kano)

female

35 yr

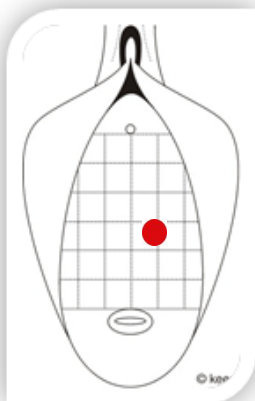
29/09-92

diagnosis: PIX (5 alive), ± 1 cm 0 vesicovaginal fistula L bladder base I, leaking urine for 3 mth which started 2 days following obstructed last labor for 2 days, in hospital a live male infant, married 25 yr ago pre(menarche 4 yr later), still living with husband, no menstruation, bilateral drop foot for 2 mth (now both grade 5), no RVF
EUO/F 6 cm, F/C 3 cm 151.0 cm

29/09-92 early closure

freshening, minimal dissection, transverse bladder closure with inverting chromic catgut, transverse avw closure with everting chromic cat gut and 3x supramid, FOLEY Ch 18; good bladder capacity (EUO/BW 10 cm), no elevation, EUO/B 3 cm anesthetic

- 19.10 + 27.10.92 cathout x 1/7 not leaking at all bladder drill
- 10.11.92 not leaking at all, no incontinence, normal miction
insp/ healed, poor elevation, no stress incontinence
- 17.11.92 idem
- 02.12.92 not leaking at all, no incontinence, normal miction healed, no stress



1 cm

KANO
documentation vulva 05.10.92

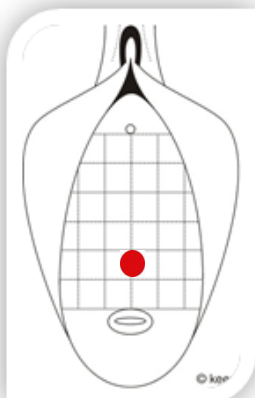
cath 125

hgk (kano city) female 19 yr 05/10-92

diagnosis: PII (2 alive), overflow incontinence due to atonic bladder or stress incontinence, **leaking urine (only at daytime) for 54 days** which started immediately following obstructed last labor for 1 day, at home a live female infant, married 5 yr ago post(menarche 1 yr earlier), still living with husband, no h/o drop foot, no menstruation, no RVF, open labia minora
EUO/BW 12 cm, bladder overfilled 154.0 cm

5/10-92 FOLEY Ch 18

19.10 + 24.11.92 not leaking at all cath removed bladder drill
07.12.92 not leaking at all, no incontinence, normal miction
insp/ healed, poor elevation/cystocele, no stress incontinence
18.01.93 idem
05.04.93 not leaking at all, no incontinence, normal miction healed, no stress



KANO

cath 126

hab (kano)

female

40 yr

05/10-92

diagnosis: PXI (3 alive), vesicouterine fistula, **leaking urine for 49 days** which started immediately following subtotal CS-hysterectomy b.c.o. ruptured uterus due to obstructed last labor for 3 days, stillborn male infant, married 27 yr ago post (menarche 2 mth earlier), still living with husband, no menstruation, no RVF, no h/o drop foot; cave ureter fistula as she also passes urine spontaneously 146.0 cm

5/10-92 FOLEY Ch 18; later again for gv

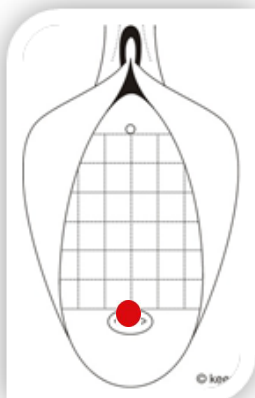
19.10 + 17.11.92 incontinence cath removed bladder drill

01.12.93 not leaking at all, no incontinence, normal miction

insp/ urine in vaginae

19/04-93 not leaking at all, no incontinence, normal miction

insp/ urine in vaginae!! Insp_gv: **vesicouterine fistula**



KANO

cath 127

mmyj (kano)

female

17 yr

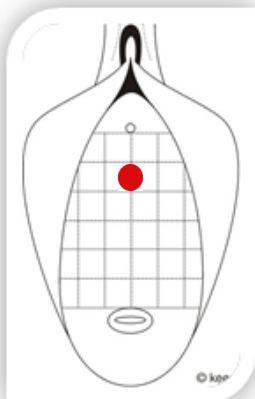
06/10-92

diagnosis: PII (0 alive), \pm 1 cm 0 urethrovesicovaginal fistula **IIAa, leaking urine for 20 days which started 7 days** following obstructed last labor for 3 days, in hospital stillborn male infant, married 5 yr ago pre(menarche 1 yr later), not living with husband no menstruation, no h/o drop foot, no RVF
EUO/F 1.5 cm, F/C 6 cm 144.0 cm

06/10-92 early closure

freshening, minimal dissection, transverse urethra closure with inverting chromic catgut, transverse avw closure with everting chromic cat gut and 3x supramid, FOLEY Ch 18; good bladder capacity (EUO/BW 11 cm), good elevation, EUO/B 3 cm anesthetic
this would heal without catheter

- 06.11.92 not leaking at all cath removed bladder drill
- 13.11.92 not leaking at all, no incontinence, normal miction
insp/ healed, good elevation, no stress incontinence
- 02.12.93 idem
- 19.04.93 not leaking at all, no incontinence, normal miction healed, no stress



1 cm

KANO
documented 12.10 + 21.12.92

cath 128

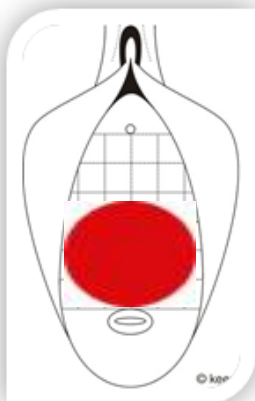
aiu (kano city) female 29 yr 12/10-92

diagnosis: PVI (3 alive), \pm 5x4 cm necrotic vesicovaginal fistula bladder neck/base **IIAa** and traumatized avw over bladder base, **leaking urine for 16 days which started 2 days** following obstructed last labor for 3 days, in hospital stillborn male infant, married 18 yr ago pre(menarche 2 yr later), still living with husband, no menstruation, drop foot R (grade 4) and L (grade 2), no RVF
EUO/F 4 cm 152.0 cm

12/10-92 FOLEY Ch 18; later for primary suturing or repair

21/12-92 early closure freshening, minimal dissection, transverse bladder closure by inverting chromic catgut, transverse avw closure by everting chromivc catgut/3x supramid, FOLEY Ch 18; free urine flow, EUO/BW 11 cm, good elevation, EUO/B 4 cm anesthetic

13.01 + 18.01.93 not leaking at all cath removed bladder drill
25.01.93 not leaking at all, no incontinence, normal miction
insp/ healed, good elevation, no stress incontinence
26.06.93 not leaking at all, no incontinence, normal miction healed, no stress



5x4 cm

zmkk (kano)

female

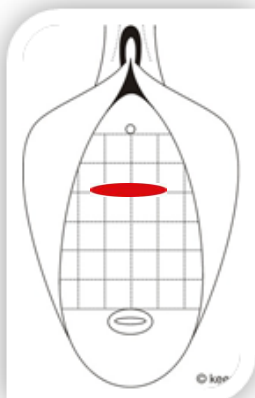
14 yr

19/10-92

diagnosis: PI, stress incontinence as bladder neck **IIAa** is traumatized (scarred), **leaking urine (only during daytime; normal micturition) for 28 days** which started 1 day following obstructed labor for 2 days, at home stillborn female infant, married 2 yr ago pre(menarche 1 yr later), not living with husband, no RVF, no menstruation, drop foot R (grade 3)
50 ml gv: no leakage 154.0 cm

19/10-92 FOLEY Ch 18

01.12.92 not leaking at all cath removed bladder drill
08.12.92 not leaking at all, no incontinence, normal miction
insp/ healed, good elevation, no stress incontinence
18.01.93 not leaking at all, no incontinence, normal miction healed, no stress



KANO

cath 130

mik (kano city)

female

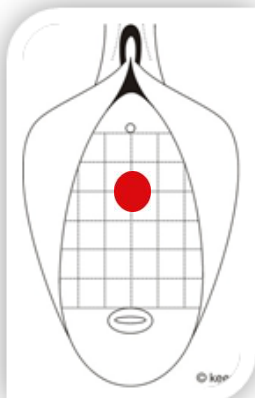
41 yr

19/10-92

diagnosis: PVII (3 alive), overflow incontinence due to atonic bladder or stress incontinence?, leaking urine day/night for 3 mth which started immediately following obstructed last labor for 1 day, at home stillborn male infant, married 30 yr ago pre(menarche 2 yr later), not living with husband, no menstruation, drop foot R (grade 3), no RVF, traumatized avw **IIAa** over bladder neck, EUO/BW 14 cm, bladder full but not overfilled 159.5 cm

19/10-92 FOLEY Ch 18

18.11.92 cathout x 1/7 not leaking at all bladder drill
24/11-92 not leaking at all, no incontinence, normal miction
insp/ healed, good elevation, no stress incontinence



KANO
documentation urethrocele 19.10

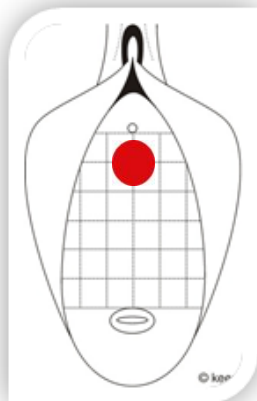
cath 131

sabdb (kano) female 14 yr 19/10-92

diagnosis: P0, \pm 2 cm 0 avw defect (with urethrocele and small fistula) **IIBa**, leaking urine for 3 mth which started immediately following yankan gishiri by wanzami b.c.o. ba hanya, married 8 mth ago post(menarche 2 mth earlier), not living with husband, normal menstruation; **vagina well developed**
EUO/F 1 cm, F/C 8 cm 166.0 cm

19/10-92 primary suturing
freshening, minimal dissection, transverse avw closure with everting dixon, FOLEY Ch 18, good bladder capacity (EUO/BW 13 cm), good elevation, EUO/B 3 cm anesthetic

23.11.93 cath out x 2/7 not leaking at all bladder drill
07.12.92 not leaking at all, no incontinence, normal miction
insp/ healed, good elevation, no stress incontinence
18.01.93 idem
05.04.93 not leaking at all, no incontinence, normal miction healed, no stress



2 cm

hag (jigawa)

female

21 yr

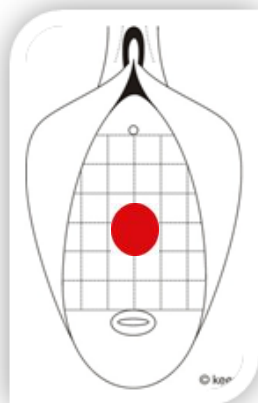
19/10-92

diagnosis: PIV (2 alive), extensive \pm 2 cm 0 urethrovesicovaginal fistula **IIAa** midline bladder neck/base, **leaking urine for 51 days which started 1 day** following obstructed last labor for 2 days, in hospital stillborn male infant, married 11 yr ago pre(menarche 3 yr later), still living with husband, no menstruation, no h/o drop foot no RVF
 EUO/F 3 cm, F/C 2 cm 153.5 cm

19/10-92 early closure

freshening, minimal dissection, transverse bladder closure with inverting chromic catgut, transverse avw closure with everting chromic catgut and dexton, FOLEY Ch 18; good bladder capacity (EUO/BW 12 cm), good elevation, EUO/B 3 cm anesthetic

- 16.11.92 cath out for 1/7 not leaking at all bladder drill
- 24.11.92 not leaking at all, no incontinence, normal miction
 insp/ healed, good elevation, no stress incontinence
- 20.12.92 not leaking at all, no incontinence, normal miction healed, no stress



2 cm

ritwdk (jigawa)

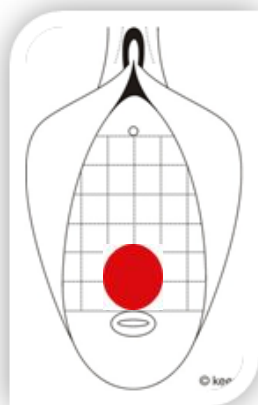
female 14 yr

19/10-92

diagnosis: PI, \pm 3 cm 0 **necrotic** vesicovaginal fistula I bladder base, **leaking urine for 3 days** which started 1 day following obstructed labor for 1 day, in hospital stillborn female infant, married 10 mth ago post(menarche 5 mth earlier), not living with husband, no menstruation, drop foot L (grade 4), no RVF, membranes still out of cervix; EUO/BW 18 cm
 EUO/F 6 cm, F/C 0 cm 149.5 cm

19/10-92 FOLEY Ch 18; later for primary suturing though it may heal off spontaneously

27.10 + 01.12 not leaking at all cath removed bladder drill
 08.12.92 not leaking at all, no incontinence, normal miction
 insp/ healed, good elevation, no stress incontinence
 17.05.93 not leaking at all, no incontinence, normal miction healed, no stress



3 cm

KANO

cath 134

mktw (kano city)

female

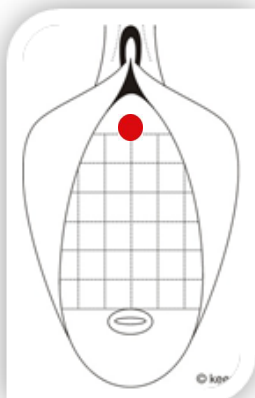
22 yr

23/10-92

diagnosis: PIV (2 alive), overflow incontinence due to atonic bladder, **leaking urine for 40 days** which started immediately following obstructed last labor for 1 day, in hospital stillborn male infant, married 10 yr ago pre(menarche 1 yr later), still living with husband, no h/o drop foot, no menstruation, no RVF; EUO/BW 15 cm, >1 liter 153.0 cm

23/10-92 FOLEY Ch 18

20.12.92 not leaking at all cath removed bladder drill
28/12-92 not leaking at all, no incontinence, normal miction
insp/ healed, no stress incontinence



KANO

cath 135

hsaw (kano)

female

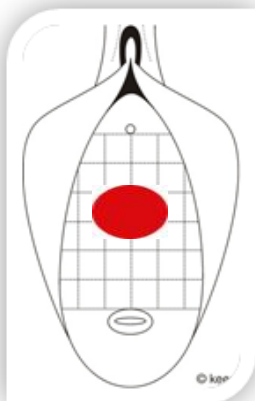
31 yr

14/12-92

diagnosis: PVII (5 alive), incontinence (check with 100 ml gv no leakage), 4x3 cm **scarred** avw area at bladder neck (when first seen 10/11 still necrosis) **IIAa, leaking urine day/night for 45 days which started 4 days** following obstructed last labor for 1 day, at home stillborn female infant, married 20 yr ago pre(menarche 2 yr later), still living with husband, bilateral drop foot for 1 mth (both grade 5 as compared to R grade 3 and L grade 4 when seen 10/11), no menstruation, no RVF
EUO/F 4 cm, F/C 5 cm 157.0 cm

14/12-92 FOLEY Ch 18

29.12 + 12.01.93 not leaking at all cath removed bladder drill
18/01-93 not leaking at all, no incontinence, normal miction
insp/ healed, good elevation, no stress incontinence



4x3 cm

haa (kaduna)

female

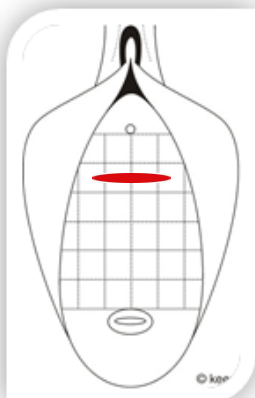
17 yr

14/12-92

diagnosis: PII (0 alive), scarred bladder neck with minute fistula **IIAa, leaking urine for 2 mth** which started immediately following obstructed last labor for 2 days, in hospital stillborn male infant, married 4 yr ago post(menarche 4 mth earlier), not living with husband, drop foot L (grade 2), no menstruation, no RVF;
 EUO/F 2 cm, F/C 7 cm 158.5 cm

14/12-92 FOLEY Ch 18, moderate bladder capacity (EUO/BW 9 cm), good elevation, EUO/B 2 cm

29.12 + 12.01.93 not leaking at all cath removed bladder drill
 18.01.93 not leaking, incontinence \pm , normal miction healed, no stress
 26/04-93 not leaking at all, no incontinence, normal miction
 insp/ healed, good elevation, no stress incontinence



minute fistula

KANO

cath 137

**urachus fistula!! type III
documentation of vesicocutaneous fistula 14.06**

ssb (kano city)

female

17 yr

14/12-92

diagnosis: PIII (1 alive), overflow? incontinence due to atonic bladder?, leaking urine for 3 mth which started 1 mth following obstructed last labor for 3 days, in hospital a live male infant, married 4 yr ago post(menarche 4 mth earlier), still living with husband, no h/o drop foot, normal menstruation, no RVF; had **lower abdominal operation at age of 5 yr (pat does not know what for)**

EUO/BW 14 cm, bladder full

166.5 cm

14/12-92 FOLEY Ch 18

14/06-93 vesicocutaneous fistula in scar of abdominal operation

13/09-93 operation: extirpation of fistulous tract

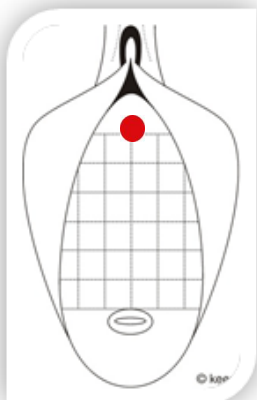
vvf 630

29.09 + 24.10.93 not leaking at all cath removed bladder drill

31.10.93 not leaking, no incontinence, normal miction wound healed, no stress

30.01.94 abdominal wound 2 0 open for 3 days **??how??** ch 18

17/04-94 not leaking at all, no incontinence, normal miction **wound healed**



hmsd (kano city)

female

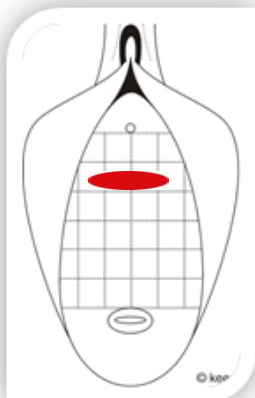
14 yr

14/12-92

diagnosis: PI, 3x1 cm traumatized avw area over bladder neck with minute fistula
IIAa, leaking urine for 1 mth which started 5 days following obstructed labor for 1 day, in hospital stillborn male infant, married 1 yr ago post(menarche 3 mth earlier), not living with husband, no h/o drop foot, no menstruation, no RVF
EUO/F 2.5 cm, F/C 6 cm 159.0 cm

14/12-92 FOLEY Ch 18

11.01.93 cath out x 1/7 not leaking at all bladder drill
25.01.93 not leaking at all, no incontinence, normal miction
insp/ healed, good elevation, no stress incontinence
03.05.93 not leaking at all, no incontinence, normal miction healed, no stress



3x1 cm

lhz (kano)

female

27 yr

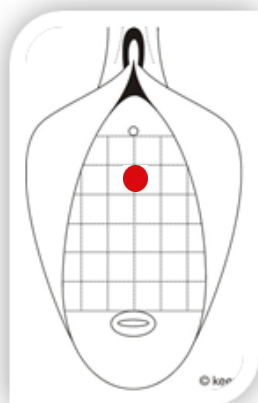
14/12-92

diagnosis: PIV (2 alive), ± 5 mm 0 urethrovesicovaginal fistula midline bladder neck
IIAa, leaking urine for 44 days which started 2 days following obstructed
 last labor for 1 day, in hospital a live male infant, married 16 yr ago
 pre(menarche 1 yr later), still living with husband, no h/o drop foot, no
 menstruation, no RVF
 EUO/F 2.5 cm, F/C 8 cm 143.5 cm

14/12-92 early closure

freshening, minimal dissection, transverse bladder/urethra closure by
 chromic catgut 00, transverse avw closure with chromic catgut/2x
 supramid; FOLEY Ch 18, good bladder capacity (EUO/BW 12 cm), good
 elevation, EUO/B 3 cm anesthetic

- 12.01.93 cath out x 3/7 not leaking at all bladder drill
- 24.01.93 not leaking at all, no incontinence, normal miction
 insp/ healed, ?elevation?, no stress incontinence
- 05.04.93 not leaking at all, no incontinence, normal miction healed, no stress



0.5 cm

hyg (kano)

female

20 yr

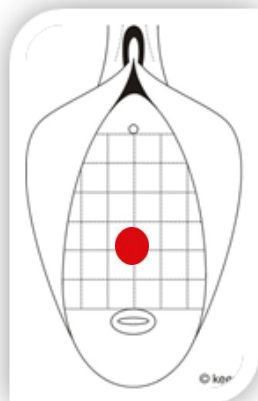
14/12-92

diagnosis: PIV (2 alive), \pm 1.5 cm 0 vesicovaginal fistula midline bladder base I, leaking urine for 3 mth which started 7 days following obstructed last labor for 4 days, in hospital stillborn male infant, married 8 yr ago pre(menarche 9 mth later), still living with husband, no h/o drop foot, normal menstruation, no RVF;
 EUO/F 6 cm, F/C 2.5 cm 151.5 cm

14/12-92 early closure

freshening, minimal dissection, only transverse adaptation of bladder with 2x chromic catgut 00, transverse avw closure with everting chromic catgut and 3x supramid; FOLEY Ch 20, moderate bladder capacity (EUO/BW 9 cm), good elevation, EUO/B 4 cm anesthetic

28.12 + 12.01.93	not leaking at all	cath removed	bladder drill
25.01.93	not leaking at all, no incontinence, normal miction insp/	healed, good levation, no stress incontinence	
05.04.93	not leaking at all, no incontinence, normal miction	healed, no stress	



1.5 cm

KANO

cath 141

radd (kano)

female

15 yr

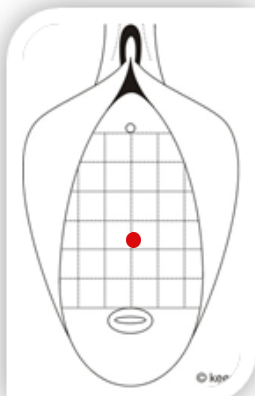
14/12-92

diagnosis: PI, minute vesicovaginal fistula I midline bladder base, **leaking urine for 54 days which started 2 days** following forceps delivery b.c.o. obstructed labor for 2 days, in hospital stillborn female infant, married 3 yr ago pre(menarche 1 yr later), not living with husband, drop foot R (grade 2), no menstruation, no RVF, broken episiotomy L
EUO/F 6 cm, F/C 4 cm 152.0 cm

14/12-92 early closure

freshening, minimal dissection, transverse bladder closure with chromic catgut, transverse avw closure with chromic catgut and 2x supramid; FOLEY Ch 18, good bladder capacity (EUO/BW 11 cm), elevation?, EUO/B 3 cm anesthetic

29.12 + 12.01.93 not leaking at all cath removed bladder drill
25/01-93 not leaking at all, no incontinence, normal miction
insp/ healed, poor elevation, no stress incontinence



minute fistula

KANO

cath 142

frm (kano)

female

25 yr

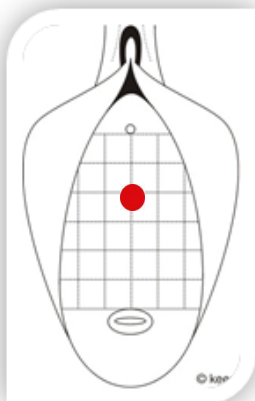
21/12-92

diagnosis: PVII (3 alive), ± 1x0.5 cm vesicovaginal fistula midline bladder neck **IIAa**, **leaking urine for 61 days** which started immediately following **2nd yankan gishiri by unguzoma** b.c.o. itching and protrusion from vagina 1 mth after last delivery (first yankan gishiri 3 mth before delivery), married 15 yr ago pre(menarche 5 yr later), still living with husband
EUO/F 4 cm, F/C 6 cm 144.0 cm

22/12-92 early closure

freshening, dissection, longitudinal bladder closure by inverting chromic catgut 00, longitudinal avw closure with everting chromic catgut 0/3x supramid; FOLEY Ch 18, good bladder capacity (EUO/BW 10 cm), cystocele, EUO/B 4 cm anesthetic

- 12.01 + 18.01.93 not leaking at all cath removed bladder drill
- 25.01.93 not leaking at all, no incontinence, normal miction
insp/ healed, poor elevation/cystocele, no stress incontinence
- 20.04.93 idem
- 26.06.93 not leaking at all, no incontinence, normal miction healed, no stress



1x0.5 cm

mshr (kano city)

female

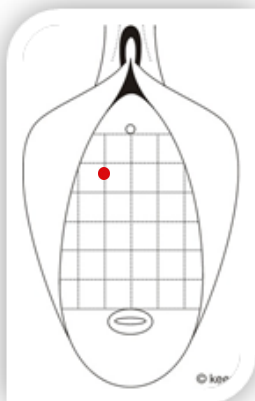
14 yr

23/11-92

diagnosis: PI, \pm 2 mm 0 vesicovaginal fistula R bladder neck **IIAa, leaking of urine for 27 days** which started immediately following obstructed labor for 2 days, in hospital a live male infant, married 1 yr ago post(menarche 2 mth earlier), still living with husband, no h/ drop foot, no menstruation, no RVF EUO/F 4 cm, F/C 7 cm 144.0 cm

23/11-92 FOLEY Ch 18

14.11 + 21.11.93 not leaking at all cath removed bladder drill
28/12-92 not leaking at all, no incontinence, normal miction
insp/ healed, good elevation, no stress incontinence



0.2 cm

hmsr (kano city)

female

16 yr

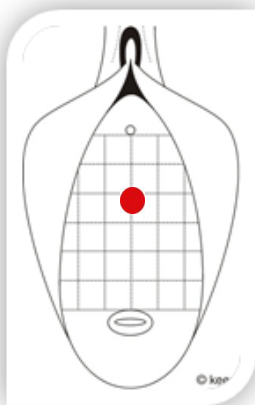
21/12-92

diagnosis: PII (0 alive), \pm 1 cm 0 urethrovesicovaginal fistula fixed to symphysis **IIAa**, **leaking urine for 2 mth** which started immediately following obstructed last labor for 1 day, in hospital stillborn male infant, married 3 yr ago pre(menarche 2 mth later), still living with husband, no h/o drop foot, no menstruation, no RVF
 EUO/F 3 cm, F/C 5 cm 145.5 cm

22/12-92 early closure

freshening, minimal dissection, transverse bladder/urethra closure with inverting chromic catgut 00, transverse avw closure with supramid with everting chromic catgut 0 and 3x supramid; FOLEY Ch 18, good bladder capacity (EUO/BW 10 cm), good elevation, EUO/B 4 cm anesthetic

- 12.01 + 18.01.93 not leaking at all cath removed bladder drill
- 25.01.93 not leaking at all, no incontinence, normal miction
 insp/ healed, good elevation, no stress incontinence
- 19.04.93 idem
- 26.06.93 not leaking at all, no incontinence, normal miction healed, no stress



1 cm

KANO
documented 21.12 before/after + 25.01 + 01.04 + 15.06

cath 145

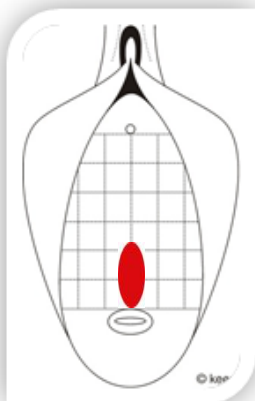
hsdt (kano city) female 24 yr 21/12-92

diagnosis: PV (1 alive), \pm 3x1 cm vesicovaginal fistula I midline/R bladder base, **leaking urine for 71 days** which started immediately following obstructed last labor for 3 days, in hospital stillborn male infant, married 12 yr ago pre(menarche 1 yr later), still living with husband, drop foot R (grade 3) and L (grade 2), no menstruation, no RVF
EUO/F 6 cm, F/C 0 cm 148.0 cm

22/12-92 early closure

freshening, minimal dissection, longitudinal bladder closure with inverting chromic catgut 00, longitudinal avw closure with everting chromic catgut 0 and 4x supramid; FOLEY Ch 18, good bladder capacity (EUO/BW 11 cm), good elevation, EUO/B 4 cm anesthetic

12.01 + 18.01.93 not leaking at all cath removed bladder drill
25.01.93 not leaking at all, no incontinence, normal miction
insp/ healed, good elevation, no stress incontinence
19.04.93 idem
15.06.93 not leaking at all, no incontinence, normal miction healed, no stress



3x1 cm

kbydk (kano city)

female

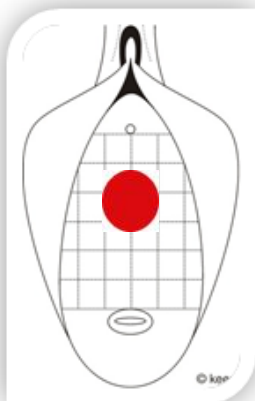
15 yr

21/12-92

diagnosis: PI, overflow incontinence due to atonic bladder, 2 cm avw defect **IIAa** mid line, **leaking urine for 4 days** that started immediately after obstructed labor for 1 day, in hospital stillborn male infant, married 2 yr ago pre(menarche 5 mth later), still living with husband, drop foot L (grade 3), no menstruation, no RVF; euo/avwt 2 cm, avwt/c 3 cm
EUO/BW 18 cm, >1 liter of urine 149.0 cm

22/12-92 FOLEY Ch 18

25.01.92 not leaking at all cath removed bladder drill
05/04-93 not leaking at all, no incontinence, normal miction
insp/ healed, good elevation, no stress incontinence



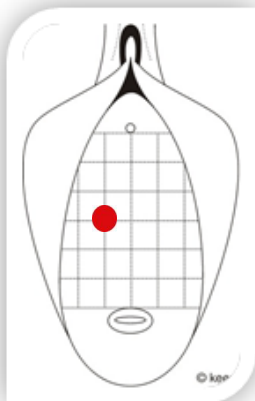
2 cm

mmmb (kano) female 24 yr 22/12-92

diagnosis: PII (0 alive), \pm 1.5 cm 0 vesicovaginal fistula R bladder neck **IIAa, leaking urine for 33 days** which started immediately following obstructed last labor for <1 day, at home a live male infant which died the same day, married 12 yr ago pre(menarche 1 yr later), still living with husband, no h/o drop foot, no menstruation, no RVF
EUO/F 5 cm, F/C 4 cm 151.0 cm

22/12-92 early closure
freshening, minimal dissection, transverse bladder closure with inverting chromic catgut, transverse avw closure with everting chromic catgut and 3x supramid; FOLEY Ch 18, moderate bladder capacity (EUO/BW 8 cm), no elevation, EUO/B 4 cm

15/06-93 not leaking at all, no incontinence, normal miction
insp/ healed, poor elevation, no stress incontinence



1.5 cm

hamb (kano)

female

15 yr

22/12-92

diagnosis: PI, \pm 2 mm 0 vesicovaginal fistula **IIAa** midline bladder neck, **leaking urine for 20 days which started 15 days** following obstructed labor for <1 day, in hospital a live male infant, married 2 yr ago pre(menarche 1 mth later), not living with husband, no h/o drop foot, no menstruation, no RVF

EUO/F 4 cm, F/C 5 cm

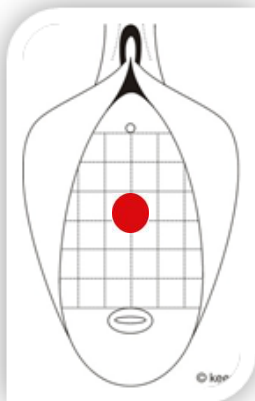
151.0 cm

22/12-92 primary suturing

freshening, transverse avw closure with everting chromic catgut 0 and 2x supramid; FOLEY Ch 18, good bladder capacity (EUO/BW 12 cm), good elevation, EUO/B 4 cm

anesthetic

12.01 + 18.01.93 not leaking at all cath removed bladder drill
26/04-93 not leaking, incontinence \pm , normal miction
insp/ healed, good elevation, no stress incontinence



KANO
documented 28.12.92 before/after

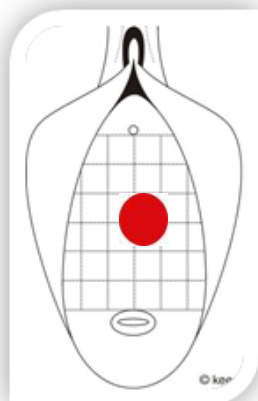
cath 149

hlst (kano city) female 29 yr 28/12-92

diagnosis: PVI (3 alive), \pm 3 cm 0 urethrovesicovaginal fistula **IIAa** midline/L, **leaking urine for 32 days** which started immediately following obstructed last labor for 1 day, at home stillborn male infant, married 18 yr ago pre (menarche 2 yr later), still living with husband, no h/o drop foot, no RVF
EUO/F 4 cm, F/C 4 cm 149.0 cm

28/12-92 early closure
freshening, dissection, transverse bladder/urethra closure with inverting chromic catgut, transverse avw closure with everting chromic cat gut and 5x supramid, FOLEY Ch 18; good bladder capacity (EUO/BW 10 cm), cystocele ++, EUO/B 4 cm anesthetic

25/01-93 not leaking at all catheter removed insp/ **breakdown**



3 cm

KANO
documented 14.12 + 28.12.92 before/after

cath 150

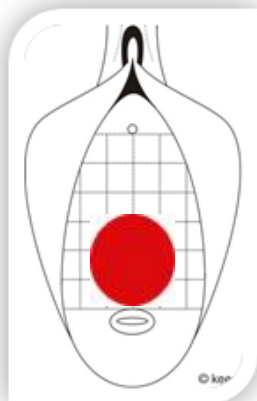
hadk (kano city) female 15 yr 14/12-92

diagnosis: PI, \pm 4 cm 0 traumatized avw **IIAa** with \pm 0.5 cm vesicovaginal fistula, **leaking urine for 2 days which started 15 days** following obstructed labor for 3 days, in hospital stillborn male infant, married 2 yr ago post(menarche 5 mth earlier), still living with husband, no menstruation, drop foot L (grade 4), no RVF
EUO/F 5 cm, F/C 3 cm, euo/avwt 4 cm, avwt/c 0 cm 148.5 cm

28/12-92 early closure

wound clean, freshening, minimal dissection, transverse bladder closure with inverting chromic catgut, partial transverse avw closure with 3x everting supramid, FOLEY Ch 18; good elevation, good bladder capacity (EUO/BW 10 cm), EUO/B 4 cm anesthetic

12.01 + 31.01.93 not leaking at all cath removed bladder drill
12.02.93 not leaking at all, no incontinence, normal miction
insp/ healed, good elevation, no stress incontinence
12.07.93 idem
16.08.93 not leaking at all, no incontinence, normal miction healed, no stress



4 cm

marl (kano city)

female

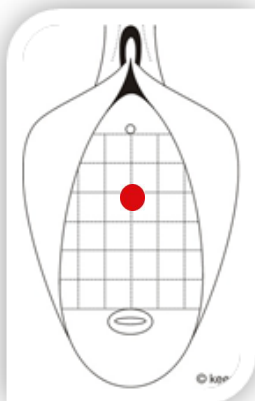
15 yr

28/12-92

diagnosis: PI, \pm 1 cm 0 necrotic vesicovaginal fistula **IIAa** midline bladder neck, **leaking urine for 9 days** which started immediately following vacuum extraction b.c.o. obstructed labor for 1 day, in hospital (eclampsia) stillborn male infant, married 1 yr ago post(menarche 1 yr earlier), not living at husband, no menstruation, drop foot R (grade 4), no RVF; no atonic bladder, EUO/BW 10 cm pat still in eclampsia ward
EUO/F 4 cm, F/C 6 cm 160.0 cm

28/12-92 FOLEY Ch 18; later for very good inspection; it may heal by catheter only

- 12.01 + 25.01.93 not leaking at all healed cath removed bladder drill
- 13.04.93 not leaking at all, no incontinence, normal miction
insp/ healed, good elevation, no stress incontinence
- 03.08.93 idem
- 05.09.93 not leaking at all, no incontinence, normal miction healed, no stress



1 cm

zzsg (jigawa)

female

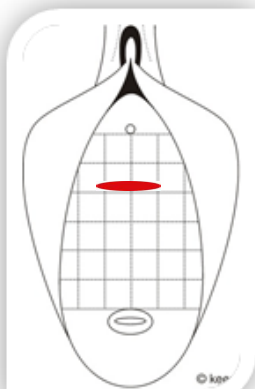
14 yr

29/12-92

diagnosis: PI, minute urethrovesicovaginal fistula **IIAa** within scar tissue, leaking urine for 3 mth which started 22 days following obstructed labor for 2 days, at home stillborn male infant, married 2 yr ago pre(menarche 7 mth later), not living with husband, normal menstruation, no h/o drop foot, no RVF, severe vagina stenosis/shortening, vagina only 6 cm deep
 EUO/F 2 cm, F/V 4 cm 147.5 cm

29/12-92 primary suturing anesthetic
 freshening, avw closure with 2x everting supramid, more is not possible, FOLEY Ch 18; good bladder capacity (EUO/BW 10 cm), good elevation, EUO/B 3 cm

12.01 not leaking 25.01.93 cath out x 2/7 not leaking at all bladder drill
 03/05-93 not leaking at all, no incontinence, normal miction
 insp/ healed, good elevation, no stress incontinence



minute fistula

smzg (kano)

female

14 yr

29/12-92

diagnosis: PI, extensive \pm 3 cm 0 urethrovesicovaginal fistula **IIAb** with circumferential defect, **leaking urine for 39 days which started 10 days** following obstructed labor for 4 days, in hospital stillborn male infant, married 1 yr ago pre(menarche 2 mth later), not living with husband, no menstruation, no h/o drop foot, no RVF, pvw stricture, when seen 14/12 still necrotic fistula, lpl stricture
 EUO/F 2 cm, F/C 5 cm 146.0 cm

29/12-92 early closure

freshening, circumferential dissection of bladder from pubic bones/symphysis, advancement and distal fixation of anterior bladder wall onto symphysis, circumferential UVVF-repair by end-to-end vesicourethrostomy with inverting chromic catgut, transverse avw closure with everting chromic catgut and 3x supramid, FOLEY Ch 20; good bladder capacity (EUO/BW 12 cm), good elevation, EUO/B 3 cm, a very difficult procedure; luckily the pat felt only closure of avw slightly anesthetic

05/04-93 leaking small fistula with UV-stricture

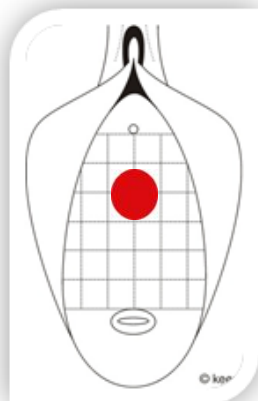
20/04-93 operation: UVVF-repair

vvf 519

11.05 + 08.06.93 not leaking at all cath removed bladder drill

13.06 + 28.06 + 22.08.93 not leaking, incontinence \pm , miction healed, no stress

18/10-93 not leaking at all, no incontinence, normal miction insp/ healed, good elevation, no stress incontinence



3 cm

KANO
documented 29.12 before/after + 25.01

cath 154

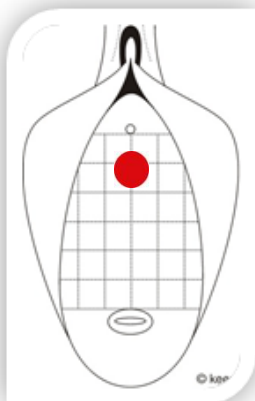
rabgm (kano city) female 17 yr 29/12-92

diagnosis: PI, \pm 1.5 cm 0 urethrovesicovaginal fistula **IIAa** midline, **leaking urine for 2 mth which started 1 day** following obstructed labor for 1 day, in hospital stillborn male infant, married 4 yr ago pre(menarche 4 mth later), not living with husband, no menstruation, drop foot L (grade 4), poliomyelitis R leg, no RVF
EUO/F 1.5 cm, F/C 7 cm 152.5 cm

29/12-92 early closure

freshening, minimal dissection, transverse bladder/urethra closure with inverting chromic catgut, transverse avw closure with everting chromic catgut and 2x supramid, FOLEY Ch 20; good bladder capacity (EUO/BW 14 cm), good elevation, EUO/B 3 cm anesthetic

12.01 + 23.01.93 not leaking at all cath removed bladder drill
05.04.93 not leaking at all, no incontinence, normal miction
insp/ healed, good elevation, stress incontinence \pm
24.05.93 not leaking at all, no incontinence, normal miction healed, stress \pm



1.5 cm

hatw (kano city)

female

16 yr

29/12-92

diagnosis: PI, \pm 5 mm 0 vesicovaginal fistula **IIAa** midline bladder neck, **leaking urine for 41 days** which started immediately following obstructed labor for 2 days, in hospital stillborn female infant, married 2.5 yr ago post(menarche 3 mth earlier), not living with husband, no menstruation, drop foot L (grade 4), no RVF

EUO/F 4 cm, F/C 6 cm

163.0 cm

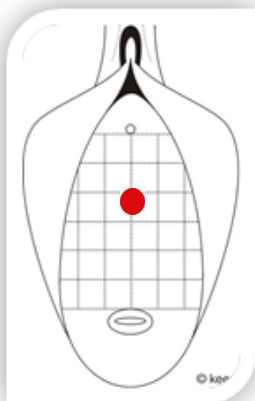
N.B. postpartum psychosis

29/12-92 early closure

freshening, minimal dissection, transverse bladder closure with inverting chromic catgut, transverse avw closure with everting chromic cat gut and 2x supramid, FOLEY Ch 18; good bladder capacity (EUO/BW 10 cm), good elevation, EUO/B 4 cm

anesthetic

- 12.01 + 25.01.93 not leaking at all cath removed bladder drill
- 05.04.93 not leaking at all, no incontinence, normal miction
- 17.05.93 not leaking at all, no incontinence, normal miction healed, no stress



0.5 cm

KANO

cath 156

aakk (kano city)

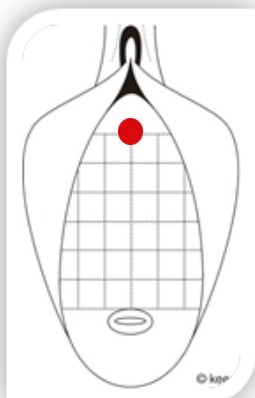
female 14 yr

01/12-92

diagnosis: PI, overflow incontinence due to atonic bladder, **leaking urine for 14 days** which started immediately following obstructed labor for 2 days, in hospital stillborn male infant, married 1 yr and 2 mth ago post(menarche 2 mth earlier), no menstruation, no h/o drop foot, no RVF
EUO/BW 15 cm, >1 liter 153.0 cm

1/12-92 FOLEY Ch 18

28.01.93 not leaking at all cath removed bladder drill
12/01-93 not leaking at all, no incontinence, normal miction
insp/ healed, no stress incontinence



KANO

cath 157

fok (kano city)

female

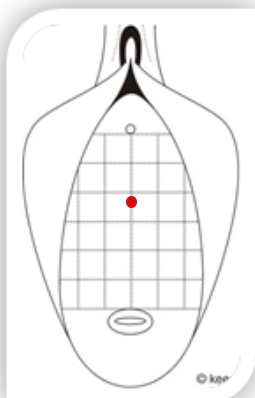
25 yr

11/01-93

diagnosis: PI, minute vesicovaginal fistula **IIAa** within scar line at bladder neck, **lea-king urine for 21 days which started 14 days** following vacuum delivery b.c.o. obstructed labor for 4 days, stillborn female infant, married 1 yr ago post(menarche 11 yr earlier), still living with husband, drop foot R (grade 3) and L (grade 4), no menstruation, no RVF
this pat finished secondary school!
EUO/F 4 cm, F/C 6 cm 150.0 cm

11/1-93 FOLEY Ch 18; most probably it will heal like this

26.01 + 14.02.93	not leaking at all	cath removed	bladder drill
19.04.93	not leaking at all, no incontinence, normal miction insp/	healed, moderate elevation, no stress incontinence	
16.08.93	not leaking at all, no incontinence, normal miction	healed, no stress	



minute fistula

adgk (kano city)

female

14 yr

11/01-93

diagnosis: PI, definitely stress incontinence, **leaking urine continuously day/ night for 18 days** which started immediately following obstructed labor for 2 days, in hospital stillborn male infant, married 1 yr 1 mth ago post(menar che 1 mth earlier), still living with husband, no menstruation, no h/o drop foot, no RVF

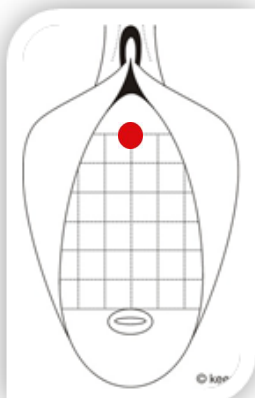
EUO/BW 10 cm, bladder not overfilled

145.5 cm

11/1-93 FOLEY Ch 18; eventually for gv testing

14.02.93 not leaking at all cath removed bladder drill

21/02-93 not leaking at all, no incontinence, normal miction
insp/ healed, good elevation, no stress incontinence



KANO

cath 159

second obstetric fistula; documented 11.01.93 before/after

tik (kano city) female 18 yr 11/01-93

diagnosis: PIII (0 alive), ± 1 cm 0 vesicovaginal fistula **IIAa** midline bladder neck, **leaking urine for 17 days which started 3 days** following obstructed last labor for 1 day, in hospital stillborn male infant, married 5 yr ago pre(menarche 2 mth later), still living with husband, no menstruation, no h/o drop foot, no RVF
N.B. successful VVF-repair 13/8-91 (mmsh) after 2nd delivery
EUO/F 4 cm, F/C 6 cm 157.0 cm

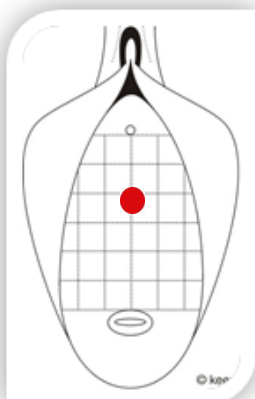
11/01-93 early closure

freshening, minimal dissection, transverse bladder/urethra closure with inverting chromic catgut, transverse avw closure with everting chromic catgut/3x supramid, FOLEY Ch 18; good bladder capacity (EUO/BW 11 cm), good elevation, EUO/B 4 cm anesthetic

25.01 + 10.02.93 not leaking at all cath removed bladder drill
17.02.93 not leaking at all, no incontinence, normal miction
insp/ healed, good elevation, no stress incontinence
10.04.93 idem
17.05.93 not leaking at all, no incontinence, normal miction healed, no stress

completely ok until **new third obstetric leakage**

21.11.11 PVII (1 alive) leaking urine whilst coughing/standing grade I-II for 5 days following choking in her own saliva insp/ **objective stress ++**
bladder drill for 2 wk **cath aajak**
15.12.111 not leaking at all, no incontinence, normal miction
insp/ healed, good elevation, no stress incontinence
31.01.12 not leaking at all, no incontinence, normal miction healed, no stress



1 cm

KANO
documented 11.01.93 before/after

cath 160

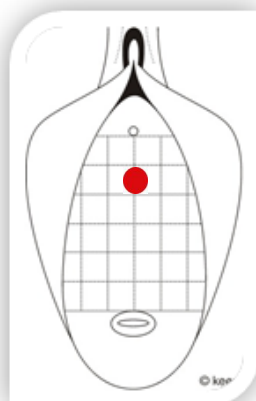
zatg (Kano) female 15 yr 11/01-93

diagnosis: PI, \pm 8 mm 0 urethrovesicovaginal fistula **IIAa** midline bladder neck, **leaking urine for 45 days which started 1 day** following obstructed labor for 3 days, in hospital stillborn male infant, married 2 yr ago pre(menarche 2 mth later), not living with husband, no menstruation, no h/o drop foot, no RVF
EUO/F 2 cm, F/C 5 cm 145.0 cm

11/01-93 early closure

freshening, minimal dissection, transverse bladder/urethra closure with inverting chromic catgut, transverse avw closure with everting chromic catgut and 3x supramid, FOLEY Ch 20; good bladder capacity (EUO/BW 12 cm), good elevation, EUO/B 4 cm anesthetic

25.01 + 14.02.93 not leaking at all
19.04.93 not leaking at all, no incontinence, normal miction
insp/ healed, good elevation, no stress incontinence
13.06.93 not leaking at all, no incontinence, normal miction healed, no stress



0.8 cm

KANO

cath 161

hsaw (Kano)

female

31 yr

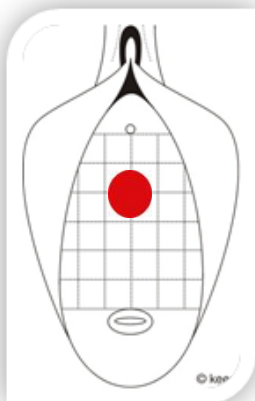
10/11-92

diagnosis: PVII (5 alive), \pm 3 cm 0 necrotic urethrovesicovaginal fistula **IIAa, leaking urine for 11 days which started 1 day** following obstructed last labor for 1 day, at home stillborn female infant, married 20 yr ago pre(menarche 2 yr later), still living with husband, no menstruation, no h/o drop foot, no RVF
EUO/F 3 cm, F/C 6 cm 157.0 cm

10/11-92 FOLEY Ch 18; later for primary suturing

12.01.93 not leaking at all cath removed bladder drill
completely healed, no stress incontinence

05/04-93 not leaking at all, no incontinence, normal miction
insp/ healed, good elevation, no stress incontinence



3 cm

KANO

cath 162

hadr (kano city)

female

18 yr

22/12-92

diagnosis: PI, ± 1.5 cm 0 partially necrotic urethrovesicovaginal fistula **IIAa, leaking urine for 19 days which started 1 day** following obstructed labor for 1 day, in hospital stillborn male infant, married 4 yr ago post(menarche 1 yr earlier), still living with husband, drop foot R (grade 3) and L (grade 4), no menstruation no RVF
EUO/F 3 cm, F/C 4 cm 153.0 cm

22/12-92 FOLEY Ch 18; later for primary suturing

12/01-93 early closure leaking urine for 41 days
now 1 cm 0 UVVF; freshening, minimal dissection, transverse bladder/urethra closure with inverting chromic catgut, transverse avw closure by everting chromic catgut/3x supramid, FOLEY Ch 18; moderate bladder capacity (EUO/BW 9 cm), good elevation, EUO/B 4 cm anesthetic

25.01.93 cath blocked x 5/7 leaking

24/05-93 only by 150 ml gv: minute residual UVVF

28/06-93 operation: UVVF-repair vvf 582

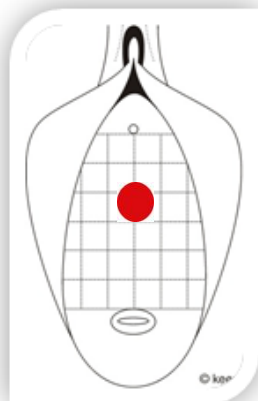
11.07.93 not leaking at all cath removed bladder drill

27.07.93 not leaking at all, no incontinence, normal miction

insp/ healed, moderate elevation, no stress incontinence

22.08 + 18.10 + 22.11.93 idem

22.12.93 not leaking at all, no incontinence, normal miction healed, no stress



1.5 cm

KANO

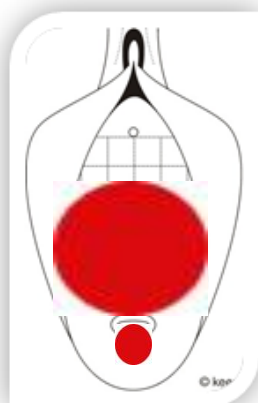
cath 163
rvf

kskn (kano) female 14 yr 17/01-93

diagnosis: PI, total urine incontinence grade III, \pm 4x3 cm avw defect **IIBa**, severe circumferential stricture and proximal pvw defect, 60 ml gv: no leakage, **leaking urine for 38 days which started 7 days** following obstructed labor of 2 days (pat eclamptic!), in hospital stillborn male infant, married 2 yr ago pre(menarche 6 mth later), not with husband, no menstruation, no h/o drop foot, no RVF; moderate bladder capacity (EUO/BW 7 cm) EUO/F 1 cm, due to stricture F/C not measured 148.0 cm

17/01-93 FOLEY Ch 18; later another check with gv

31.01 + 14.02.93 not leaking at all cath removed bladder drill
21/02-93 not leaking at all, no incontinence, normal miction
insp/ **both** healed, good elevation, no stress incontinence



4x3 cm

ssk (jigawa)

female

32 yr

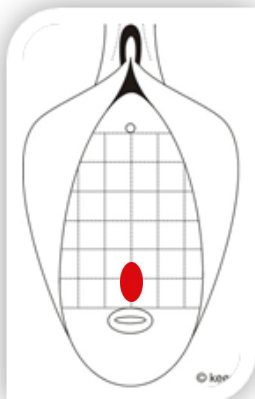
18/01-93

diagnosis: PX (5 alive), ± 2x1 cm vesicovaginal fistula (CS superimposed?) midline bladder base I, anterior cervix slightly traumatized, **leaking urine for 21 days which started 15 days** (immediately upon removal of catheter) following CS b.c.o. obstructed last labor for 1 day, a live male infant which died 4 days later, married 20 yr ago pre(menarche 1 yr later), still living with husband, no menstruation, no h/o drop foot, no RVF
 EUO/F 6 cm, F/C 0 cm 151.5 cm

18/01-93 early closure

freshening, minimal dissection, longitudinal bladder closure with inverting chromic catgut, longitudinal avw closure with everting chromic catgut and 4x supramid, FOLEY Ch 18; free urine flow, good bladder capacity (EUO/BW 11 cm), reasonable elevation, EUO/B 4 cm anesthetic

- 31.01 + 14.02.93 not leaking at all cath removed bladder drill
- 21.02.93 not leaking at all, no incontinence, normal miction
- insp/ healed, good elevation, no stress incontinence
- 26.04.93 not leaking at all, no incontinence, normal miction healed, no stress



2x1 cm

rsa (kaduna)

female

14 yr

18/01-93

diagnosis: PI, one \pm 1 cm 0 urethrovesicovaginal fistula (pressure necrosis) **IIAa** and one \pm 3 cm 0 CS-vesicocervicovaginal fistula, **leaking urine for 45 days** which started 4 days (upon catheter removal) following CS b.c.o. obstructed labor for 2 days, stillborn male infant, married 2 yr ago pre(menarche 6 mth later), not living with husband, no menstruation, drop foot R (grade 4), no RVF, severe vagina stenosis/shortening
 EUO/F 2 cm, F/F 1.5 cm, F/C 0 cm 143.0 cm

18/01-93 early closure

first stage

freshening of UVVF, minimal dissection, transverse bladder and urethra closure with inverting chromic catgut, transverse avw closure with 3x everting supramid, FOLEY Ch 20 to keep urethra open; EUO/BW 10 cm, good elevation, EUO/B 2.5 cm anesthetic
 if successful, later for CS-VCVF-repair

13/04-93 leaking insp/ **healed**

19/04-93 operation: CS_VCVF-"repair" second stage

vvf 515

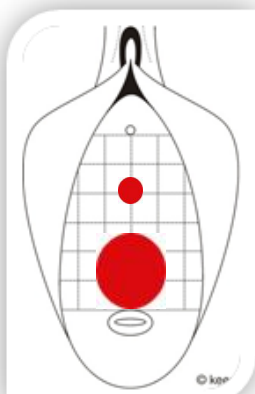
03.05.94 not leaking at all cath removed bladder drill

10.05.93 not leaking at all, no incontinence, normal miction

insp/ **both** healed, good elevation, no stress incontinence

24.05 + 05.09.93 idem

10.10.93 not leaking at all, no incontinence, normal miction **both** healed, no stress



multiple fistulas

zgbr (kano city)

female

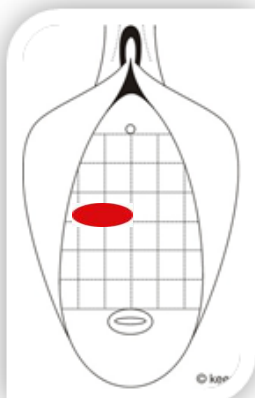
40 yr

18/01-93

diagnosis: PXI (6 alive), total urine stress incontinence grade III due to traumatized bladder neck, \pm 2.5x1 cm traumatized avw midline/R bladder neck **IIAa**, **leaking urine continuously for 45 days which started 1 day** following obstructed last labor for 1 day, in hospital stillborn male infant, married 30 yr ago pre(menarche 3 yr later), still living with husband, no menstruation, drop foot R (grade 4) and L (grade 2), no RVF, episiotomy L
EUO/F 5 cm, F/C 5 cm 159.5 cm

18/1-93 FOLEY Ch 18; good bladder capacity (EUO/BW 11 cm), good elevation, EUO/B 4 cm avw documented

31.01 + 14.02.93 not leaking at all cath removed bladder drill
21.02.93 not leaking at all, no incontinence, normal miction
insp/ healed, good elevation, no stress incontinence
05.04.93 not leaking at all, no incontinence, normal miction healed, no stress



2.5x1 cm

hsig (kano)

female

29 yr

21/12-92

diagnosis: PVI (1 alive), stress incontinence grade III or sminute vesicovaginal fistula R bladder neck **IIAa** within operation scar, leaking urine for 1 yr which started 14 days (upon catheter removal) following CS b.c.o. obstructed last labor for 2 days, stillborn male infant, married 17 yr ago pre(menarche 1 yr later), still living with husband, normal menstruation, no h/o drop foot, no RVF, operated 1x (BAKORI); 100 ml gv: no leakage, EUO/BW 12 cm, EUO/B 4 cm, ureter fistula??? healed sacrum scar EUO/F 4 cm, F/C 8 cm 162.5 cm

21/12-92 FOLEY Ch 18

04/01-93 with catheter no leakage

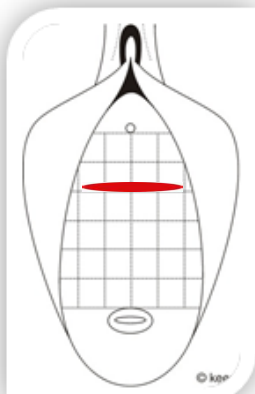
18/1-93 not leaking at all, catheter removed, avw/bladder neck seems completely healed

19.01.93 not leaking at all, no incontinence, normal miction

insp/ healed, poor elevation/cystocele, no stress incontinence

13.04.93 idem

26.06.93 not leaking at all, no incontinence, normal micturition healed, no stress



minute fistula

hasr (kano city)

female

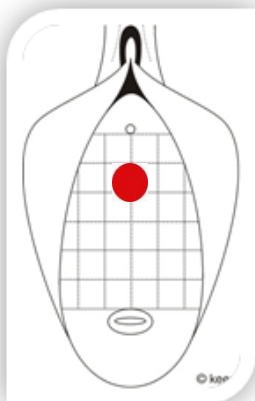
17 yr

19/01-93

diagnosis: PI, \pm 1.5 cm 0 urethrovesicovaginal fistula **IIAb** midline/L bladder neck with 3/4 circumferential defect (only R lateral bladder wall intact), **leaking urine for 18 days which started 15 days** following obstructed labor for 1 day, in hospital stillborn female infant, married 4 yr ago pre(menarche 2 mth later), still living with husband, no menstruation, no h/o drop foot, no RVF
 EUO/F 2 cm, F/C 8 cm 159.0 cm

19/01-93 **early closure** very difficult procedure
 freshening, minimal dissection, transverse bladder/urethra closure with inverting chromic catgut, transverse avw closure with everting chromic catgut and 3x supramid, FOLEY Ch 18; free urine flow, good bladder capacity (EUO/BW 16 cm), good elevation, EUO/B 3 cm anesthetic

31.01 + 14.02.93 not leaking at all cath removed bladder drill
 21/02-93 not leaking at all, no incontinence, normal miction
 insp/ healed, good elevation, no stress incontinence



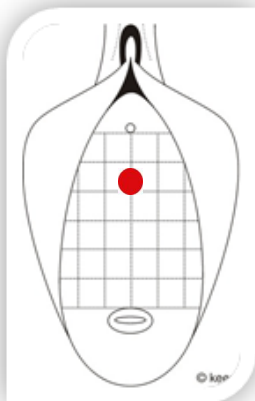
1.5 cm

HABIBA ABDU CHIRANCHI (kano city) female 35 yr 25/01-93

diagnosis: PVII (3 alive), ± 1 cm 0 urethrovesicovaginal fistula **IIAa, leaking urine for 39 days which started 1 day** following obstructed last labor for 1 day, in hospital stillborn male infant, married 25 yr ago pre(menarche 3 yr later), not living with husband, drop foot L (grade 3), no menstruation, no RVF
EUO/F 2 cm, F/C 6 cm 160.0 cm

25/01-93 early closure
freshening, minimal dissection, transverse bladder/urethra closure with inverting chromic catgut, transverse avw closure with everting chromic catgut and 3x supramid, FOLEY Ch 16; atonic bladder?? (EUO/BW 17 cm), good elevation, EUO/B 3 cm anesthetic

31.01 + 14.02.93 not leaking at all cath removed bladder drill
21/02-93 not leaking at all, no incontinence, normal miction
insp/ healed, good elevation, no stress incontinence



1 cm

KANO

cath 170

sig (kano city)

female

16 yr

25/01-93

diagnosis: PI, total urine stress incontinence III or fistula?, **leaking urine for 37 days which started 1 mth** following obstructed labor for 2 days, in hospital stillborn male infant, married 4 yr ago pre(menarche 1 yr later), not living with husband, drop foot R (grade 3), no menstruation, no RVF, severe vagina stenosis and shortening with avw stricture at 2 cm from EUO

good bladder capacity (EUO/BW 10 cm), EUO/B 3 cm

157.5 cm

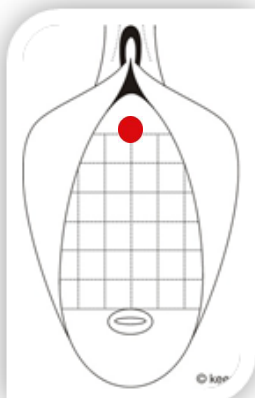
25/1-93

FOLEY Ch 18; later for gv

21.02.93 not leaking at all cath removed bladder drill

28/02-93 not leaking at all, no incontinence, normal miction

insp/ healed, good elevation, no stress incontinence



aak (kano city)

female

17 yr

01/02-93

diagnosis: PI, \pm 2 cm 0 necrotic vesicovaginal fistula **IIAa** midline bladder neck, **leaking urine for 14 days** which started immediately following obstructed labor for 3 days, in hospital stillborn male infant, married 4 yr ago pre(menarche 3 mth later), still living with husband, no menstruation, no h/o drop foot, no RVF
 EUO/F 4 cm, F/C 6 cm 155.0 cm

01/02-93 FOLEY Ch 18; later for primary suturing

15/02-93 not leaking at all, insp/ healed

01/03-93 not leaking at all, catheter removed

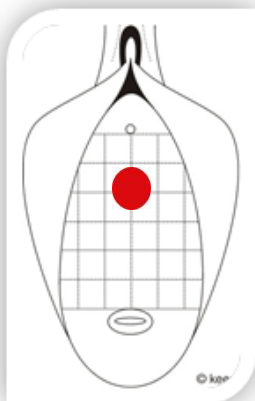
insp/ healed EUO/BW 12 cm, EUO/B 4 cm

05/04-93 not leaking at all, no incontinence, normal micturition

insp/ healed, no stress incontinence, good elevation

25/06-93 not leaking at all, no incontinence, normal miction

insp/ healed, good elevation, no stress incontinence



2 cm

KANO

cath 172

hamy (jigawa)

female

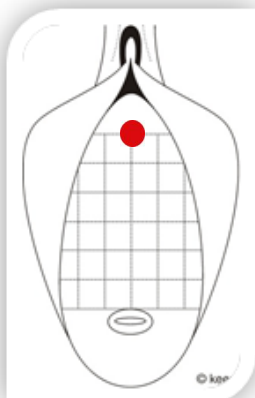
20 yr

15/02-93

diagnosis: PII (2 alive), **urine stress incontinence III for 1 mth which started 9 days** following obstructed last labor for 1 day, at home a live male infant, married 7 yr ago pre(menarche 2 mth later), still living with husband, no menstruation, no h/o drop foot, no RVF 154.0 cm

15/2-93 FOLEY Ch 18; good bladder capacity (EUO/BW 12 cm), good elevation, EUO/B 4 cm

19/04-93 not leaking at all, no incontinence, normal miction healed, no stress

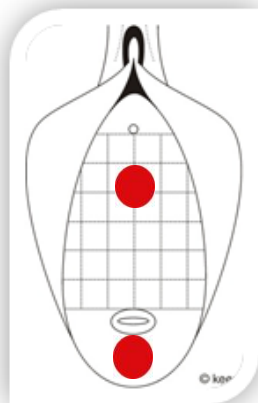


mirg (jigawa) female 15 yr 05/04-93

diagnosis: PI, ± 2 cm 0 necrotic urethrovesicovaginal fistula **IIAa** midline bladder neck, **leaking urine for 7 days which started 1 day** following obstructed labor for 4 days, in hospital stillborn male infant, married 1 yr ago post(men arche 1 yr earlier), still living with husband, no menstruation, drop foot R (grade 4) and L (grade 4), traumatized pvw
EUO/F 2 cm, F/C 6 cm 157.0 cm

05/04-93 FOLEY Ch 18; later for primary suturing

19.04 + 03.05.93 not leaking at all cath rremoved bladder drill
11/05-93 not leaking at all, no incontinence, normal miction
insp/ healed, moderate elevation, no stress incontinence



2 cm

amrg (kano city)

female

15 yr

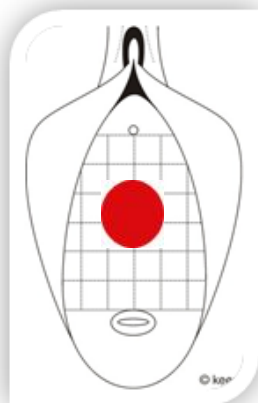
05/04-93

diagnosis: PI, extensive \pm 2.5 cm 0 urethrovesicovaginal fistula **IIAb** with circumferential defect, **leaking urine for 36 days which started 4 days** following obstructed labor for 1 day, at home stillborn male infant, married 3 yr ago pre(menarche 1 yr later), not living with husband, no menstruation, drop foot L (grade 3), no RVF; vagina shortening
 EUO/F 1.5 cm, F/C 2 cm 147.0 cm

05/04-93 early closure

freshening, minimal dissection, transverse bladder/urethra closure with interrupted inverting chromic catgut, transverse avw closure with everting chromic catgut/3x supramid, FOLEY Ch 18; free urine flow, small bladder capacity (EUO/BW 6 cm), good elevation, EUO/B 3 cm anesthetic

- 19.04 + 03.05.93 not leaking, incontinence cath removed bladder drill
- 10.05.93 not leaking, incontinence +, normal miction healed, stress +
- 24.05.93 not leaking, incontinence \pm , normal miction healed, no stress
- 26.06.93 not leaking at all, no incontinence, normal miction
 insp/ healed, good elevation, no stress incontinence
- 23.08.93 idem
- 03.10.93 not leaking at all, no incontinence, normal miction healed, no stress



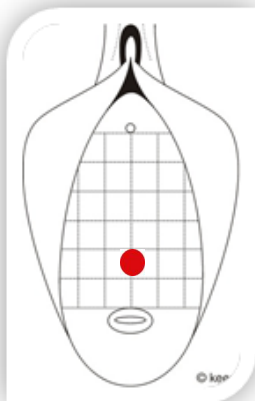
2.5 cm

hsg (kano) female 40 yr 05/04-93

diagnosis: PXI (6 alive), ± 1 cm 0 vesicovaginal fistula I midline bladder base, **leaking urine for 10 days which started 11 days** following obstructed last labor for 3 days, in hospital stillborn male infant, married 28 yr ago pre(menarche 1 yr later), still living with husband, no menstruation, no h/o drop foot, no RVF
EUO/F 6 cm, F/C 2 cm 163.0 cm

05/04-93 early closure anesthetic freshening, extirpation of some necrotic tissue, minimal dissection, transverse bladder closure by inverting chromic catgut transverse avw closure by everting chromic catgut/3x supramid, FOLEY Ch 18; free urine flow, good bladder capacity (EUO/BW 12 cm), good elevation, EUO/B 4 cm

19.04 + 03.05.93 not leaking at all cath removed bladder drill
10.05.93 not leaking at all, no incontinence, normal miction insp/ healed, moderate elevation, no stress incontinence
25.05 + 26.06 + 22.08.93 idem
17.10.93 not leaking at all, no incontinence, normal miction healed, no stress



1 cm

KANO
documented 12.04 + 08.06

cath 176

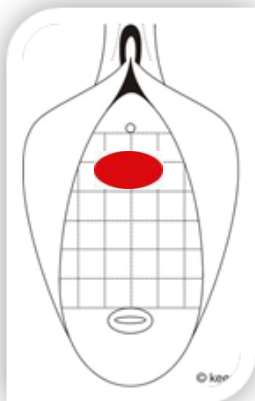
yhsu (kano city) female 21 yr 12/04-93

diagnosis: PIII (2 alive), ± 4x2 cm traumatized avw **IIAa** with necrosis midline,
leaking urine for 9 days which started 3 days following obstructed last
labor for 1 day, at home stillborn male twins, married 10 yr ago pre(men
arche 2 yr later), still living with husband, no menstruation, drop foot R
(grade 2), no RVF
EUO/F 1.5 cm, F/C 7 cm 163.0 cm

12/04-93 urine incontinence demonstrated on cough, as well seeping thru; FOLEY
Ch 18; later for primary suturing though it may heal

27/04-93 early ps minute UVVF documented 12/4 + 8/6
leaking urine for 27 days
freshening, transverse avw closure by 3x everting supramid; EUO/BW 17
cm, moderate elevation, EUO/B 2.5 cm anesthetic

10.05 + 24.05.93 not leaking at all cath removed bladder drill
08.06.93 not leaking at all, no incontinence, normal miction
insp/ healed, good elevation, no stress incontinence
20.06 + 03.08 + 30.08.93 idem
25.10.93 not leaking at all, no incontinence, normal miction healed, no stress



4x2 cm

zikt (kano city) female 15 yr 15/03-93

diagnosis: PI, ± 1 mm 0 vesicovaginal fistula I midline bladder base, **leaking urine for 17 days which started 21 days** following obstructed labor for 5 days, in hospital a live female infant, married 2 yr ago pre(menarche 2 mth later), not living with husband, no menstruation (lactation), drop foot R (grade 2) and L (grade 3), no RVF
EUO/F 8 cm, F/C 2 cm 149.0 cm

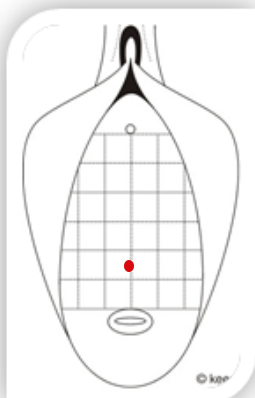
15/3-93 FOLEY Ch 18; this will heal spontaneously; good bladder capacity (EUO/BW 13 cm), good elevation, EUO/B 4 cm

13/4-93 no leakage, catheter removed
insp/ healed, no stress incontinence, good elevation

19.04.93 not leaking at all, no incontinence, normal miction
insp/ healed, good elevation, no stress incontinence

17.05 + 12.07.93 idem

16.08.93 not leaking at all, no incontinence, normal miction healed, no stress



0.1 cm

fhmg (jigawa)

female

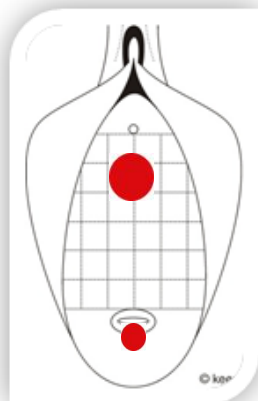
16 yr

19/04-93

diagnosis: PII (1 alive), \pm 2 cm 0 urethrovesicovaginal fistula **IIBb** with small circumferential defect, proximal rectovaginal fistula, **leaking urine and passing stools per vaginam for 30 days** which started immediately following obstructed last labor for 1 day, in hospital male stillborn, married 3 yr ago pre(menarche 10 days later), not living with husband, no menstruation, drop foot R (grade 3-4) and L (grade 3-4), eclampsia
 EUO/F 1 cm, F/C 5 cm 153.0 cm

19/04-93 early closure anesthetic
 freshening, minimal dissection, transverse bladder/urethra closure by inverting chromic catgut (anterior adaptation), transverse avw closure with everting chromic catgut/4x supramid, FOLEY Ch 18; free urine flow, moderate bladder capacity (EUO/BW 9 cm), good elevation, EUO/B 2.5 cm

03.05 + 17.05.93 not leaking at all cath removed bladder drill
 24.05.93 not leaking, incontinence \pm , normal miction healed, stress \pm
 29/09-93 not leaking at all, no incontinence, normal miction
 insp/ healed, good elevation, no stress incontinence



2 cm

KANO
documented 18.01.93

cath 179

amdg (kano city) female 15 yr 18/01-93

diagnosis: PI, \pm 3x2 cm necrotic vesicovaginal fistula **IIAa** bladder neck, **leaking urine for 4 days which started 14 days** following obstructed labor for 3 days, at home stillborn male, married 1 yr ago post (menarche 7 mth earlier), not living with husband, drop foot R (grade 4) and L (grade 1), no menstruation, no RVF
EUO/F 4 cm, F/C 3 cm 143.0 cm

18/01-93 FOLEY Ch 18; later for primary suturing

24/01-93 not clean yet

31/01-93 looks like it will heal spontaneously; not leaking at all

07.02.93 not leaking at all; almost healed

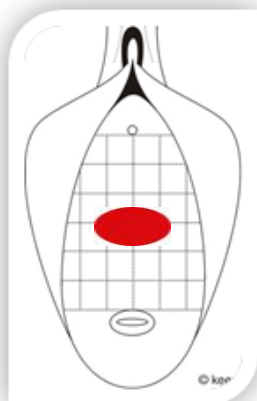
15/02-93 not leaking at all healed catheter removed

19/04-93 not leaking at all, no incontinence, normal menstruation

insp/ completely healed, no stress incontinence, good elevation

26/06-93 not leaking at all, no incontinence, normal miction

insp/ healed, good elevation, no stress incontinence



3x2 cm

hbs (kano city)

female

14 yr

20/04-93

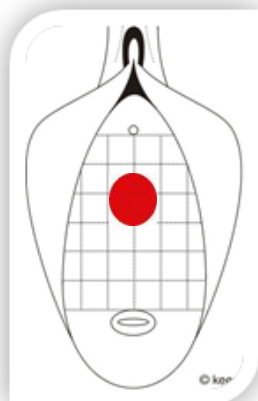
diagnosis: PI, extensive \pm 2 cm 0 urethrovesicovaginal fistula **IIAb** with small circumferential defect, **leaking urine for 15 days** which started immediately following obstructed labor for 3 days, in hospital stillborn female infant, married 1 yr ago pre(menarche 2 mth later), not living with husband, no menstruation, drop foot R (grade 4), no RVF, **minimal necrosis laterally**
EUO/F 1.5 cm, F/C 3 cm 151.5 cm

20/04-93 early closure

freshening, minimal dissection, transverse bladder/urethra closure with inverting chromic catgut, transverse avw closure by everting chromic catgut and 5x supramid, FOLEY Ch 20; free urine flow, good bladder capacity (EUO/ BW 14 cm), good elevation, EUO/B 4 cm anesthetic

03.05 + 17.05.93 not leaking at all cath removed bladder drill
25.05 + 06/06-93 not leaking, incontinence \pm , normal miction
insp/ healed, poor elevation, no stress incontinence
bladder overfilled with > 1,500 ml urine FOLEY Ch 18

04/07-93 not leaking at all catheter removed **bladder drill**



2 cm

hyhk (kano city)

female

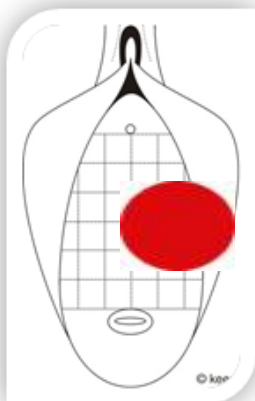
16 yr

18/04-93

diagnosis: PII (0 alive), \pm 5x4 cm necrotic urethrovesicovaginal **IIAa** fistula L bladder neck, **leaking urine for 11 days which started 2 days** following obstructed last labor for 1 day, in hospital stillborn male infant married 4 yr ago pre(menarche 1 yr later), not living with husband, no menstruation, drop foot R (grade 2 and L grade 5), no RVF
 EUO/F 3 cm, F/C 2 cm 155.0 cm

26/04-93 **early closure** clean \pm 4x2 cm urethrovesicovaginal fistula with circumferential defect; EUO/F 3 cm, F/C 2 cm
leaking urine for 21 days
 freshening, minimal dissection of avw from bladder/urethra, dissection of bladder from L pubic bone/symphysis, transverse closure of bladder/urethra by inverting chromic catgut starting with fixation of L lateral bladder wall to symphysis, transverse avw closure by everting chromic catgut/4x supramid, FOLEY Ch 18; free urine flow, good bladder capacity (EUO/ BW 12 cm) and EUO/B 4 cm anesthetic

10.05 + 24.05.93 not leaking at all cath removed bladder drill
 08.06.93 not leaking (only at night \pm), no incontinence, normal miction insp/ healed, good elevation, no stress incontinence
 26.06.93 not leaking (only at night \pm), no incontinence, miction healed, no stress



5x4 cm

zsk (kano city)

female

33 yr

26/04-93

diagnosis: PVII (3 alive), ± 1 cm 0 urethrovesicovaginal fistula L bladder neck **IIAa**, **leaking urine for 45 days** which started immediately following CS b.c.o. obstructed last labor for 2 days, stillborn male infant, married 20 yr ago pre(menarche 3 mth later), still living with husband, no menstruation, drop foot R (grade 4), no RVF, also avw trauma in front of cervix
 EUO/F 2.5 cm, F/C 6 cm 150.0 cm

26/04-93 early closure

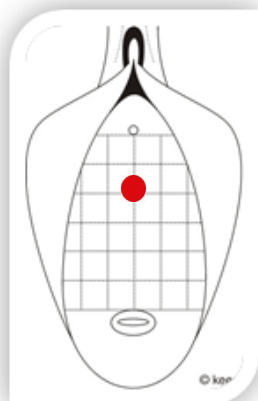
freshening, minimal dissection, transverse bladder/urethra closure with inverting chromic catgut, transverse avw closure with everting chromic catgut and 3x supramid, FOLEY Ch 18; free urine flow, good bladder capacity (EUO/ BW 10 cm), no elevation, EUO/B 3 cm anesthetic

- 10.05 + 24.05.93 not leaking at all cath removed bladder drill
- 02.06.93 not leaking at all, no incontinence, normal miction
 insp/ healed, poor elevation, no stress incontinence
- 04.07 + 05.09.93 idem
- 10.10.93 not leaking at all, no incontinence, normal miction healed, no stress

second obstetric fistula completely ok until PVIII (4 alive) live female in hosp

27.06.95 operation: UVVF-repair vuf 1067

- 11.07 + 25.07.95 not leakimng at all cath removed bladder drill
- 14.08.95 not leaking at all, no incontinence, normal miction
 insp/ healed, good elevation, no stress incontinence
- 04.09.95 idem
- 30.10.95 not leaking at all, no incontinence, normal miction healed, no stress



1 cm

KANO

cath 183

hhrg (kano)

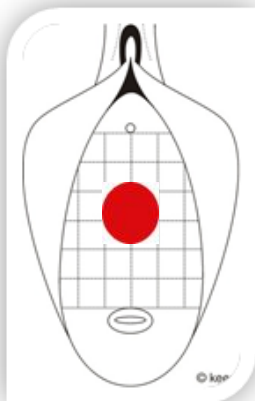
female 15 yr

27/04-93

diagnosis: PI, extensive \pm 2 cm 0 urethrovesicovaginal fistula **IIAb** with small circumferential defect, **leaking urine for 29 days which started 14 days** following obstructed labor for 3 days, in hospital live male infant, married 2 yr ago pre(menarche 5 mth later), not living with husband, no menstruation, drop foot L (grade 3), no RVF; EUO/F 2 cm, F/C 2 cm 155.0 cm

27/04-93 early closure anesthetic freshening, minimal dissection, transverse bladder/urethra closure by inverting chromic catgut starting with fixation of lateral bladder walls onto symphysis (contact anteriorly bladder/ urethra), transverse avw closure by everting chromic catgut and 3x supramid, FOLEY Ch 20; free urine flow, good bladder capacity (EUO/BW 11 cm), good elevation, EUO/B 3 cm

10.05 + 24.05.93 not leaking at all cath removed bladder drill
15/06-93 not leaking at all, no incontinence, normal miction
insp/ healed, good elevation, stress incontinence +



2 cm

hsmdg (kano)

female

40 yr

27/04-93

diagnosis: PVI (4 alive), one ± 1 cm 0 vesicovaginal fistula I midline bladder base and one CS fistula, **leaking urine for 14 days which started 13 days** (upon removal of catheter) following CS b.c.o. obstructed last labor for 2 days, stillborn male infant, married 27 yr ago pre(menarche 3 mth later), not living with husband, no menstruation, drop foot R (grade 4), no RVF EUO/F 7 cm, F/C? 4 cm 152.0 cm

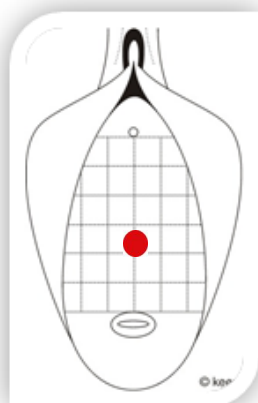
27/04-93 early closure

freshening, minimal dissection, scarring +++, longitudinal avw closure with everting chromic catgut and 3x supramid (the only thing possible), there is still leakage from cervix, FOLEY Ch 18; free urine flow, good bladder capacity (EUO/BW 12 cm), elevation?, EUO/B 4 cm anesthetic

24/05-93 leaking catheter removed insp/ **healed**

13/06-93 160 ml gv under spinal anesthesia

overflow incontinence, EUO/BW 17 cm, **no fistula, no leakage** clear urine from "cervix" **??ureter fistula??**



1 cm

mmgm (kano city)

female

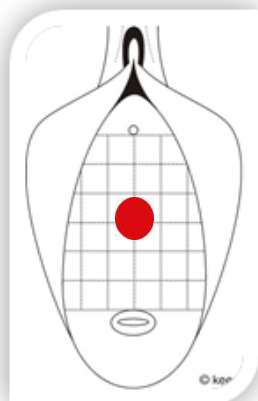
15 yr

27/04-93

diagnosis: PI, extensive \pm 1 cm 0 urethrovesicovaginal fistula **IIAa** at midline, **leaking urine for 2 mth** which started immediately following CS b.c.o. obstructed labor for 1 day (eclampsia), stillborn male infant, married 2 yr ago pre(menarche 3 mth later), not living with husband, no menstruation, no RVF, drop foot R (grade 3) and L (grade 3), moderate vagina s-tenosis/shortening
 EUO/F 2 cm, F/C 2 cm (mutilated cervix) 145.0 cm

27/04-93 **early closure** difficult
 freshening, minimal dissection, transverse bladder/urethra closure with in-verting chromic catgut, transverse avw closure with everting chromic catgut and 3x supramid, FOLEY Ch 18; free urine flow, moderate bladder capacity (EUO/BW 9 cm), good elevation, EUO/B 3 cm anesthetic

- 10.05 + 24.05.93 not leaking at all cath removed bladder drill
- 08.06.93 not leaking at all, no incontinence, normal miction healed, stress \pm
- 20.06.93 idem
- 03.08.93 not leaking at all, no incontinence, normal miction
 insp/ healed, good elevation, no stress incontinence
- 22.08.93 idem
- 10.10.93 not leaking at all, no incontinence, normal miction healed, no stress



1 cm

hidt (kano city) female 32 yr 12/04-93

diagnosis: PVII (3 alive), \pm 4 cm 0 necrotic urethrovesicovaginal fistula **IIAb** (circum defect?) at L bladder neck, **leaking urine for 15 days** which started immediately following obstructed last labor for 1 day, in hospital still born female infant, married 20 yr ago pre(menarche 1 yr later), still living with husband, no menstruation, drop foot R (grade 2) and L (grade 4), no RVF EUO/F 2 cm, F/C 6 cm 154.0 cm

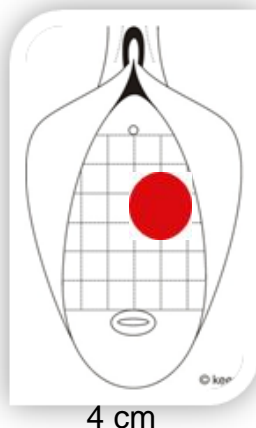
19/4-93 still necrosis

27/04-93 early closure "clean" \pm 4 cm 0 urethrovesicovaginal fistula with a circumferential defect (bladder even loose anteriorly) L bladder neck EUO/F 2 cm, F/C 6 cm
 freshening, minimal dissection, a dissection of bladder from L pubic bone, circumferential UVVF-repair by end-to-end vesicourethrostomy by single layer of inverting chromic catgut starting with fixation of anterior bladder wall to anterior urethra and L lateral bladder wall onto symphysis, transverse avw closure with everting chromic catgut and 5x supramid, FOLEY Ch 18; free urine flow, good bladder bladder capacity (EUO/BW 11 cm), elevation?, EUO/BW 2 cm anesthetic

1 cm fistula

14/06-93 operation: "urethra reconstruction" vvf 566

27.06.93 not leaking at all cath removed bladder drill
 04.07.93 not leaking, incontinence \pm , normal miction
 insp/ healed, poor elevation, stress incontinence +
 11.07 + 05.09.93 idem
 31.10.93 not leaking, incontinence \pm , normal miction healed, stress +



anrl (kano city)

female

16 yr

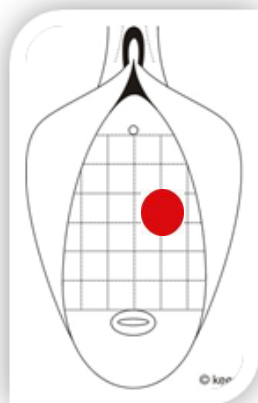
27/04-93

diagnosis: PI, \pm 2 cm 0 urethrovesicovaginal fistula **IIAb** with almost circumferential defect L bladder neck, **leaking urine for 31 days which started 5 days** (upon removal of catheter) following obstructed labor for 3 days, in hospital (eclampsia) stillborn male infant married 3 yr ago pre(menarche 3 mth later), not living with her husband, no menstruation, drop foot R (grade 4), no RVF
 EUO/F 3 cm, F/C 4 cm 156.5 cm

27/04-93 early closure

freshening, minimal dissection, dissection of bladder from L pubic bone, transverse bladder/urethra closure with a single layer of inverting chromic catgut starting with fixation of L bladder wall to symphysis (contact anteriorly bladder/urethra), transverse avw closure by everting chromic catgut/4x supramid, FOLEY Ch 18; free urine flow, good bladder capacity (EUO/B 12 cm), good elevation, EUO/B 2 cm anesthetic

- 10.05 + 24.05.93 not leaking at all cath removed bladder drill
- 08.06.93 not leaking at all, no incontinence, normal miction healed, stress +
- 20.06.93 idem
- 16.08.93 not leaking at all, no incontinence, normal miction insp/ healed, good elevation, no stress incontinence
- 19.09.93 not leaking at all, no incontinence, normal miction healed, no stress



2 cm

uag (kano)

female

15 yr

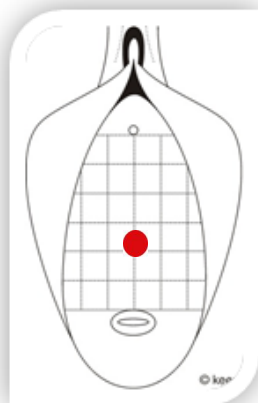
27/04-93

diagnosis: PI, \pm 1 cm 0 vesicovaginal fistula **IIAa** midline bladder neck, **leaking urine for 6 days which started 30 days** following obstructed labor for 3 days, in hospital (eclampsia) stillborn male infant married 2 yr ago pre(menarche 1 mth later), not living with husband, no menstruation, no h/o drop foot, no RVF
 EUO/F 4 cm, F/C 2 cm 157.0 cm

27/04-93 early closure

freshening, minimal dissection, transverse bladder closure with inverting chromic catgut, transverse avw closure with everting chromic catgut/3x supramid, FOLEY Ch 20; free urine flow, good bladder capacity (EUO/BW 13 cm), good elevation, EUO/B 4 cm anesthetic

- 10.05 + 24.05.93 not leaking at all cath removed bladder drill
- 08.06.93 not leaking at all, no incontinence, normal miction
 insp/ healed, good elevation, no stress incontinence
- 20.06 + 22.08.93 idem
- 17.10.93 not leaking at all, no incontinence, normal miction healed, no stress



1 cm

KANO

cath 189

aatb (kano city)

female

33 yr

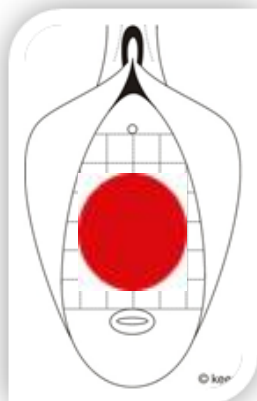
26/04-93

diagnosis: PV (0 alive), very extensive \pm 6 cm 0 necrotic urethrovesicovaginal fistula **IIAb, leaking for 18 days** which started immediately following obstructed last labor for 2 days, in hospital stillborn male infant, married 20 yr ago pre(menarche 4 mth later), not living with husband, no menstruation, no RVF, drop foot R (grade 2)
EUO/F 2 cm, F/C 1 cm 157.0 cm

26/4-93 FOLEY Ch 18; later for primary suturing

04/05-93 early closure now clean \pm 6 cm 0 urethrovesicovaginal fistula; **still necrosis lateral vagina walls**; EUO/F 2 cm, F/C 1 cm
leaking urine for 26 days
freshening, minimal dissection, transverse bladder/urethra closure with inverting chromic catgut, transverse avw closure with 4x everting supramid, FOLEY Ch 18; free urine flow, good bladder capacity (EUO/BW 10 cm), moderate elevation, EUO/B 2.5 cm anesthetic

17.05 + 08.06.93 not leaking at all cath removed bladder drill
13.06.93 not leaking at all, no incontinence, normal miction
insp/ healed, poor elevation, no stress incontinence
20.06 + 15.08.93 idem
10.10.93 not leaking at all, no incontinence, normal miction healed, no stress



6 cm

KANO

cath 190

documented 11.05 + 25.05 before/after + 20.06 + 04.07

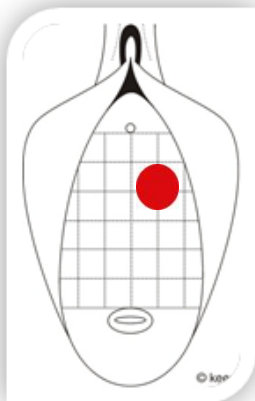
isrwd (kano) female 14 yr 10/05-93

diagnosis: PI, ± 2.5 cm 0 necrotic urethrovesicovaginal fistula **IIAb** midline/L bladder neck, **leaking urine for 15 days** which started immediately following obstructed labor for 2 days, in hospital (eclampsia) stillborn male infant, married 1 yr ago pre(menarche 3 mth later, she only menstruated 3x), not living with husband, no menstruation, drop foot R (grade 2) and L (grade 4), no RVF
EUO/F 2 cm, F/C 5 cm 147.0 cm

10/5-93 FOLEY Ch 18; later for early closure though it may heal spontaneously

25/05-93 early closure ± 2.5 cm 0 UVVF with small circum defect **leaking urine for 30 days**
freshening, sharp dissection of bladder from L pubic bone/symphysis, transverse bladder/symphysis/urethra closure (anterior adaptation) by inverting chromic catgut, FOLEY Ch 18, transverse avw closure by everting chromic catgut/4x supramid; free urine flow, EUO/BW 12 cm, good elevation, EUO/B 3 cm anesthetic
normal bladder capacity (longitudinal diameter 12-3 = 9 cm)

- 07.06 + 20.06.93 not leaking at all cath removed bladder drill
- 26.06.93 not leaking, incontinence \pm , normal miction healed, stress \pm
- 04.07.93 not leaking at all, no incontinence, normal miction
insp/ healed, good elevation, no stress incontinence
- 05.09.93 idem
- 25.10.93 not leaking at all, no incontinence, normal miction healed, no stress



2.5 cm

KANO

cath 191

documented 11.05 + 24.05 + 07.06 + 10.10

hmhf (kano city) female 14 yr 11/05-93

diagnosis: PI, overflow incontinence due to atonic bladder, \pm 3 cm 0 traumatized avw
IIBa, leaking urine for 6 days which started immediately following
craniotomy b.c.o. an obstructed labor for 3 days, in hospital (eclampsia)
stillborn male infant, married 1 yr ago post(menarche 2 mth earlier), not
living with husband, no menstruation, drop foot R (grade 4) and L (grade
3), no RVF
EUO/T 1 cm, T/C ?? cervix too far away 162.0 cm

11/05-93 FOLEY Ch 20, > 1 liter of urine; EUO/BW 20 cm!, good elevation, EUO/B
4 cm on cough urine \pm from EUO

24/05-93 now 2x1 cm **necrotic** avw

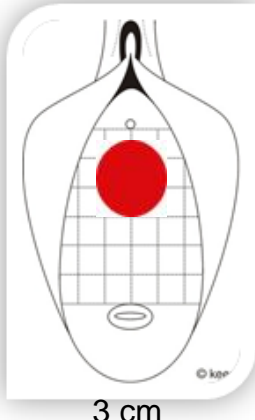
07/06-93 still **1 cm 0 avw defect**

 26.06.93 not leaking at all cath removed bladder drill

04.07.93 not leaking at all, no incontinence, normal miction
 insp/ healed, good elevation, no stress incontinence

 16.08 + 10.10.93 idem

21.11.93 not leaking at all, no incontinence, normal miction healed, no stress



KANO
documented 10.05 + 17.05 + 07.06

cath 192

saatb (kano city) female 15 yr 10/05-93

diagnosis: PI, \pm 1 cm 0 triangular necrotic vesicovaginal fistula R bladder neck **IIAa**,
leaking urine for 18 days which started immediately (therefore catheter
for 5 days) following vacuum extraction b. c.o. obstructed labor for 2 days,
live male infant, married 2 yr ago post(menarche 1 mth earlier), not living
with husband, no menstruation, no h/o drop foot, no RVF
EUO/F 4 cm, F/C 4 cm 166.5 cm

10/5-93 FOLEY Ch 18; later for early closure though it may heal spontaneously;
good bladder capacity (EUO/BW 10 cm), good elevation, EUO/B 4 cm

17/5-93 not leaking at all; insp/ almost healed, no longer VVF

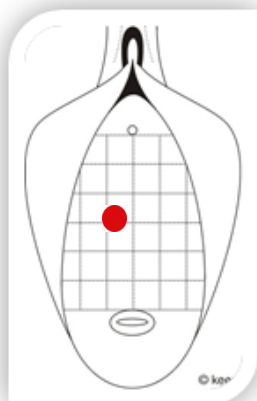
07.06.93 not leaking at all cath removed bladder drill

20.06.93 not leaking at all, no incontinence, normal miction

insp/ healed, good elevation, no stress incontinence

03.08 + 30.08.93 idem

25.10.93 not leaking at all, no incontinence, normal miction healed, no stress



1 cm

KANO
documented 17.05 + 13.06.93

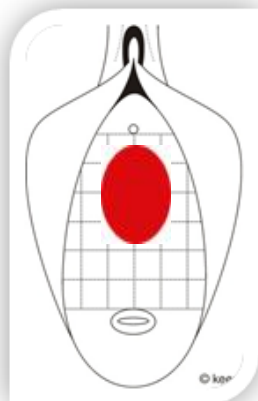cath 193

nmkb (kano city) female 18 yr 17/05-93

diagnosis: PI, urine stress incontinence with normal micturition, \pm 5x4 cm **IIBa** avw trauma urethra/bladder neck, **leaking when standing/walking for 5 days which started 2 days** following obstructed labor for 2 days, in hospital stillborn female, married 7 yr ago pre(menarche 2 yr later), not living with husband, no menstruation, no h/o drop foot, no RVF
EUO/T 1 cm, T/C 5 cm 160.0 cm

17/5-93 FOLEY Ch 18; bladder full, good bladder capacity (EUO/BW 12 cm) good elevation, EUO/B 2 cm

07.06 + 13.06.93 not leaking at all cath removed bladder drill
20.06.93 not leaking at all, no incontinence, normal miction
insp/ healed, good elevation, no stress incontinence
16.08.93 idem
17.10.93 not leaking at all, no incontinence, normal miction healed, no stress



5x4 cm

KANO
development of cystocele

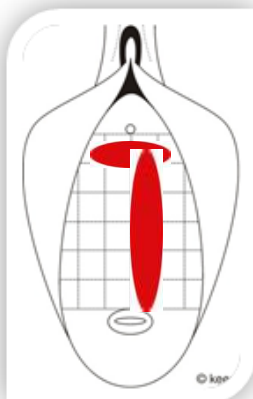
cath 194

aak (kano city) female 25 yr 17/05-93

diagnosis: PIV (1 alive), urine stress incontinence & normal micturition, \pm 4x9x1.5 cm T-like **deep** avw trauma **IIBa, leaking urine whilst standing/walking for 20 days which started 3 days** following obstructed last labor for 1 day, in hospital a stillborn male infant, married 15 yr ago pre(menarche 3 yr later), still living with husband, no menstruation, drop foot R (grade 3) and L (grade 3), no RVF
EUO/F 1 cm, F/C 0 cm 152.0 cm

17/5-93 FOLEY Ch 18; bladder full, good bladder capacity (EUO/BW 10 cm) good elevation, EUO/B 2 cm

08.06 + 13.06.93 not leaking at all cath removed bladder drill
20.06.93 not leaking at all, no incontinence, normal miction
insp/ healed, large cystocele, no stress incontinence
04.07 + 05.09.93 idem
10.10.93 not leaking at all, no incontinence, normal miction healed, no stress
large cystocele



KANO

cath 195

sadm (kano)

female

32 yr

03/05-93

diagnosis: PVI (5 alive), ± 2 cm 0 necrotic vesicovaginal fistula midline bladder base
I, leaking urine for 7 days which started 7 days following removal of
catheter for 14 days after CS b.c.o. obstructed last labor for 2 days,
stillborn male infant, married 20 yr ago pre(menarche 1 yr later), still living
with husband, no menstruation, drop foot R (grade 4), no RVF
EUO/F 8 cm, F/C? 0 cm 149.5 cm

03.05.93 FOLEY Ch 18; later for repair

10/5-93 still necrosis

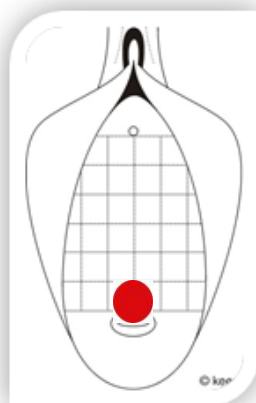
17/5-93 almost clean; for repair under spinal anesthesia tomorrow

18/05-93 difficult early closure (unsuccessful spinal) still 2 cm 0 fistula
freshening, extirpation of some necrosis, dissection, longitudinal bladder
closure by inverting chromic catgut, longitudinal avw closure by everting
chromic catgut/3x supramid, FOLEY Ch 18 free urine flow (no loin pain),
good bladder capacity (EUO/BW 10 cm), good elevation, EUO/B 4 cm
it looks more like CS-hysterectomy with cervix stump anesthetic

09.06 + 13.06.93 not leaking at all cath removed bladder drill

30.06.93 not leaking at all, no incontinence, normal miction
insp/ healed, good elevation, no stress incontinence

04.07.93 not leaking at all, no incontinence, normal miction healed,no stress



2 cm

documented 10.05 + 24.05 + 25.05 before/after + 20.06 + 04.07

riykm (kano city)

female

15 yr

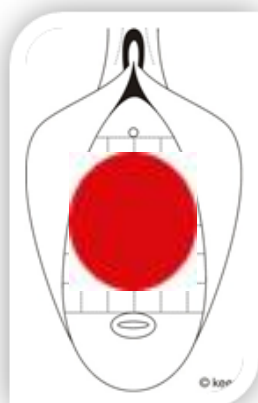
18/05-93

diagnosis: PI, extensive \pm 6 cm urethrovesicovaginal fistula **IIBb** with extensive circumferential defect, **leaking urine for 65 days** which started immediately following obstructed labor for 2 days, in hospital stillborn male infant, married 2 yr ago post(menarche 3 mth earlier), not living with husband, no menstruation, drop foot R (grade 3) and L (grade 3), also RVF, labia minora loss
 EUO/F 1 cm, F/C 1 cm 160.0 cm
 when seen 3/5 for the first time she had a catheter but the balloon was blown up inside the fistula and had torn almost the distal "urethra" off

18/05-93 early closure

still grossly damaged EUO, incision at fistula edge, sharp dissection of avw from bladder, sharp circumferential dissection of bladder from pubic bones/symphysis, advancement/distal fixation of anterior bladder onto symphysis, circumferential UVVF-"repair" by end-to-end vesicourethrostomy with a single layer of inverting chromic catgut starting with fixation of lateral bladder walls onto symphysis, transverse avw "closure" with everting chromic catgut and 4x supramid, FOLEY Ch 18, vagina pack; free urine flow, good bladder capacity (EUO/BW 12 cm), good elevation, EUO/B 2 cm doubtful/difficult anesthetic this pat felt slightly only the two lateral supramid sutures, otherwise this extensive early "closure" would not have been possible

- 15/08-93 leaking & miction insp/ healed, EUO drawn inside, stress ++
- 16/08-93 operation: RVF-repair rvf 70**
- 16/11-93 operation: urethra/avw reconstruction vvf 700**
- 24/01-94 UVVF + RVF
- 31/05-94 operation: UVVF-repair vvf 801**
- 14.06.94 not leaking at all cath removed bladder drill
- 18.06.94 not leaking at all, no incontinence, normal miction
 insp/ **both** healed, good elevation, no stress incontinence
- 03.07 + 31-07 + 02.10 + 23.01.95 idem
- 26/03-95 not leaking, incontinence \pm , normal miction
 insp/ healed, poor elevation, stress incontinence ++
- 15/07-97 leaking & normal miction **bladder drill** ba hanya
 insp/ EUO/BW 9 cm, EUO/B 3 cm, **no** leakage, stress +++



6 cm

asb (kano city) female 22 yr 23/05-93

diagnosis: PIII (1 alive), ± 6 cm 0 necrotic avw **IIAb** with seeping thru/stress incontinence, ± 3 cm 0 necrotic proximal pvw, **leaking urine and passing stools sometimes per vaginam for 11 days** which started immediately following obstructed last labor for 1 day, in hospital a stillborn male infant, married 10 yr ago pre(menarche 1 yr later), not living with husband, no menstruation yet, drop foot L (grade 2)
EUO/F 2 cm, F/C 3 cm, I/F 10 cm, F/C 0 cm 160.0 cm

23/5-93 FOLEY Ch 20; later for early closure, free urine flow (bladder not overfilled), good bladder capacity (EUO/BW 13 cm), moderate elevation, EUO/B 4 cm

08/06-93 stool o.k., still leaking; insp/ now necrotic fistula

14/06-93 clean fistula, but fever/diarrhea; next week ps

21/06-93 early closure clean 2 cm 0 UVVF with circumferential defect
EUO/F 2 cm, F/C 6 cm pvw completely healed

leaking urine for 40 days

incision at fistula edge, dissection of avw from bladder and minimally from urethra, circumferential dissection of bladder, advancement and distal fixation of anterior bladder wall onto symphysis, circumferential UVVF-repair by end-to-end vesicourethrostomy with inverting chromic catgut starting by fixation of lateral bladder walls onto symphysis, transverse avw closure by everting chromic catgut and 5x supramid, FOLEY Ch 20, vagina pack; flow of urine, good bladder capacity (EUO/BW 12 cm), good elevation, EUO/B 3 cm anesthetic pat felt only the most lateral avw sutures when "anesthetist" left and she was no longer spoken to; when anesthetist returned everything o.k.!!

06/09-93 leaking & normal miction

gv: healed, EUO/BW 7 cm, moderate elevation, EUO/B 1 cm
no leakage ?for lengthening urethroplasty?

30/11-93 operation (MMSH_Sa): bladder stone removal/urethra lengthening

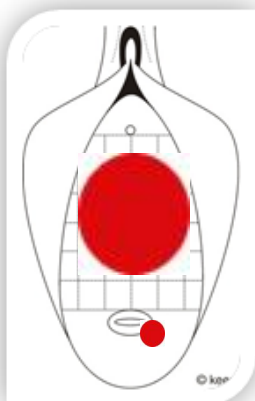
30/01-94 urethra breakdown

28/06-94 operation: urethra reconstruction vvf 823

17.07.94 not leaking at all cath removed bladder drill

07/03-95 not leaking at all, no incontinence, normal miction

insp/ healed, good elevation, no stress incontinence



6 cm

KANO
intrinsic incontinence

cath 198

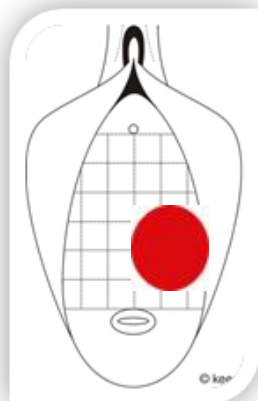
frdk (kano city) female 16 yr 24/05-93

diagnosis: PI, overflow incontinence due to atonic bladder, \pm 4 cm 0 avw traumatized/necrotic **IIAa** (will develop fistula?), **leaking urine for 3 days which started 2 days** following an obstructed labor for 1 day, in hospital stillborn male infant, married 3 yr ago pre(menarche 3 mth later), still living with husband, no menstruation, no h/o drop foot, no RVF
EUO/T 4 cm 151.0 cm

24/5-93 FOLEY Ch 18; bladder overfilled >1 liter (EUO/BW 15 cm), moderate elevation, EUO/B 4 cm; later for good inspection

14/06-93 early closure 1 cm 0 fistula L
freatening, dissection, transverse bladder/urethra closure by inverting chromic catgut, FOLEY Ch 18, transverse avw closure by 3x everting supamid, pack; a free urine flow, EUO/BW 12 cm, good elevation, EUO/B 4 cm very difficult; poor accessibility anesthetic
normal bladder capacity (longitudinal diameter 12-4 = 8 cm)

26.06. + 11.07.93 not leaking at all cath removed bladder drill
27.07.93 not leaking at all, no incontinence, normal miction
insp/ healed, good elevation, no stress incontinence
23.08 + 17.10.93 idem
21.11.93 not leaking at all, no incontinence, normal miction healed, no stress



4 cm

**KANO
documented 25.05 before/after + 20.06**

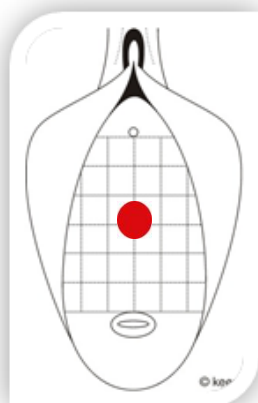
cath 199

ttmu (kano city) female 31 yr 25/05-93

diagnosis: PVI (3 alive), \pm 1.5 cm 0 vesicovaginal fistula midline bladder neck **IIAa**,
leaking urine for 41 days which started 6 days following obstructed
 last labor for 2 days, in hospital stillborn female infant, married 20 yr
 pre(menarche 2 yr later), still living with husband, no menstruation, drop
 foot L (grade 2) no RVF
 EUO/F 4 cm, F/C 5 cm 154.0 cm

25/05-93 freshening, dissection, scar tissue ++, transverse bladder/urethra closure
 by inverting chromic catgut, transverse avw closure with evertting chromic
 catgut/4x supramid, FOLEY Ch 20; free urine flow, good bladder capacity
 (EUO/BW 11 cm), good elevation, EUO/B 4 cm anesthetic

- 07.06 + 20.06.93 not leaking at all cath removed bladder drill
- 26.06.93 not leaking, incontinence ++, normal miction
 insp/ healed, good elevation, no stress incontinence
- 04.07 + 23.08 + 17.10.93 idem vaginal discharge
- 21/11-93 not leaking at all, no incontinence, normal miction
 insp/ healed, good elevation, no stress incontinence



1.5 cm

KANO

cath 200

documented 10.05 + 24.05 + 25.05 before/after + 20.06 + 04.07.93

hsg (kano) female 15 yr 10/05-93

diagnosis: PI, 4x2 cm necrotic urethrovesicovaginal fistula midline bladder neck **IIAa**,
rectovaginal fistula with sphincter ani rupture, **leaking urine/passing stools pv for 8 days** which started immediately following obstructed labor for 2 days, in hospital stillborn male infant, married 1 yr ago post(men arche 10 mth earlier), not living with husband, no menstruation, drop foot R (grade 2) and L (grade 4), partial pubococcygeus loss
EUO/F 3 cm, F/C 5 cm 152.5 cm

10/5-93 FOLEY Ch 20; later for early closure

17/5-93 not yet clean

24/5-93 balloon in fistula, catheter removed

25/5-93 clean \pm 3 cm 0 urethrovesicovaginal fistula midline; still some necrosis lateral vagina walls; EUO/F 2.5 cm, F/C 6 cm anesthetic
leaking urine for 23 days
freshening, dissection (vagina wall very thin), transverse bladder/ure thra closure by inverting chromic catgut, transverse avw closure with everting chromic catgut and 5x supramid, FOLEY Ch 20; free urine flow, good bladder capacity (EUO/BW 14 cm), good elevation, EUO/B 4 cm

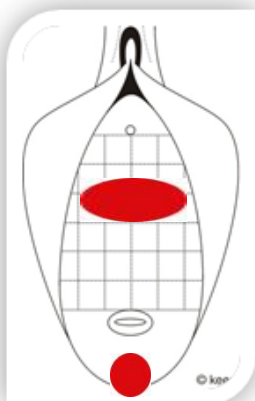
20.06.93 not leaking at all cath removed bladder drill

26.06.93 not leaking at all, no incontinence, normal miction
insp/ healed, good elevation, no stress incontinence

04.07 + 05.09.93 not leaking at all, normal miction healed, no stress

13/09-93 operation: rectum/sphincter ani repair rvf 75

27/02-94 not leaking at all, normal miction, stools ok **both** healed, no stress



4x2 cm

sdig (kano) female 14 yr 25/05-93

diagnosis: PI, extensive \pm 5 cm 0 urethrovesicovaginal fistula **IIAb** with extensive circumferential defect, proximal rectovaginal fistula, **leaking/passing stools pv for 64 days which started 3 days** following obstructed labor for 3 days, at home stillborn female infant, married 3 yr ago pre(menarche 1.5 yr later), not living with husband, no menstruation, patient cannot walk/stand (only crawl), drop foot R (grade 0) and L (grade 2)
EUO/F 1.5 cm, F/C 4 cm 140.0 cm

25/05-93 freshening, dissection of avw from bladder and minimally from urethra, circumferential sharp dissection of bladder from pubic bones/symphysis/abdominal wall, advancement and distal fixation of anterior bladder wall onto the symphysis, a circumferential UVVF-repair by end-to-end vesicourethrostomy by a single layer of inverting chromic catgut, transverse avw closure by everting chromic catgut and 5x supramid, FOLEY Ch 20, vagina pack; free urine flow, good bladder capacity (EUO/BW 11 cm), good elevation, EUO/B 3 cm anesthetic
No pain whatsoever

06/09-93 gv: **multiple residual small fistulas**

18/10-93 operation: lungu UVVF-repair 2x vvf 665

01.11 + 13.11.93 not leaking at all cath removed bladder drill

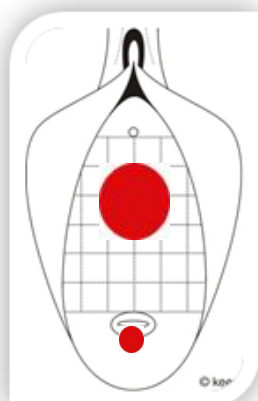
21.11 + 09.01.94 not leaking at all, no incontinence, miction healed, stress \pm

14/03-94 not leaking, no incontinence, normal miction **still stools pv**

insp/ healed, good elevation, stress incontinence \pm **RVF**

24/05-94 operation: RVF-repair rvf 103

14/08-94 stools ok/not leaking at all, normal miction **both** healed, no stress



5 cm

highly interesting _ study this patient very carefully

biu (kano city) female 16 yr 06/06-93

diagnosis: PII (1 alive), stress incontinence II (it does not seem to be overflow incontinence due to atonic bladder; only 100 ml urine inside bladder), **leaking only when standing/walking with normal micturition for 21 days** which started 3 days following obstructed last labor for 3 days, in hospital stillborn female infant, married 4 yr ago pre(menarche 1 yr later), not living with husband (divorced already before labor), no menstruation, no h/o drop foot, no RVF; \pm 1 cm 0 avw defect midline bladder base on cough definite stress incontinence ++++
EUO/AVWT 7 cm, AVWT/C 2 cm 158.0 cm

06/06-93 FOLEY Ch 18; free urine flow, good bladder capacity (EUO/BW 14 cm), moderate elevation, EUO/B 3 cm

20.06 + 04.07.93 not leaking at all cath removed bladder drill
12.07.93 not leaking at all, no incontinence, normal miction
insp/ healed, good elevation, no stress incontinence
16.08 + 03.10.93 idem
28.11.93 not leaking at all, no incontinence, normal miction healed, no stress

new leaking started to leak following lower abdominal mass 1 yr after last delivery for 2 days, at home live male **PVII (5 alive)**

bubru old card still with her

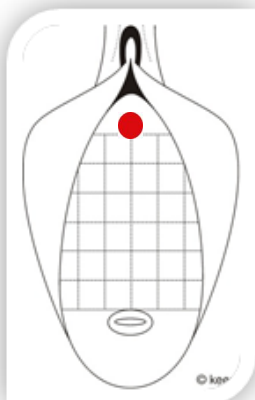
16.01.07 urethralization (mmsh_ka): VVF-repair

25.06.07 leaking insp/ healed, moderate elevation, stress incontinence ++
EUO/BW 14 cm (rough bladder surface_trabecularization), EUO/B 2 cm

strange new obstetric leakage after abd mass PVII (5 alive)

25.06.07: long-standing atonic bladder cath 807

02.09.07 not leaking at all cath removed bladder drill
23.09.07 leaking **bladder drill**



fyg (kano)

female

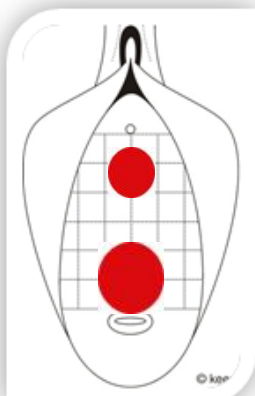
20 yr

25/05-93

diagnosis: PIV (2 alive), \pm 3 cm 0 necrotic urethrovesicovaginal fistula **IIAa** and 4 cm 0 necrotic avw at vault, **leaking urine for 23 days** which started immediately (upon removal of catheter x 12 days) following CS-laparotomy b.c.o. ruptured uterus b.c.o. obstructed last labor for 1 day, stillborn male infant, married 8 yr ago pre(menarche 1 yr later), not living with husband, no menstruation, bilateral drop foot (R grade 1-2 and L grade 1-2), no RVF, malnutrition + poor generalcondition
 EUO/F 2 cm, F/NAVW 4 cm 150.0 cm

07/06-93 now 2.5 cm 0 urethrovesicovaginal fistula with necrosis \pm at R; the necrotic avw has healed without fistula; general condition not fit for spinal freshening, extirpation of some necrotic tissue, minimal dissection, transverse bladder/urethra closure by inverting chromic catgut, transverse avw closure with everting chromic catgut/ 5x supramid, FOLEY Ch 18, pack; free urine flow, moderate bladder capacity (EUO/BW 7 cm), moderate elevation, EUO/B 4 cm anesthetic

20.06 + 04.07.93 not leaking at all cath removed bladder drill
 11.07.93 not leaking, incontinence \pm , normal miction healed, no stress
 15.08.93 idem
 10.10.93 not leaking at all, no incontinec, normal miction condition good
 insp/ healed, good elevation, no stress incontinence
 21.11.93 not leaking at all, no incontinence, normal miction healed, no stress



multiple trauma

KANO
documented 7.06.93 before/after

cath 204

mjakkb (kano)

female 15 yr

07/06-93

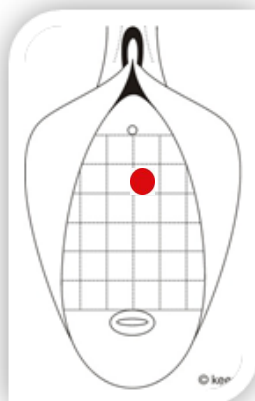
diagnosis: PI, \pm 1 cm 0 urethrovesicovaginal fistula L bladder neck **IIAa, leaking urine for 22 days which started 5 days** following obstructed labor for 3 days, in hospital stillborn female infant, married 1 yr ago post(menarche 7 mth earlier), still living with husband, no menstruation, drop foot R (grade 1), no RVF

EUO/F 2 cm, F/C 6 cm

152.0 cm

07/06-93 freshening, dissection, transverse bladder/urethra closure with inverting chromic catgut, transverse avw closure with everting chromic catgut and 4x supramid, FOLEY Ch 18, pack; free urine flow, good bladder capacity (EUO/BW 10 cm), good elevation, EUO/B 4 cm anesthetic

20.06 + 04.07.93 not leaking at all cath removed bladder drill
19.07.93 not leaking, incontinence \pm , normal miction healed, no stress
09.08 + 23.08.93 idem
19.09.93 not leaking at all, no incontinence, normal miction
insp/ healed, good elevation, no stress incontinence
28.11.93 not leaking at all, no incontinence, normal miction healed, no stress



1 cm

hrbr (kano city)

female

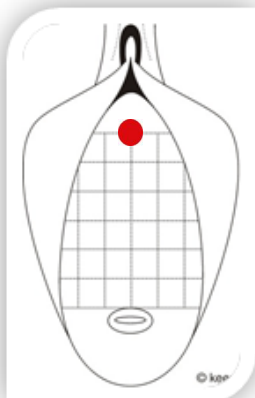
15 yr

13/06-93

diagnosis: PI, overflow incontinence due to UV-stricture, transverse scar over UV-junction (healed UVVF), **leaking urine for 60 days** which started 4 days following obstructed labor for 3 days, at home stillborn male infant, married 2.5 yr ago pre(menarche 6 mth later), not living with husband, no menstruation, drop foot R for 1 mth (now grade 5), no RVF
EUO/S 3 cm, S/C 8 cm 154.0 cm

13/06-93 gentle dilatation from H3 thru H10, insertion of FOLEY Ch 20; free urine flow, bladder overdistended (EUO/BW 15 cm, >1 liter of urine), good elevation, EUO/B 3 cm gv: no leakage

26.06 + 11.07.93 not leaking at all cath removed bladder drill
03/08-93 not leaking at all, no incontinence, normal miction



KANO
documented 13.06 + 21.06 before/after

cath 206

saskh (kano city) female 15 yr 13/06-93

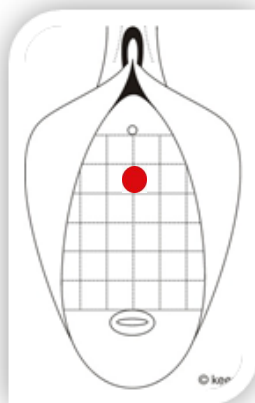
diagnosis: PI, \pm 1 cm 0 necrotic urethrovesicovaginal fistula **IIAa** at midline, **leaking urine for 9 days which started 3 days** following an obstructed labor for 2 days, in hospital (eclampsia) a stillborn female infant, married 2.5 yr ago pre(menarche 1 yr later), not living with husband, no menstruation, no h/o drop foot, no RVF
EUO/F 2 cm, F/C 6 cm 155.0 cm

13/6-93 FOLEY Ch 20; later for early closure

21/6-93 clean 1 cm 0 UVVF
freshening, dissection, transverse bladder/urethra closure with inverting chromic catgut, transverse avw closure with everting chromic catgut and 3x supramid, FOLEY Ch 20, pack; free urine flow, good bladder capacity (EUO/BW 13 cm), good elevation, EWUO/B 3 cm anesthetic
no pain whatsoever

05.07 + 20.07.93 not leaking at all cath removed bladder drill
27.07.93 not leaking at all, no incontinence, normal miction
insp/ healed, good elevation, no stress incontinence

05.09 + 31.10.93 idem
28.11.93 not leaking at all, no incontinence, normal miction healed, no stress



1 cm

kir (kano city) female 16 yr 10/05-93

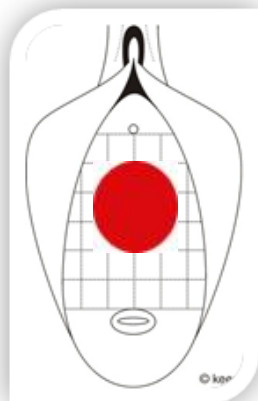
diagnosis: PI, very extensive necrotic UVVF at bladder neck/base **IIAb, leaking urine for 4 days** which started 4 days following obstructed labor for 3 days, at home stillborn female infant, married 4 yr ago pre(menarche 1 yr later), not living with husband, no menstruation, drop foot R (grade 0) and L (grade 0), no RVF??, pat cannot stand/walk, but only crawl
EUO/F 2 cm, F/C 4 cm

7/6-93 almost clean UVVF; FOLEY Ch 18

14/6-93 "clean" ± 6 cm 0 urethrovesicovaginal fistula with an extensive circumferential defect, pubococcygeus loss, bed sores, pat can still not stand or walk, **leaking urine for 39 days**
EUO/F 2 cm, F/C 4 cm 146.0 cm
freshening, dissection of avw from bladder and minimally from urethra, then sharp circumferential dissection of bladder from avw/pubic bones/symphysis, advancement and distal fixation of anterior bladder wall onto the symphysis circumferential UVVF-repair by end-to-end vesicourethroostomy with a single layer of inverting chromic catgut, transverse avw closure with 6x everting supramid (left open further for drainage), FOLEY Ch 20 and pack; free urine flow, moderate bladder capacity (EUO/BW 9 cm), good elevation, EUO/B 4 cm pat did not feel anything anesthetic

11/07-93 catheter out x 3 days leaking ±
insp/ seems healed

26/09-93 leaking insp/ **breakdown + RVF** pat "walks" with stick



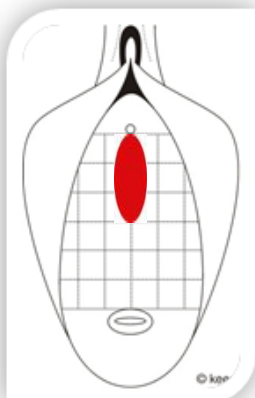
6 cm

lbb (kano city) female 15 yr 15/06-93

diagnosis: PI, overflow incontinence due to bladder atony, **leaking urine for 21 days** which started immediately following obstructed labor for 2 days, in hospital stillborn female infant, married 2.5 yr ago pre(menarche 2 mth later), still living with husband no menstruation, no h/o drop foot, no RVF longitudinal avw trauma type **IIBa** 151.0 cm

15/06-93 bladder overdistended (bulging into vagina, suprapubic mass), EUO/ BW 17 cm, >1.5 liter, EUO/B 3 cm, no elevation, FOLEY Ch 18

26.06 + 11.07.93 not leaking at all cath removed bladder drill
03/08-93 not leaking at all, no incontinence, normal miction
insp/ healed, moderate elevation, no stress incontinence



bak (kano city) female 14 yr 21/06-93

diagnosis: PI, very extensive \pm 2 cm 0 urethrovesicovaginal fistula **IIAb** with circumferential defect, leaking urine for 3 mth which started immediately following obstructed labor for 4 days, in hospital (eclampsia) stillborn male infant, married 1 yr ago post(menarche 2 mth earlier), not living with husband, no menstruation, drop foot R (grade 1) and L (grade 2), no RVF, patient can only "stand/walk" with stick, cervix displaced to L, slight vagina stenosis with moderate shortening
EUO/F 2 cm, F/C 1 cm 144.0 cm

21/06-93 freshening, dissection of avw from bladder and minimally from urethra, circumferential dissection of bladder from avw/cervix/pubis/symphysis/abdominal wall, advancement and distal fixation of anterior bladder wall to symphysis, circumferential UVVF-repair by an end-to-end vesico urethrostomy, transverse avw closure by everting chromic catgut/supramid, FOLEY Ch 20, pack; free urine flow, moderate bladder capacity (EUO/BW 9 cm), good elevation, EUO/B 3 cm anesthetic
slight pain at avw closure

06/09-93 dilatation & FOLEY Ch 18

0.3 cm fistula

18/01-94 operation: UVVF-"repair" vvf 725

01.02.94 not leaking at all cath removed bladder still

07/03-94 leaking & normal miction **bladder drill**

insp_gv: healed, no leakage, stress incontinence ++

second obstetric fistula completely ok until PII (1 alive) live female in hospital

16.11.98 operation: UVVF-repair/suspension VVF 1798

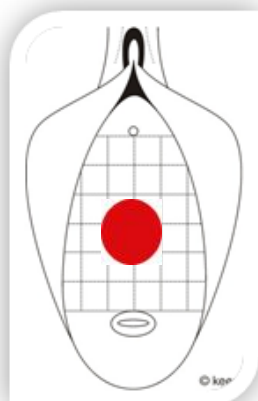
08.02.99 leaking & miction insp/ euo drawn inside, stress ++

third obstetric fistula ok until PIII (1 alive) sb female at home

01.06.09 operation: UVVF-repair + pcf refixation VVF 4310

09.07 + 30.08 not leaking, incontinence +, miction healed, stress +

25.10 + 27.12 + 04.04.10 total incontinence healed, incontinence ++



2 cm

thmf (katsina) female 15 yr 14/06-93

diagnosis: PI, urine stress incontinence with avw trauma (no necrosis) at L bladder neck, **leaking urine for 23 days** which started immediately following CS b.c.o. obstructed last labor for 3 days, in hospital a live male infant, married 1.5 yr ago post(menarche 3 mth earlier), not living with husband, no menstruation, no RVF, drop foot L (grade 3)
EUO/T 4 cm, cervix not identified (CS) 149.0 cm

14/06-93 FOLEY Ch 18; later for gv testing

28/6-93 catheter out for 2 days; incontinence +, normal micturition?
gv: no leakage, good elevation, EUO/BW 10 cm, EUO/B 4 cm; FOLEY Ch 18 for another 2 wk

11.07.93 leaking? cath removed bladder drill

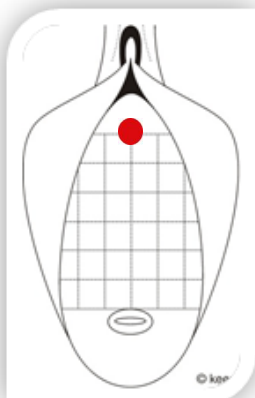
01.11.93 leaking insp_gv/ bladder stone

02/11-93 operation: cystostomy/stone removal vvf 687

15.12.93 wound healed, not leaking at all cath removed bladder drill

22.12.93 not leaking at all, no incontinence, normal miction
insp/ healed, good elevation, no stress incontinence

29.05.94 not leaking at all, no incontinence, normal miction healed, no stress



rabd (kano city)

female

15 yr

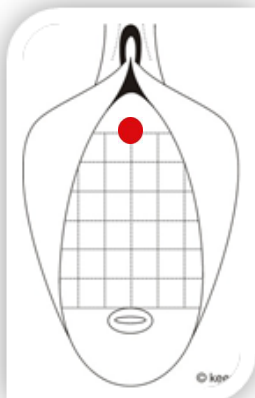
14/06-93

diagnosis: PI, urine stress incontinence, **leaking on/off for 17 days** which started immediately following obstructed labor for 3 days, some times not leaking at all, in hospital (eclampsia!) live female infant, married 1.5 yr ago post(menarche 6 mth earlier), still living with husband, no RVF no menstruation, drop foot R (grade 4) and L (grade 4), no fistula seen
EUO/BW 10 cm, moderate elevation, EUO/B 4 cm 155.0 cm

14/06-93 FOLEY Ch 18; later for gv testing

28/6-93 gv: no leakage; leave catheter for another 2 wk

13.07.93 not leaking at all cath removed bladder drill
16.08.93 not leaking at all, no incontinenec, normal miction
insp/ healed, moderate elevation, no stress incontinence
17.10.93 not leaking at all, no incontinence, normal miction healed, no stress



ryktm (kano city)

female 39 yr

29/05-93

diagnosis: PIX (7 alive), ± 2x1 cm necrotic CS vesicocervicovaginal I fistula, **leaking urine for 14 days** which started immediately following CS b.c.o. obstructed last labor for 3 days, live female infant, married 25 yr post(menarche 6 mth earlier), still living with husband, no menstruation, no h/o drop foot, no RVF
EUO/F 8 cm, F/C 0 cm 160.0 cm

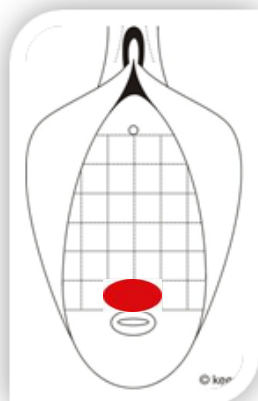
29/5-93 FOLEY Ch 18; later for gv

08/06-93 almost clean

28/6-93 clean; gv: seeping thru; for operation tomorrow

29/6-93 spinal L3/L4 with 4 ml bupivacaine 0.5%
bladder healed, avw still open, 80 ml gv: no longer leakage; pat could pass urine herself this morning
N.B. clear urine in vaginae from R ureter fistula inside R lateral cervix!!
too early for operation; FOLEY Ch 18, good bladder capacity (EUO/ BW 10 cm), no elevation (cystocele), EUO/B 2 cm

31/10-93 not leaking at all, no incontinence, normal miction
insp/ healed, poor elevation, no stress incontinence
no urine in vaginae so **no** ureter fistula



2x1 cm

msr (jigawa)

female

15 yr

05/07-93

diagnosis: PI, ± 5 mm 0 vesicovaginal fistula I midline bladder neck, **leaking urine for 25 days which started 7 days** following obstructed labor for 2 days, in hospital stillborn female infant, married 3 yr ago pre(menarche 7 mth later), not living with husband, no h/o drop foot, no menstruation, no RVF EUO/F 5 cm, F/C 2 cm 138.5 cm

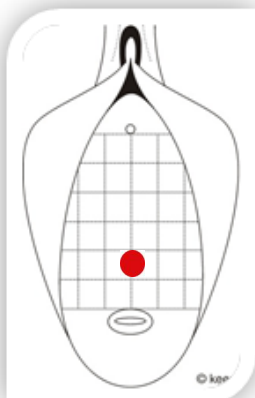
05/07-93 freshening, dissection, transverse bladder closure by inverting chromic catgut, transverse avw closure by everting chromic catgut and 3x supramid FOLEY Ch 18, vagina pack; free urine flow, good bladder capacity (EUO/BW 10 cm), no elevation, EUO/B 3 cm anesthetic

02.08.93 not leaking at all cath removed bladder drill

09.08.93 not leaking at all, no incontinence, normal miction insp/ healed, poor elevation, no stress incontinence

19.09.93 idem

09.01.94 not leaking at all, no incontinence, normal miction healed, no stress



0.5 cm

KANO
intrinsic incontinence

cath 214

hag (jigawa) female 16 yr 28/06-93

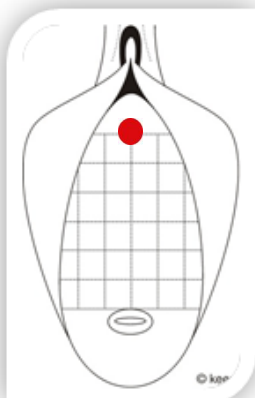
diagnosis: PI, ?? **leaking urine for 35 days** which started immediately following obstructd labor for 3 days, in hospital SB male infant, married 3 yr ago pre(menarche 4 mth later), still living with her husband, no menstruation, no RVF, drop foot R (grade 4) and L (grade 3-4) 164.0 cm

28/06-93 no fistula seen, bladder empty, good bladder capacity (EUO/BW 11 cm), good elevation, EUO/B 4 cm FOLEY Ch 18 for 4 wk

05/07-93 not leaking at all, 60 ml gv + cough: no leakage/no spilling

02/08-93 catheter fell out today, not leaking at all bladder drill

16/08-93 not leaking at all, no incontinence, normal micturition insp/ no (stress) incontinence



rsk (kano city)

female

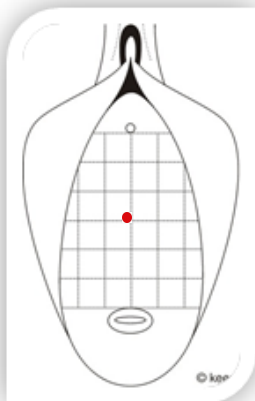
15 yr

19/07-93

diagnosis: PI, ± 3 mm 0 vesicovaginal fistula **IIAa** midline bladder neck, **leaking urine for 8 days that started 33 days** following obstructed labor for 1 day, in hospital SB female, married 14 mth ago post (menarche 5 mth earlier), still living with her husband, no RVF no menstruation, no h/o drop foot
 EUO/F 5 cm, F/C 5 cm 149.0 cm

FOLEY Ch 18; free flow of urine, good bladder capacity (EUO/BW 11 cm), good elevation, EUO/B 4 cm it may heal spontaneously

- 16.08 + 30.08.92 cath out x 3/7 not leaking at all, no incontinence, miction
 Insp/ healed, good elevation, no stress incontinence
- 05/09-93 not leaking, no incontinence, normal miction
 insp/ healed, good elevation, no stress
- 29/09-93 started to leak again after sex fistula
- 19/10-93 primary suturing**
 transverse incision through fistula, dissection, scarring +++, transverse bladder closure by 1x inverting chromic catgut, avw transverse closure by 3x everting supramid, FOLEY Ch 18, pack; free urine flow, EUO/ BW 11 cm, good elevation, EUO/B 4 cm anesthetic
 normal bladder capacity (longitudinal diameter 11-4 = 7 cm)
- 01.11 + 13.11.93 not leaking at all cath removed bladder drill
- 24.11.93 not leaking at all, no incontinence, normal miction
 insp/ healed, good elevation, no stress incontinence
- 28.11.93 idem
- 09.01.94 not leaking at all, no incontinence, normal miction healed, no stress



0.3 cm

KANO

cath 216

mmak (kano city)

female

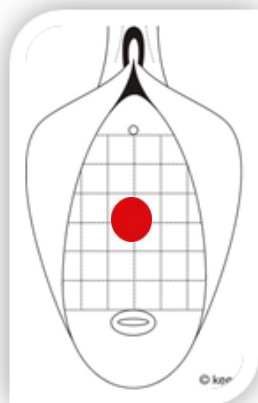
14 yr

19/07-93

diagnosis: PI, ± 2 cm 0 necrotic urethrovesicovaginal fistula at midline bladder neck
IIAa, leaking urine for 6 days which started immediately following obstructed labor for 2 days, in hospital SB male, married 1 yr ago pre(menarche 1 mth later), not living with her husband, no menstruation, pain both legs (both grade 5), no RVF
 EUO/F 4 cm, F/C 4 cm 152.0 cm

19/7-93 FOLEY Ch 18; later for primary suturing, free urine flow, good bladder capacity (EUO/BW 12 cm), good elevation, EUO/B 4 cm

02.08 + 30.08.93 not leakinh at all cath removed bladder drill
 05.09.93 not leaking at all, no incontinence, normal miction
 insp/ healed, good elevation, no stress incontinence
 03.10 + 21.11 + 17.01.94 idem
 27.02.94 not leaking at all, no incontinence, normal miction healed, no stress



2 cm

zir (kano city)

female

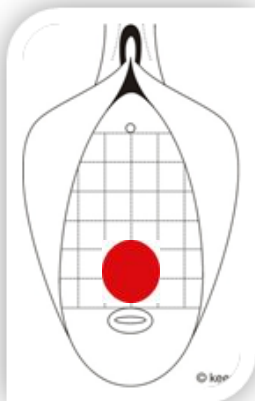
39 yr

29/07-93

diagnosis: PVIII (4 alive), overflow incontinence due to atonic bladder, **leaking urine for 18 days** which started immediately following craniotomy b.c.o. obstructed last labor for 2 days, SB female/ male twins, married 28 yr ago pre(menarche 2 yr later), still living with husband, no menstruation, drop foot R (grade 0) and L (grade 4), necrotic pvw but no RVF; 4 cm 0 traumatized avw at bladder base type I; pat cannot stand/walk
 EUO/AVWT 6 cm, AVWT/C 0 cm 152.0 cm

29/7-93 suprapubic mass, avw bulging into vagina, bladder overdistended (EUO/BW 17 cm), EUO/B 4 cm, >1 liter of urine FOLEY Ch 18

16.08 + 30.08,93 "walks" with stick not leaking at all cath removed drill
 05.09.93 not leaking at all, no incontinence, normal miction
 insp/ healed, moderate elevation, no stress incontinence
 19.09.93 idem
 25.10.93 not leaking at all, no incontinence, normal miction healed, no stress
 pat walks "ok" without support



4 cm

KANO

cath 218

mrd (kano city)

female

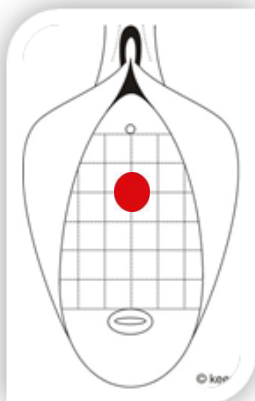
14 yr

02/08-93

diagnosis: PI, \pm 2 cm 0 **necrotic** urethrovesicovaginal fistula at midline bladder neck **IIAa, leaking urine for 15 days** which started immediately following obstructed labor for 1 day, in hospital a live male infant, married 1 yr ago post(menarche 1 mth earlier), not living with husband, no menstruation, drop foot R (grade 2) and L (grade 4), no RVF
EUO/F 3 cm, F/C 6 cm 154.0 cm

02/08-93 FOLEY Ch 18, later for primary suturing; free urine flow, good bladder capacity (EUO/BW 13 cm), good elevation, EUO/B 4 cm

16.08 + 05.09.93 not leaking at all cath removed bladder drill
12.09.93 not leaking at all, no incontinence, normal miction
insp/ healed, good elevation, no stress incontinence
10.10 + 21.11.93 idem
27.02.94 not leaking at all, no incontinence, normal miction healed, no stress



2 cm

hssk (kano city)

female

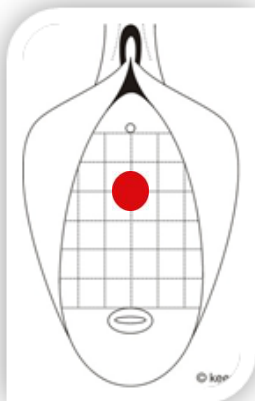
26 yr

02/08-93

diagnosis: PVI (5 alive), overflow incontinence due to an atonic bladder, **leaking urine for 20 days which started 3 days** following last obstructed labor for 1 day, in hospital SB male, married 13 yr ago pre(menarche 1 mth later), still living with her husband, no menstruation, no h/o drop foot, no RVF; 2 cm 0 traumatized avw type **IIAa** over bladder neck
 EUO/AVWT 3 cm, AVWT/C 6 cm 153.0 cm

02/08-93 suprapubic mass, avw bulging into vagina, bladder overdistended (EUO/BW 17 cm), EUO/B 3 cm, >1 liter urine FOLEY Ch 18

16.08 + 06.09.93 not leaking at all cath removed bladder drill
 19.09.93 not leaking, incontinence \pm , normal miction bladder drill
 29.09.93 not leaking at all, no incontinence, normal miction
 insp/ healed, moderate elevation, no stress incontinence
 31.10.93 idem
 28.11.93 not leaking at all, noincontinence, normal miction healed, no stress



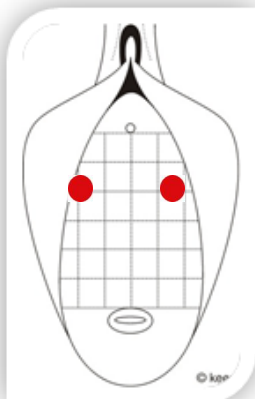
2 cm

Img (jigawa) female 16 yr 16/08-93

diagnosis: PI, overflow incontinence due atonic bladder in healing phase, **leaking urine for 30 days** which started immediately following an obstructed labor for 2 days, at home SB male infant, married 3 yr ago pre(menarche 4 mth later), not living with husband, no menstruation, no RVF, drop foot R (grade 4); granulations R & L bladder neck type **IIAa**
EUO/G 3 cm 144.5 cm

16/8-93 suprapubic mass, avw bulging into vagina, bladder overdistended (EUO/BW 16 cm), EUO/B 3 cm, >1 liter urine FOLEY Ch 18

05.09 + 20.09.93 not leaking at all cath removed bladder drill
26.09.93 not leaking at all, no incontinence, normal miction
insp/ healed, good elevation, no stress incontinence
25.10.93 idem
28.11.93 not leaking at all, no incontinence, normal miction healed, no stress



granulations

hyhk (kano)

female

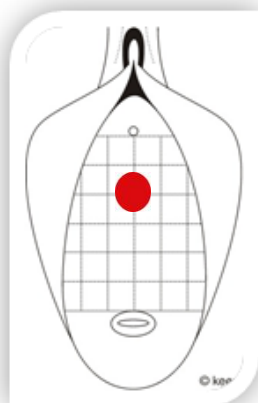
15 yr

17/08-93

diagnosis: PI, \pm 1.5 cm 0 urethrovesicovaginal fistula **IIAb** with small circumferential defect, **leaking urine for 26 days which started 3 day** following obstructed labor for 3 days, in hospital SB male infant, married 2 yr ago pre(men arche 2 mth later), not living with husband, no menstruation, no RVF drop foot R (grade 4) and L (grade 3-4); pat still needs support whilst walking EUO/F 2 cm, F/C 5 cm 145.0 cm

17/08-93 freshening, minimal dissection, transverse bladder/urethra closure by inverting chromic catgut (also adaptation anteriorly?), transverse avw closure by everting chromic catgut/4x supramid, FOLEY Ch 20, pack; free flow of urine, good bladder capacity (EUO/BW 13 cm), good elevation, EUO/B 3 cm no pain whatsoever anesthetic

- 05.93 + 19.09.93 incontinence walks ok cath removed bladder drill
- 26.09.93 not leaking, incontinence \pm , normal miction walks normally (no support) insp/ healed, good elevation, stress incontinence \pm
- 13.11.94 idem
- 09.01.94 not leaking at all, no incontinence, normal miction insp/ healed, good elevation, no stress incontinence
- 20.02.94 not leaking at all, no incontinence, normal miction healed, stress ++



1.5 cm

asb (kano)

female

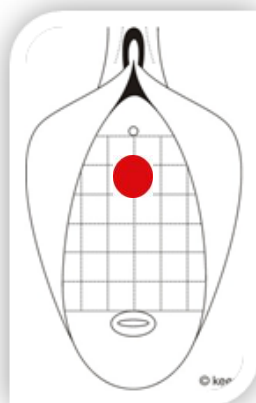
15 yr

17/08-93

diagnosis: PI, \pm 2 cm 0 urethrovesicovaginal fistula with circumferential defect **IIAb**, **leaking urine for 41 days** which started immediately following obstructed labor for 3 days, in hospital SB male infant, married 2 yr ago post(men arche 3 mth earlier), not living with husband, no menstruation, drop foot R (grade 2) and L (grade 4) no RVF, eclampsia
 EUO/F 1.5 cm, F/C 8 cm 163.0 cm

17/08-93 freshening, dissection also minimally bladder from R symphysis/ pubic bone, transverse bladder/urethra closure (with complete? adaptation anteriorly) by inverting chromic catgut, transverse avw closure with everting chromic catgut and 4x supramid, FOLEY Ch 20, vagina pac; a free flow of urine, good bladder capacity (EUO/BW 12 cm), good elevation, EUO/B 3 cm anesthetic
 minimal pain at paraurethral avw suturing 2x

- 12.09.93 incontinence cath removed bladder drill
- 19.09.93 not leaking, incontinence \pm , normal miction healed, stress \pm
- 17.10 + 21.11.93 idem
- 24.01.94 not leaking at all, no incontinence, normal miction insp/ healed, good elevation, no stress incontinence



2 cm

kak (kano city)

female

32 yr

13/07-93

diagnosis: PII (0 alive), \pm 4 cm 0 **necrotic** urethrovesicovaginal fistula L bladder neck **IIAa, leaking urine for 5 days which started 1 day** following obstructed last labor for 2 days, in hospital SB male, married 20 yr ago pre (menarche 1 yr later), still living with husband, no menstruation, no RVF, drop foot R (grade 4) and L (grade 3), very poor general condition
 EUO/F 2 cm, F/C 3 cm 154.5 cm

13/07-93 FOLEY Ch 18; later for early closure

22/08-92 now \pm 2 cm 0 clean urethrovesicovaginal fistula L bladder neck; EUO/F 2 cm, F/C 4 cm, condition better but still poor
leaking urine for 46 days
 freshening, minimal dissection, transverse bladder/urethra closure with inverting chromic catgut, transverse avw closure with everting chromic catgut/3x supramid, FOLEY Ch 20, vagina pack; free urine flow, good bladder capacity (EUO/BW 10 cm) and good elevation, EUO/B 3 cm
 only slight pain at L paraurethral avw suture anesthetic

01/11-93 **fistula** condition ok

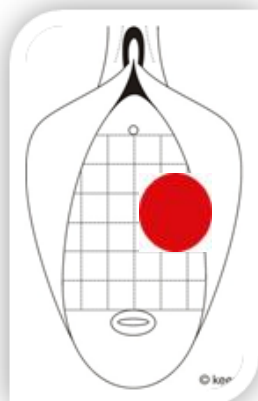
09/11-93 operation: UVVF-repair **vvf 691**

23.11.93 not leaking at all cath removed bladder drill

08.12.93 not leaking at all, no incontinence, normal miction
 insp/ healed, good elevation, no stress incontinence

27.03.94 not leaking, incontinence \pm , miction healed, stress \pm bladder drill

21.11.94 not leaking at all, no incontinence, normal miction healed, no stress



4 cm

KANO

cath 224

zyykl (kano city)

female

15 yr

15/07-93

diagnosis: PI, \pm 2 cm 0 **necrotic** urethrovesicovaginal fistula **IIAa** midline bladder neck, **leak ing urine for 2 days which started 1 day** following obstructed labor for 2 days, at home SB male, married 1.5 yr ago pre(menarche same month), not living with husband, no menstruation, drop foot R (grade 3), no RVF
EUO/F 2 cm, F/C 7 cm 163.5 cm

15/07-93 FOLEY Ch 18; free flow of urine, good bladder capacity (EUO/BW 13 cm), good elevation, EUO/B 4 cm; later for early closure

22/08-93 not leaking at all; insp/ healed catheter removed

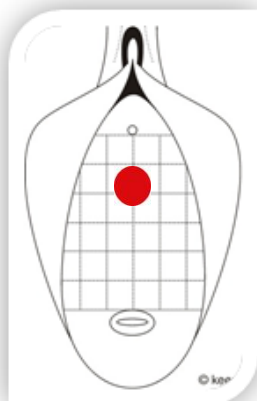
13/09-93 **overflow > 1,000 ml urine** foley ch 18

29.09.93 not leaking at all

18.10.93 cath out x 4/7 not leaking at all, no incontinence, normal miction
insp/ healed, good elevation, no stress incontinence

21.11 + 17.01.94 idem

20.03.94 not leaking at all, no incontinence, normal miction healed, no stress



2 cm

KANO

cath 225

rtayt (kano city) female 15 yr 26/07-93

diagnosis: PI, \pm 1 cm 0 necrotic vesicovaginal fistula **IIAa** at midline bladder neck, **leaking urine for 4 days** which started immediately following obstructed labor for 1 day, in hospital live female infant which died 1 day later, married 3 yr ago pre(menarche 8 mth later), not living with husband, no menstruation, no drop foot, no RVF
EUO/F 4 cm, F/C 3 cm 147.0 cm

26/07-93 FOLEY Ch 18; later for early closure

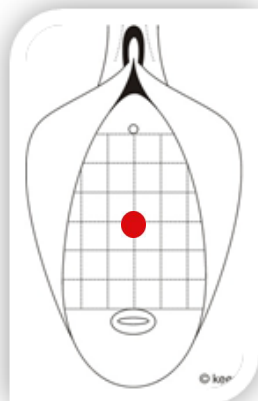
22/08-93 now \pm 5 mm 0 clean fistula; EUO/F 4 cm, F/C 3 cm
freshening, minimal dissection, transverse bladder closure with inverting chromic catgut, transverse avw closure with everting chromic catgut and 3x supramid, FOLEY Ch 20, vagina pack; free urine flow, good bladder capacity (EUO/BW 11 cm), good elevation, EUO/B 4 cm anesthetic slight pain at avw closure

05.09 + 19.09.93 not leaking at all cath removed bladder drill

26.09.93 not leaking at all, no incontinence, normal miction
insp/ healed, good elevation, no stress incontinence

11.10 + 23.11.93 idem

09.01.94 not leaking at all, no incontinence, normal miction healed, no stress



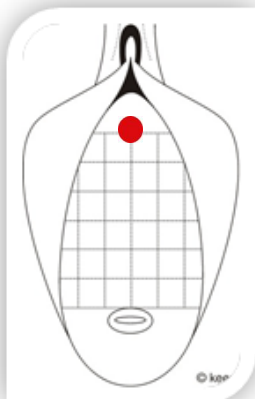
1 cm

bik (kano city) female 14 yr 26/07-93

diagnosis: PI, overflow incontinence due to atonic bladder, **leaking urine for 20 days** which started 3 days (eclampsia) following obstructed labor for 2 days, in hospital SB male, married 1 yr ago pre(menarche 3 mth later), not living with husband, no menstruation, drop foot R (grade 3) and L (grade 4), no RVF 164.0 cm

26/7-93 suprapubic mass, avw bulging into vagina, bladder overdistended (EUO/BW 15 cm), EUO/B 3 cm, > 1 liter urine FOLEY Ch 18

06.09.93 not leaking at all cath removed bladder drill
12.09.93 not leaking at all, no incontinence, normal miction
insp/ healed, good elevation, no stress incontinence
11.10.93 idem
13.11.93 not leaking at all, no incontinence, normal miction healed, no stress
02/10-94 **amenorrhea for 3 mth** not leaking at all **instructions**



zid (kano city) female 41 yr 26/07-93

diagnosis: PXIII (6 alive), \pm 3 cm 0 necrotic urethrovesicovaginal fistula **IIAa, leaking urine for 9 days which started 1 day** following obstructed last labor for 3 days, in hospital SB male, married 30 yr ago premenarche 2 yr later), still living with husband, no drop foot, no menstruation, **necrotic pwv and stool incontinence**
EUO/F 3 cm, F/C 5 cm 161.0 cm

26/7-93 FOLEY Ch 18; free flow of urine, good bladder capacity (EUO/BW 12 cm, moderate elevation, EUO/B 3 cm; later for early closure

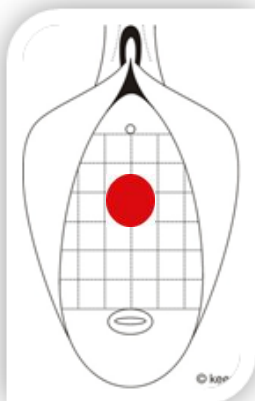
22/8-93 not leaking at all; insp/ UVVF healed, granulations pwv no RVF catheter removed

12.09.93 not leaking, incontinence \pm , normal miction healed, stress \pm

10.10.93 not leaking at all, no incontinence, normal miction pwv stricture
insp/ healed, poor elevation, no stress incontinence

21.11.93 idem cystocele +

20.01.94 not leaking at all, no incontinence, normal miction healed, no stress



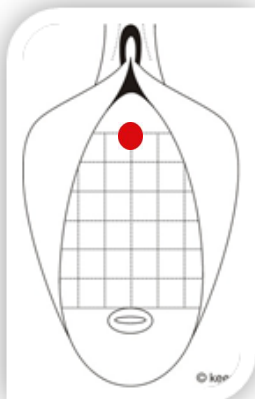
3 cm

skf (kano city) female 14 yr 27/07-93

diagnosis: PI, stress incontinence?? (it does not seem atonic bladder??), **leaking urine for 14 days** which started immediately following obstructed labor for 2 days, in hospital SB female, married 1.5 yr ago pre(menarche 4 mth), not living with husband, no menstruation, no drop foot (both grade 5), no RVF 159.0 cm

27/07-93 FOLEY Ch 18; moderate bladder capacity (EUO/BW 9 cm), no elevation, EUO/B 3 cm

- 30.08.93 incontinence cath removed bladder drill
- 06.09.93 leaking & miction gv/ healed, stress + **bladder drill**
- 13.11.93 only leaking whilst sitting, normal miction healed, no stress
- 17.01.94 not leaking at all, no incontinence, normal miction insp/ healed, good elevation, no stress incontinence
- 28.01.94 not leaking at all, no incontinence, normal miction healed, no stress



KANO

cath 229

documented 23.08 before/after + 19.09 + 11.10 +

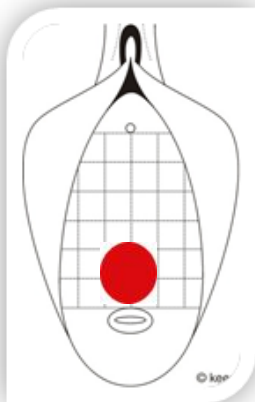
atrk (kano city) female 15 yr 23/08-93

diagnosis: PI, very extensive \pm 1.5 cm 0 urethrovesicovaginal fistula **IIAa** at whole bladder neck/base, **leaking urine for 41 days** which started immediately following obstructed labor for 4 days, in hospital (eclampsia) a SB female, married 2 yr ago pre(menarche 3 mth later), not living with husband, no menstruation, drop foot R (grade 4) and L (grade 3), no RVF, open episiotomy R, slight vagina stenosis/shortening; when seen 26/7-93 at 14 day leakage everything was necrotic
EUO/F 3.5 cm, F/C 0 cm 163.0 cm

23/08-93 freshening, dissection, transverse bladder/urethra closure with inverting chromic catgut, transverse avw closure with everting chromic catgut and 3x supramid, FOLEY Ch 18, vagina pack; free urine flow (no loin pain), moderate bladder capacity (EUO/BW 9 cm), good elevation, EUO/B 3 cm only **pain in the legs** not at operation site anesthetic

12.09 + 19.09.93 not leaking at all cath removed bladder drill
26.09.93 not leaking at all, no incontinence, normal miction
insp/ healed, good elevation, no stress incontinence
11.10 + 13.12 + 09.01.94 idem
20.03.94 ^not leaking at all, no incontinence, normal miction healed, no stress
card lost

documented 23.08 before/after + 19.09 + 11.10



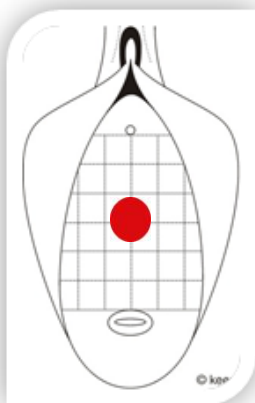
1.5 cm

fyzg (kano city) female 15 yr 23/08-93

diagnosis: PI, extensive ± 1.5 cm 0 urethrovesicovaginal fistula **IIAb** midline with small circumferential defect, **leaking urine for 20 days** which started 2 days following obstructed labor for 3 days, in hospital SB male, married 2 yr ago pre(menarche 2 mth later), not living with husband, no menstruation, drop foot R (grade 4) and L (grade 4-5), no RVF
 EUO/F 2.5 cm, F/C 2.5 cm 146.0 cm

23/08-93 freshening, dissection, transverse bladder/urethra closure (+ adaptation anteriorly) with inverting chromic catgut, transverse avw closure by evert-ing chromic catgut and 3x supramid, FOLEY Ch 18, pack; free flow of urine, good bladder capacity (euo/bw 10 cm), good elevation, euo/b 3 cm only slight pain at paraurethral avw closure anesthetic

- 05.09 + 19.09.93 not leaking at all cath removed bladder drill
- 26.09.93 not leaking, incontinence ±, normal miction healed, stress ±
- 11.10.93 idem
- 13.11.93 not leaking at all, no incontinence, normal miction
 insp/ healed, good elevation, no stress incontinence
- 17.01.94 idem
- 28.01.94 not leaking at all, no incontinnece, normal miction healed, no stress



1.5 cm

KANO

cath 231

hmk (kano city)

female

14 yr

02/08-93

diagnosis: PI, overflow incontinence due to atonic bladder, **leaking urine for 5 days** which started immediately following obstructed labor for 4 days, in hospital (eclampsia) a SB male, married 1 yr ago pre(menarche 1 mth later), not living with husband, no menstruation, drop foot R (grade 3) and L (grade 4), no RVF; \pm 4 cm 0 avw **IIAa** trauma R bladder neck
EUO/AVWT 3 cm 151.0 cm

02/08-93 suprapubic mass, avw bulging into vagina, bladder overdistended (EUO/BW 19 cm), EUO/B 3 cm, > 1 liter urine FOLEY Ch 18

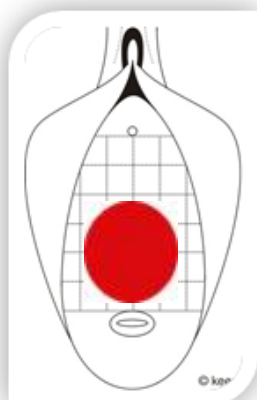
23/8-93 catheter out since this morning, not leaking, but again already signs of atonic bladder, avw trauma not yet completely healed FOLEY Ch 20 for 2 wk

13.09.93 not leaking at all cath removed bladder drill

19.09.93 not leaking at all, no incontinence, normal miction
insp/ healed, good elevation, no stress incontinence

17.10.93 idem

28.11.93 not leaking at all, no incontinence, normal miction healed, no stress



4 cm

KANO
documented 23.08 + 19.09.93

cath 232

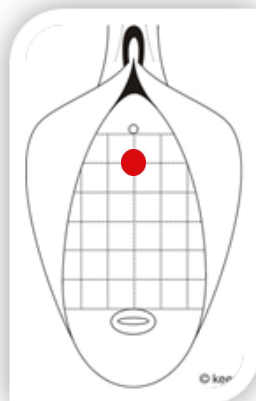
fgk (kano city) female 14 yr 23/08-93

diagnosis: PI, \pm 1 cm 0 urethrovesicovaginal fistula **IIAa, leaking urine for 9 days which started 2 days** following obstructed labor for 3 days in hospital SB female, married 2 yr ago pre(menarche 8 mth later), not living with husband, no menstruation, no drop foot, no RVF
EUO/F 1 cm, F/C 6 cm 153.0 cm

23/8-93 FOLEY Ch 18; it may heal spontaneously otherwise for early closure; free flow of urine, good bladder capacity (EUO/BW 13 cm), good elevation, EUO/B 3 cm

05.09 + 19.09.93 not leaking at all cath removed bladder drill
26.09.93 not leaking at all, no incontinence, normal miction
insp/ healed, good elevation, no stress incontinence
10.10 + 21.11 + 27.01.94 idem
20.03.94 not leaking at all, no incontinence, normal miction healed, no stress

documented 23.08 + 19.09



1 cm

KANO
documented 24.08.93 before/after

cath 233

hatw (kano city) female 15 yr 24/08-93

diagnosis: PI, \pm 1 cm 0 urethrovesicovaginal fistula **IIAa** midline bladder neck, **leaking urine for 25 days** which started immediately following obstructed labor for 5 days, in hospital craniotomy SB female, married 1 yr ago post (menarche 1 yr earlier), not living with husband, no menstruation, no RVF, drop foot R (grade 4) and L (grade 4-5); when seen 9/8-93 at 10 day leakage there was still necrotic fistula; FOLEY Ch 18 was inserted
EUO/F 2 cm, F/C 6 cm 147.5 cm

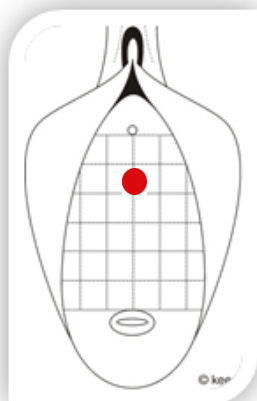
24/08-93 freshening, dissection, transverse bladder/urethra closure with inverting chromic catgut, transverse avw closure with everting chromic catgut and 3x supramid, FOLEY Ch 18, vagina pack; free urine flow, good bladder capacity (EUO/BW 10 cm), good elevation, EUO/B 4 cm anesthetic

26.09.93 not leaking at all cath removed bladder drill

03.10.93 not leaking at all, no incontinence, normal miction
insp/ healed, good elevation, no stress incontinence

17.10 + 28.11.93 idem

23.01.94 not leaking at all, no incontinence, normal miction healed, no stress



1 cm

KANO

cath 234

amdsr (kano city)

female

25 yr

12/07-93

diagnosis: PII (2 alive), \pm 3 cm 0 necrotic vesicovaginal fistula **IIAa** midline, **leaking urine for 4 days which started 3 days** following obstructed last labor for 2 days, in hospital live male, married 3 yr ago post(menarche 9 yr earlier), still living with husband, no menstruation, drop foot R (grade 4) and L (grade 4), no RVF
 EUO/F 4 cm, F/C 2 cm 160.0 cm

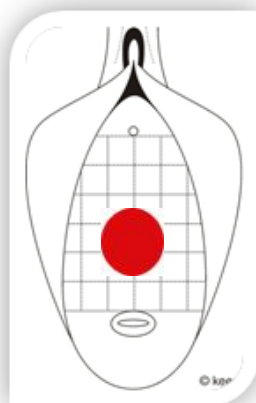
12/07-93 FOLEY Ch 18; later for early closure

24/08-93 now clean \pm 1.5 cm 0 vesicovaginal fistula midline bladder neck EUO/F 4 cm, F/C 2 cm
 freshening, dissection, transverse bladder/urethra closure with inverting chromic catgut, transverse avw closure with everting chromic catgut and 3x supramid FOLEY Ch 18, pack; free flow of urine, good bladder capacity (EUO/BW 10 cm), good elevation, EUO/B 4 cm anesthetic
 only slight pain at paraurethral avw closure

07.09 + 19.09.93 not leaking at all cath removed bladder drill

26.09.13 not leaking at all, no incontinence, normal miction insp/ healed, good elevation, no stress incontinence

28.11.93 not leaking at all, no incontinence, normal miction healed, no stress



3 cm

KANO
total intrinsic incontinence

cath 235

hrg (kano) female 33 yr 30/08-93

diagnosis: PX (5 alive), overflow incontinence due to atonic bladder (in the healing phase??), **leaking urine for 35 days** which started immediately upon removal of catheter (for 4 days) following CS (hysterectomy as cervix not identified) b.c.o. obstructed last labor for 2 days, a SB male, married 20 yr ago post(menarche 2 mth), still living with husband, no menstruation, drop foot R for 1 mth (now grade 5), no RVF 154.0 cm

30/8-93 no suprapubic mass, avw bulging into vagina, bladder distended
EUO/BW 12 cm, EUO/B 3 cm, > 500 ml urine FOLEY Ch 18

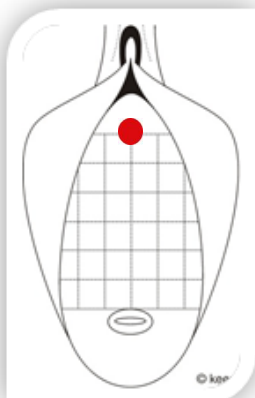
19.09.93 cath out x 2/7 leaking foley ch 18

03.10.93 cath out x 4/7 only leaking during night, never daytime

10.10.93 not leaking, incontinence \pm , normal miction bladder drill

31.10.93 not leaking at all, no incontinence, normal miction
insp/ healed, good elevation, no stress incontinence

28.11.93 not leaking at all., no incontinence, normal miction healed, no stress



KANO

cath 236

ryr (kano city)

female

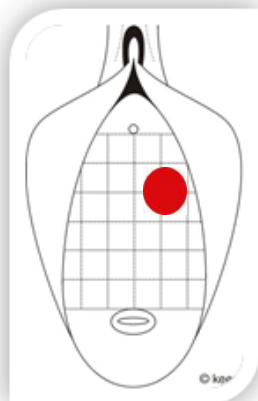
28 yr

31/08-93

diagnosis: PX (3 alive), ± 2.5 cm 0 urethrovesicovaginal fistula L bladder neck **IIAa** and bladder base prolapse, **leaking urine for 46 days** which started 15 days following obstructed last labor for 2 days, in hospital female twins (one SB and one live), married 17 yr ago pre(menarche 2 yr later), still living with husband, no RVF, no menstruation, no h/o drop foot (both grade 4-5)
 EUO/F 2 cm, F/C 5 cm 158.0 cm

31/08-93 freshening, dissection, transverse bladder/urethra closure with inverting chromic catgut, transverse avw closure with everting chromic catgut and 4x supramid, FOLEY Ch 18, pack; a free urine flow, good bladder capacity (EUO/BW 12 cm), good elevation and EUO/B 4 cm
 slight pain at paraurethral avw closure anesthetic

20.09 + 26.09.93 not leaking at all cath removed bladder drill
 03.10.93 not leaking at all, no incontinence, normal miction
 insp/ healed, good elevation, no stress incontinence
 17.10 + 21.11.93 idem
 30.01.94 not leaking at all, no incontinence, normal miction healed, no stress



2.5 cm

smyt (jigawa)

female

29 yr

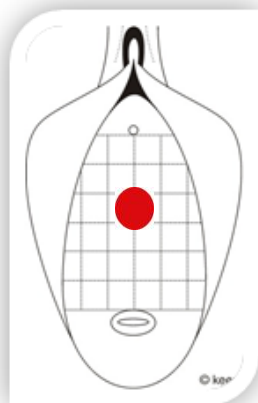
31/08-93

diagnosis: PVI (4 alive), \pm 2 cm 0 urethrovesicovaginal fistula **IIAa** at midline bladder neck, **leaking urine for 32 days** which started 23 days following CS b.c.o. obstructed last labor for 1 day (twins with hand prolapse), SB female twins, married 17 yr ago pre(menarche 8 mth later), still living with husband, no menstruation, drop foot R (grade 2-3), no RVF; when seen 16/8-93 balloon of catheter (inserted 2/8) was in partially necrotic fistula
 EUO/F 3 cm, F/C 4 cm 165.0 cm

31/08-93 freshening, dissection, transverse bladder/urethra closure with inverting chromic catgut, transverse avw closure with everting chromic catgut and 4x supramid, FOLEY Ch 18, pack; a free urine flow, good bladder capacity (EUO/BW 10 cm), good elevation and EUO/B 3 cm
 minimal pain at paraurethral avw closure anesthetic

19.09 + 26.09.93 not leaking at all cath removed bladder drill
 03.10.93 not leaking at all, no incontinence, normal miction healed, stress \pm
 17.10.93 not leaking at all, no incontinence, normal miction
 insp/ healed, good elevation, no stress incontinence
 28.11 + 23.01.94 idem
 20.02.94 not leaking at all, no incontinence, normal miction healed, no stress.

documented 16.08 + 31.08 before/after



2 cm

KANO

cath 238

rizk (kano city)

female

30 yr

31/08-93

diagnosis: PV (3 alive), \pm 5 mm 0 vesicovaginal fistula I at midline bladder base just in front of cervix, **leaking urine for 23 days** which started 5 days following obstructed last labor for 2 days, in hospital SB male, married 18 yr ago pre(menarche 1 yr later), still living with husband, no menstruation, no RVF, drop foot R (grade 4); when seen 23/8-93 at 15-day leakage still necrosis

EUO/F 7 cm, F/C 0 cm

143.5 cm

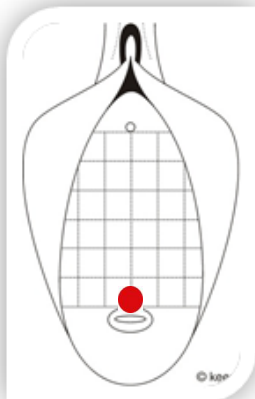
31/08-93 freshening, dissection, transverse bladder closure by inverting chromic catgut, transverse avw closure by everting chromic catgut/supramid 3x FOLEY Ch 18, pack; free urine flow, a moderate bladder capacity (EUO/BW 8 cm), moderate elevation, EUO/B 3 cm anesthetic no pain whatsoever

19.09 + 26.09.93 not leaking at all cath removed bladder drill

03.10.93 not leaking at all, no incontinence, normal miction insp/ healed, moderate elevation, no stress incontinence

27.10.93 idem

21.11.93 not leaking at all, no incontinence, normal miction healed, no stress



0.5 cm

KANO

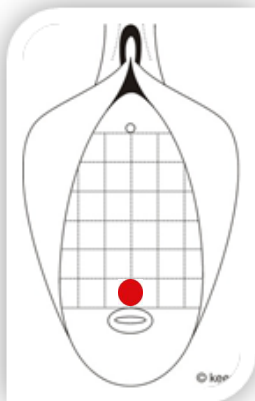
cath 239

asak (kano) female 43 yr 01/09-93

diagnosis: PXIII (3 alive), \pm 1 cm 0 vesicovaginal fistula midline bladder neck in front of cervix I, **leaking urine for 29 days** which started immediately following obstructed last labor for 2 days, in hospital SB male, married 30 yr ago pre(menarche 4 mth later), still living with husband, no menstruation, no RVF, drop foot R (grade 3); pat dirty
EUO/F 6 cm, F/C 0 cm 147.0 cm

01/09-93 freshening, dissection, tissue still friable, transverse bladder closure by inverting chromic catgut, transverse avw closure by 5x everting supramid, FOLEY Ch 18, vagina pack; free urine flow, moderate bladder capacity (EUO/ BW 7 cm), moderate elevation, EUO/B 4 cm anesthetic

19.09 + 26.09.93 not leaking at all? cath removed bladder drill
03.10.93 not leaking at all, no incontinence, normal miction
insp/ healed, moderate elevation, no stress incontinence
17.10 + 28.11 + 23.01.94 idem
20.02.94 not leaking at all, no incontinence, normal miction healed, no stress



1 cm

KANO

cath 240
RVF

nybb (jigawa)

female

26 yr

01/09-93

diagnosis: PV (2 alive), urge/stress incontinence, sphincter ani incontinence, **leaking urine/stool incontinence for 2 mth** which started immediately following obstructed last labor for 1 day, at home live female, married 15 yr ago pre(menarche 2 yr later), still living with husband, no menstruation, no h/o drop foot

sacral plexus trauma?????

163.0 cm

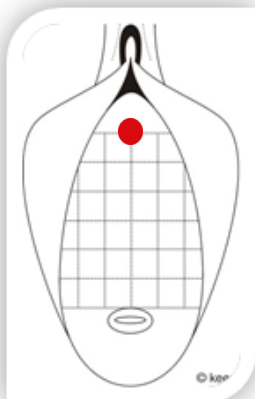
01/09-93 FOLEY Ch 18; free urine flow, moderate bladder capacity (EUO/ BW 9 cm), no elevation, EUO/B 4 cm

12.09 + 26.09 + 03.10.93 not leaking at all, stools ok cath removed drill

11.10.93 leaking insp_gv/ no leakage foley ch 18

17.10 + 31.10.93 not leaking at all cath removed bladder drill

05/11-93 not leaking at all, no incontinence, normal miction stools ok
 insp/ healed, moderate elevation, stress incontinence ++

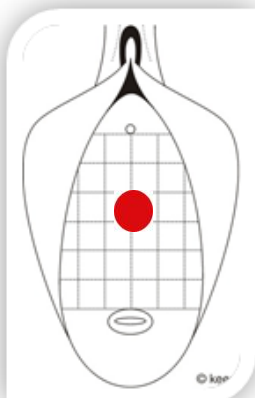


hug (jigawa) female 15 yr 23/08-93

diagnosis: PI, ± 3 cm 0 necrotic vesicovaginal fistula **IIAa** at midline bladder neck, **leaking urine for 9 days which started 2 days** following obstructed labor for 2 days, in hospital live male who died few hours later, married 1 yr 7 mth ago post(menarche 4 mth earlier), not living with husband, no drop foot, no RVF
EUO/F 4 cm, F/C 5 cm 145.5 cm

23/08-93 FOLEY Ch 18; free flow of urine, good bladder capacity (EUO/BW 14 cm), good elevation, EUO/B 4 cm; later for early closure

05/09-93 not leaking at all insp/ almost healed
12.09 + 16.09.93 not leaking at all healed cath removed bladder drill
26.09.93 not leaking at all, no incontinence, normal miction
insp/ healed, good elevation, no stress incontinence
11.10.93 idem
31.10.93 not leaking at all, no incontinence, normal miction healed, no stress



3 cm

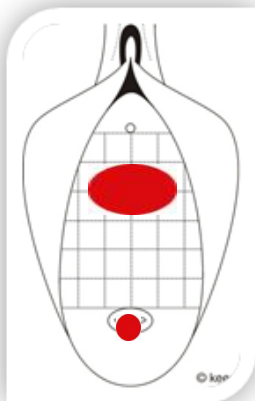
rbkt (katsina) female 14 yr 30/08-93

diagnosis: PI, ± 4x2 cm necrotic urethrovesicovaginal fistula **IIAa** bladder neck **leaking urine for 5 days which started 9 days** following craniotomy bco obstructed labor for 4 days, SB male, married 1 yr ago pre(menarche 1 mth later), not living with husband, no menstruation, drop foot R (grade 3) and L (grade 3), no RVF though **pvw traumatized**
EUO/F 2.5 cm, F/C 5 cm 161.5 cm

30/08-93 FOLEY Ch 18; later for early closure

06/09-93 now clean ± 2 cm 0 urethrovesicovaginal fistula R bladder neck; EUO/F 2.5 cm, F/C 5 cm; leaking 16 days anesthetic freshening, dissection, transverse bladder/urethra closure with inverting chromic catgut, transverse avw closure with everting chromic catgut and 3x supramid, FOLEY Ch 18, pack; a free urine flow, good bladder capacity (EUO/BW 12 cm), good elevation and EUO/B 3 cm only slight pain at paraurethral avw closure (2 sutures)

27/03-94 not leaking at all, no incontinence, normal miction insp/ healed, good elevation, no stress incontinence



4x2 cm

KANO

cath 243

rikb (kano city)

female

32 yr

06/09-93

diagnosis: PX (4 alive), one \pm 1 cm 0 urethrovesicovaginal fistula and one \pm 1 cm 0 vesicovaginal fistula L just in front of cervix, **leaking urine for 64 days** which started immediately following obstructed last labor for 1 day, in hospital SB female, married 20 yr ago pre(menarche 1 yr later), still living with husband, no menstruation, drop foot R (grade 3-4) and L (grade 0), no RVF; when seen 12/7-93 at 8-day dur very poor condition
EUO/F 2 cm, F/F 6 cm, F/C 0 cm 156.0 cm

06/09-93 freshening of fistula L bladder base, minimal dissection, then transverse bladder closure by inverting chromic catgut, transverse avw closure with everting chromic catgut and 3x supramid, FOLEY Ch 18, pack; the UVVF cannot be repaired in this session EUO/BW 15 cm, EUO/B 2.5 cm
first stage!! no pain but pat very nervous! anesthetic

24/10-93 sometimes leaking & normal miction insp/ **healed**

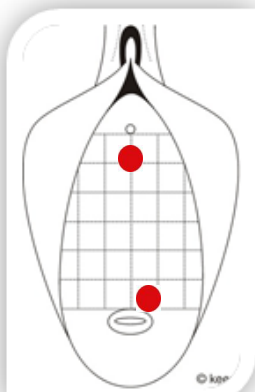
25/10-93 operation: UVVF-repair second stage **vvf 672**

08.11.93 not leaking at all cath removed bladder drill

13.11.93 not leaking at all, no incontinence, normal miction
insp/ **both** healed, good elevation, no stress incontinence

28.11 + 24.01.94 idem

20.03.94 not leaking at all, no incontinence, normal miction **both** healed, no stress



multiple fistulas

aimg (jigawa)

female

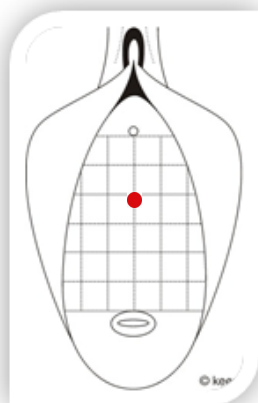
17 yr

07/09-93

diagnosis: PII (1 alive), \pm 2 mm 0 vesicovaginal fistula **IIAa** midline bladder neck, **leaking urine for 60 days which started 2 days** following obstructed last labor for 4 days, in hospital SB male, married 4 yr ago pre(menarche 2 mth later), not living with husband, no menstruation, drop foot R (grade 3) and L (grade 2), no RVF
 EUO/F 4 cm, F/C 7 cm 161.0 cm

07/09-93 transverse incision through fistula, dissection, extirpation of some scar tissue, transverse bladder closure by inverting chromic catgut, transverse avw closure with everting chromic catgut and 3x supramid, FOLEY Ch 18, pack; free urine flow, good bladder capacity (EUO/BW 12 cm), good elevation, EUO/B 4 cm no pain whatsoever anesthetic

03.10 + 10.10.93 not leaking at all cath removed bladder drill
 25.10.93 not leaking at all, no incontinence, normal miction
 insp/ healed, good elevation, no stress incontinence
 21.11.93 idem
 30.01.94 not leaking at all, no incontinence, normal miction healed, no stress



0.2 cm

KANO

cath 245

documented 06.09 + 13.09 + 19.09 + 29.09.93 + 09.01.94

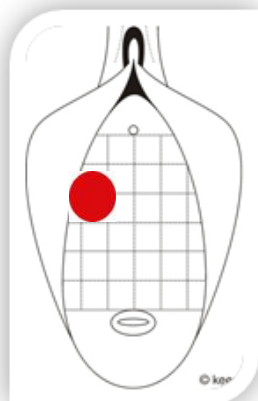
mya (bauchi) female 15 yr 06/09-93

diagnosis: PI, \pm 3 cm 0 urethrovesicovaginal fistula R bladder neck **IIAa, leaking urine for 4 days which started 4 days** following obstructed labor for 2 days, in hospital an SB female, married 1.5 yr ago post(menarche 3 mth earlier), not living with husband, no menstruation, drop foot R (grade 4) and L (grade 4), no RVF, ulcer L buttock
EUO/F 2 cm, F/C 5 cm 152.0 cm

06/09-93 FOLEY Ch 18; free flow of urine, good bladder capacity (EUO/BW 10 cm), moderate elevation, EUO/B 2 cm; later for early closure though it may heal spontaneously

13.09 + 29.09.93 not leaking at all insp_gv/ no leakage cath removed
17.10.93 not leaking at all, no incontinence, normal miction
insp/ healed, good elevation, no stress incontinence
25.10 + 21.11 + 09.01.94 idem
07.03.94 not leaking at all, no incontinence, normal miction healed, no stress

documented 06.09 + 13.09 + 19.09 + 29.09 + 09.01



3 cm

KANO
documented 13.09.93 before/after

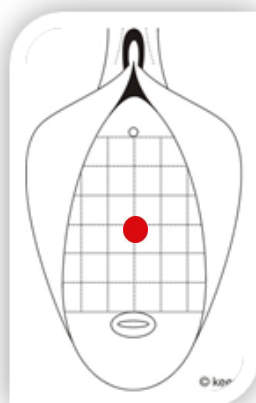
cath 246

hshgz (kano city) female 20 yr 13/09-93

diagnosis: PIV (2 alive), \pm 1 cm 0 vesicovaginal fistula I midline bladder base, **leaking urine for 8 days which started 13 days** following obstructed last labor for 2 days, at home live female, married 8 yr ago pre(menarche 8 mth later), still living with husband, no menstruation, no drop foot, no RVF
EUO/F 6 cm, F/C 4 cm 153.0 cm

13/09-93 freshening, dissection, transverse bladder closure by inverting chromic catgut, transverse avw closure by everting chromic catgut/3x supramid foley ch 18, pack; free urine flow, good bladder capacity (wuo/bw 11 cm), moderate elevation, EUO/B 4 cm no pain whatsoever anesthetic

29.09 + 17.10.93 not leaking at all cath removed bladder drill
24.10.93 not leaking at all, no incontinence, normal miction
insp/ healed, good elevation, no stress incontinence
13.11.93 not leaking at all, no incontinence, normal miction healed, no stress



1 cm

KANO
documented 13.09.93 before/after

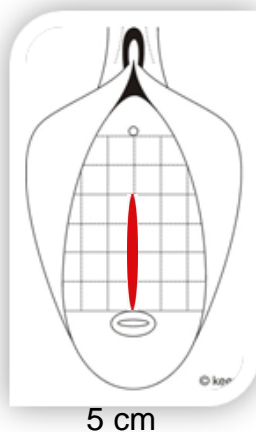
cath 247

rabk (kano city) female 24 yr 13/09-93

diagnosis: PIII (2 alive), \pm 2 mm 0 vesicovaginal fistula **IIAa** midline bladder neck at top of 5 cm long median scar from cervix onwards, leaking urine for 2 yr which started 11 days following obstructed 2nd labor for 3 days, at home SB male, married 12 yr ago pre(menarche 8 mth later), still living with husband, normal menstruation, no h/o drop foot, no RVF; pt put baobab leave powder inside vagina to seal off the leakage! delivered 3 mth ago EUO/F 4 cm, F/C 5 cm 151.0 cm

13/09-93 transverse incision thru fistula, dissection, transverse bladder closure by inverting chromic catgut, transverse avw closure by everting chromic catgut and 3x supramid, FOLEY Ch 18, vagina pack; free urine flow, moderate bladder capacity (EUO/BW 9 cm), moderate elevation, EUO/B 3 cm no pain whatsoever anesthetic

29.09 + 10.10.93 not leaking at all cath removed bladder drill
17.10.93 not leaking at all, no incontinence, normal miction
insp/ healed, good elevation, no stress incontinence
31.10.93 idem
28.11.93 not leaking at all, no incontinence, normal miction healed, no stress



KANO
documented 13.09 before/after

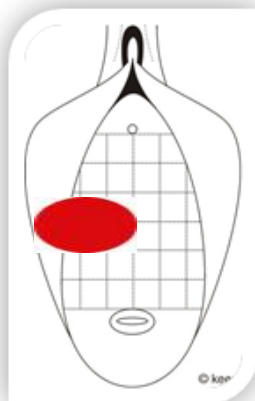
cath 248

mmyk (sokoto) female 20 yr 13/09-93

diagnosis: PIII (2 alive), \pm 4x2 cm urethrovesicovaginal fistula **IIAb** with some necrosis at R bladder neck (circum defect??), **leaking urine for 20 days which started 8 days** following obstructed last labor for 2 days, in hospital SB male, married 6 yr ago post(menarche 8 mth earlier), not living with husband, no menstruation, no h/o drop foot, no RVF
EUO/F 3 cm, F/C 2.5 cm 155.0 cm

13/09-93 freshening with extirpation of some necrotic tissue, dissection transverse bladder/urethra closure by inverting chromic catgut, transverse avw closure by everting chromic catgut/5x supramid, FOLEY Ch 18 and pack; a free urine flow, good bladder capacity (EUO/BW 11 cm), good elevation, EUO/ B 4 cm anesthetic
only slight pain at 1x paraurethral avw closure R

29.09 + 10.10.93 not leaking at all cath removed bladder drill
17.10.93 not leaking at all, no incontinence, normal miction
insp/ healed, good elevation, no stress incontinence
31.10 + 28.11 + 30.01.94 idem
27.03.94 not leaking at all, no incontinence, normal miction healed, no stress



4x2 cm

KANO

cath 249
RVF

hayk (kano city) female 16 yr 14/09-93

diagnosis: PI, overflow incontinence due to atonic bladder, **leaking urine for 8 days** which started 1 day following obstructed labor for 2 days, in hospital an SB female, married 3 yr ago pre(menarche 1 mth later), not living with husband, no menstruation, drop foot R (grade 2) and L (grade 2), no RVF; further assessment not possible as **vagina completely traumatized (necrotic???) IIBb** 151.0 cm

14/9-93 suprapubic mass, avw bulging into vagina, bladder overdistended (EUO/BW 22 cm!), EUO/B 3 cm, > 2 liter urine FOLEY Ch 18

17/10-93 1.5 cm fistula type IIBb

19/10-93 operation: "circumferential" UVVF-repair vvf 671

01.11 + 20.11.93 not leaking at all cath removed bladder drill

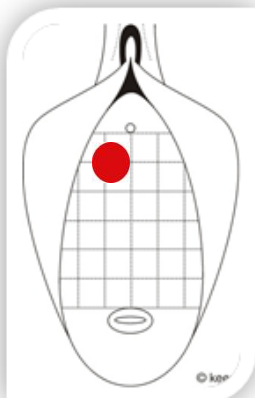
13/04-94 not leaking, urge incontinence \pm , normal miction insp/ healed, poor elevation, no stress incontinence

10/10-94 only leaking \pm whilst lying, normal miction **bladder drill**
gv: EUO/BW 11 cm, poor elevation, EUO/B 2 cm stress ++

11/10-94 operation: anterior colposuspension VVF 890

14.11.94 not leaking, incontinence \pm , normal miction

08.02.98 not leaking at all, no incontinence, normal miction insp/ healed, moderate elevation, stress incontinence ++



1.5 cm

KANO
documented 19.09 + 03.10.93

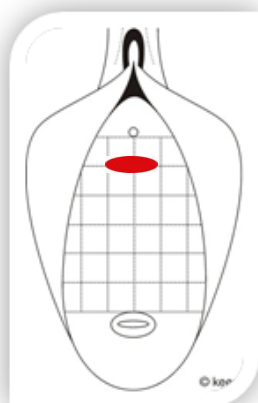
cath 250

mug (kano) female 14 yr 19/09-93

diagnosis: PI, \pm 1.5x0.5 cm necrotic urethrovesicovaginal fistula type **IIAa** midline, **leaking urine (incontinence) for 3 days** which started immediately following obstructed labor for 2 days, in hospital (eclampsia) SB female, married 2 yr ago pre(menarche 6 mth later), no RVF, not living with husband, no h/o drop foot (but L grade 4)
EUO/F 1 cm, F/C 6 cm 155.5 cm

19/09-93 FOLEY Ch 18; free urine flow, moderate bladder capacity (EUO/BW 9 cm), no elevation, EUO/B 2 cm; this will heal spontaneously

03.10 + 17.10.93 not leaking at all cath removed bladder drill
25.10.93 leaking & miction healed, euo wide open, stress ++
13.11.93 not leaking, incontinence \pm , normal miction healed, stress \pm
17.01.94 not leaking at all, no incontinence, normal miction
insp/ healed, moderate elevation, no stress incontinence
24.04.94 not leaking at all, no incontinence, no stress incontinence



1.5x0.5 cm

KANO
documentation 20.09.93 before/after

cath 251

rjmt (kano city) female 16 yr 20/09-93

diagnosis: PI, \pm 2 mm 0 vesicovaginal fistula I midline bladder neck, **leaking urine for 42 days** which started immediately following obstructed labor for 3 days, in hospital (eclampsia) an SB male, married 4 yr ago pre(menarche 1 yr later), not living with husband, no menstruation, no h/o drop foot (but both R and L grade 4),no RVF
EUO/F 4.5 cm, F/C 6 cm 169.0 cm

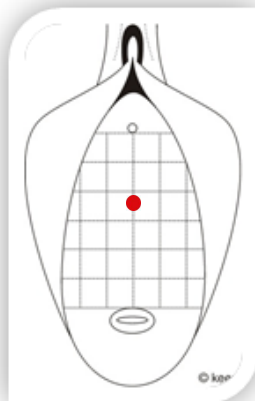
20/09-93 transverse incision thru fistula, dissection, transverse bladder closure by 1x chromic catgut cross suture, transverse avw closure with everting chromic catgut/3x supramid, FOLEY Ch 18, vagina pack; free flow of urine, good bladder capacity (EUO/BW 10 cm), moderate elevation, EUO/B 4 cm no pain whatsoever anesthetic

04.10 + 17.10.93 not leaking at all cath removed bladder drill

24.10.93 not leaking at all, no incontinence, normal miction
insp/ healed, good elevation, no stress incontinence

13.11 + 15.12 + 24.01.94 idem

27.03.94 not leaking at all, no incontinence, normal miction healed, no stress



KANO
second obstetric fistula

cath 252
VVF 308

aiz (kano) female 17 yr 20/9-93

diagnosis: PII (0 alive), \pm 5 mm 0 urethrovesicovaginal fistula **IIAa** within \pm 1 cm 0
 avw defect, **leaking urine for 56 days which started 9 days** following
 obstructed last labor for 2 days, in hospital a live male which died 3 days
later, married 5 yr ago pre(menarche 7 mth later), not living with husband,
 no menstruation, no RVF, no h/o drop foot, moderate vagina shortening
 EUO/AVWD 2 cm, AVWD/C 2 cm 154.0 cm

20/09-93 freshening, dissection, transverse bladder/urethra closure with inverting
 chromic catgut, transverse avw closure with everting chromic catgut and
 3x supramid, FOLEY Ch 18, vagina pack; free urine flow, small bladder
 capacity (EUO/BW 6 cm), good elevation, EUO/B 4 cm anesthetic

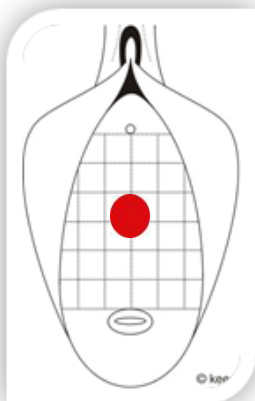
04.10 + 17.10.93 not leaking at all cath removed bladder drill

24.10.93 not leaking at all, no incontinence, normal miction
 insp/ healed, good elevation, no stress incontinence

13.11 + 15.12.93 idem

28.02.94 not leaking at all, no incontinence, normal miction healed, no stress

31/07-94 **amenorrhea for 3 mth** not leaking at all **instructions**



KANO

cath 253

sikk (kano city)

female

37 yr

12/09-93

diagnosis: PVIII (5 alive), \pm 1.5 cm 0 necrotic vesicovaginal fistula I next to R cervix, **leaking urine for 13 days** which started immediately following obstructed last labor for 2 days, in hospital a SB female, married 25 yr ago pre(menarche 1 yr later), still living with husband, no menstruation, drop foot R (grade 4) and L (grade 4), no RVF
EUO/F 10 cm, F/C 0 cm 147.0 cm

12/9-93 FOLEY Ch 18; free flow of urine, good bladder capacity (EUO/BW 12 cm), good elevation, EUO/B 4 cm; for early closure following gv check

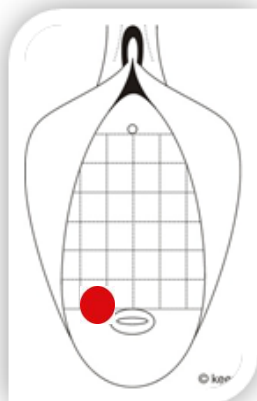
20/9-93 looks like it will heal spontaneously; gv: no leakage

26.09 + 10.10.93 not leaking at all cath removed bladder drill

17.10.93 not leaking at all, no incontinence, normal miction
insp/ healed, good elevation, no stress incontinence

31.10 + 28.11 + 24.01.94 idem

20.02.94 not leaking at all, no incontinence, normal miction healed, no stress



1.5 cm

KANO

cath 254

hhab (kano city)

female

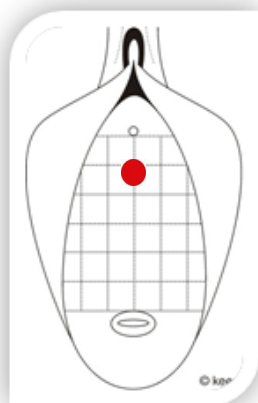
17 yr

29/09-93

diagnosis: PI, \pm 1 cm 0 urethrovesicovaginal fistula **IIAb** midline with urethra block, **leaking urine for 45 days which started 3 days** following obstructed labor for 2 days, in hospital SB male, married 4 yr ago pre(menarche 5 mth later), not living with husband, no menstruation, no h/o drop foot, no RVF, minimal vagina stenosis
EUO/F 2 cm, F/C 7 cm 156.0 cm

29/09-93 freshening, dissection, transverse bladder/urethra closure with inverting chromic catgut, transverse avw closure by everting chromic catgut/supra mid 3x, FOLEY Ch 18, pack; free urine flow, good bladder capacity (EUO/BW 12 cm), good elevation, EUO/B 3 cm anesthetic no pain whatsoever

17.10 +24.10.93 not leaking at all cath removed bladder drill
31.10.93 not leaking, incontinence \pm , normal miction healed, stress \pm
21.11.93 idem
17.01.94 not leaking at all, no incontinence, normal miction insp/ healed, good elevation, no stress incontinence
27.03.94 not leaking at all, no incontinence, normal miction healed, no stress



1 cm

KANO

cath 255

ammsn (kano)

female

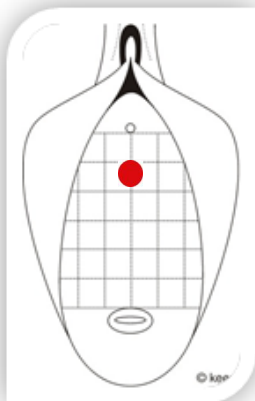
19 yr

30/09-93

diagnosis: PII (0 alive), \pm 1 cm 0 urethrovesicovaginal fistula **IIAa** or better scarred avw defect with seeping thru, **leaking urine for 33 days which started 52???? days** following obstructed last labor for 2 days, at home SB male, married 7 yr ago pre(menarche 1 yr later), still living with husband, no menstruation, drop foot R (grade 3) and L (grade 3), no RVF
EUO/AVWD 2 cm, AVWD/C 7 cm 150.0 cm

30/09-93 freshening, dissection, extirpation of scar tissue ++, transverse bladder/urethra closure with inverting chromic catgut, transverse avw closure with everting chromic catgut 00 and 4x supramid, FOLEY Ch 18, vagina pack; free urine flow, atonic bladder?? (EUO/BW 18 cm), good elevation, EUO/B 2.5 cm no pain whatsoever anesthetic

- 17.10 + 31.10.93 not leaking at all cath removed bladder drill
- 07.11.93 atonic bladder, > 1,500 ml urine foley ch 18
- 13.11 + 22.11.93 not leaking at all cath removed bladder drill
- 28.11.93 not leaking at all, no incontinence, normal miction
insp/ healed, good elevation, no stress incontinence
- 17.01 + 20.02.94 idem
- 27.03.94 not leaking at all, no incontinence, normal miction healed,no stress



1cm

KANO
second obstetric fistula

cath 256
cath 30

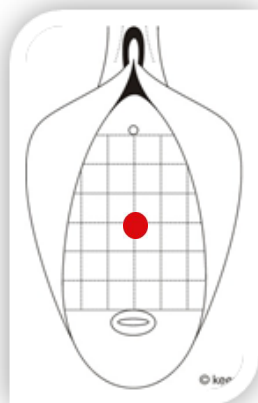
bdlkh (kano city) female 32 yr 30/09-93

diagnosis: PVI (5 alive), ± 5 mm 0 vesicovaginal fistula **IIAa** midline bladder neck, **leaking urine for 41 days** which started immediately following obstructed last labor for 2 days, at home live female, married 22 yr ago pre(menarche 2 yr later), still living with husband, no menstruation, no h/o drop foot, no RVF
N.B. primary suturing 30/12-91 following delivery V
EUO/F 4 cm, F/C 3 cm 156.0 cm

30/09-93 a transverse incision thru fistula, dissection, scar tissue ++, transverse bladder closure by inverting chromic catgut, transverse avw closure with everting chromic catgut and 4x supramid, FOLEY Ch 18 and vagina pack; free flow of urine, moderate bladder capacity (EUO/BW 8 cm), moderate elevation, EUO/B 3 cm no pain whatsoever anesthetic

17.10 + 31.10.93 not leaking at all cath removed bladder drill
07.11.93 not leaking at all, no incontinence, normal miction
insp/ healed, good elevation, no stress incontinence
21.11.93 idem
17.04.94 not leaking at all, no incontinence, normal miction healed, no stress

third obstetric fistula completely ok until PVIII (7 alive) live female at home
23.09.96 operation: uvvf-repair vvf 1372
07.10 + 21.10.96 not leaking at all cath removed bladder drill
28.10.96 not leaking at all, no incontinence, normal miction
insp/ healed, good elevation, no stress incontinence
11.12.96 idem
13.05.97 not leaking at all, no incontinence, normal miction healed, no stress



0.5 cm

KANO

cath 257
RVF

ahkr (kano) female 25 yr 30/09-93

diagnosis: PIV (3 alive), very extensive 3 cm 0 urethrovesicovaginal fistula **IIAb** with urethra block/circumferential defect, **leaking urine for 49 days** which started immediately following craniotomy b.c. o. obstructed last labor for 2 days, SB male, married 13 yr ago pre(menarche 9 mth later), not living with husband, no menstruation, drop foot R (grade 3) and L (grade 2), no RVF

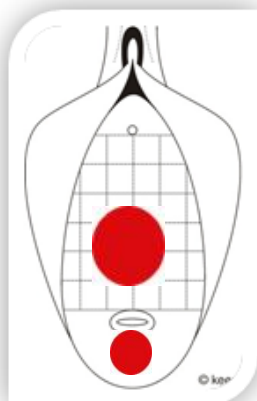
when seen 23/8-93 at 11 day duration, there was a large necrotic urine fistula and a 3 cm 0 necrotic proximal rectovaginal fistula; at 12/9-93 pat was still crawling and told she would be operated if she could walk with stick; so now she "walks" with stick

EUO/F 2.5 cm, F/C 1 cm 154.0 cm

30/09-93 freshening, dissection, circumferential dissection of bladder from avw/cervix/pubis/symphysis, advancement of bladder, completely tension-free circumferential UVVF-repair by end-to-end vesicourethrostomy starting with fixation of lateral bladder walls onto symphysis (adaptation anteriorly) by a single layer of inverting chromic catgut, transverse avw closure by everting chromic catgut and 5x supramid, FOLEY Ch 18, vagina pack; free flow of urine, good bladder capacity (EUO/BW 11 cm), good elevation, EUO/B 3 cm anesthetic vagina sufficient, pvw healed no pain whatsoever

17.10 + 31.10.93 not leaking at all "walks" without support cath removed
07.11.93 leaking/incontinence & miction healed, stress +
28.11 + 09.01.94 not leaking, incontinence +, miction healed, stress +
10/04-94 not leaking at all, no incontinence, normal miction euo/bw 14 cm
insp/ **both** healed, moderate elevation, stress incontinence + stools ok

03/10-94 now **leaking & normal miction** gv: no leakage, stress +
bladder drill ?what happened? **delivery?**



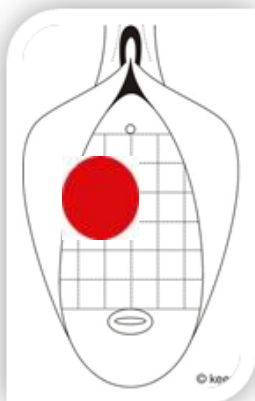
3 cm

mrimk (jigawa) female 15 yr 04/10-93

diagnosis: PI, very extensive \pm 3 cm 0 urethrovesicovaginal fistula R bladder neck **IIBb** with circumferential defect, **leaking urine for 25 days** which started 1 day following obstructed labor for 3 days, in hospital SB female, married 3 yr ago pre(menarche 11 mth later) not living with husband, no menstruation, drop foot R (grade 2) and L (grade 3), also stool incontinence; loss of labia minora, multiple bedsores R buttock/sacrum, partial pubococcygeus loss and moderate distal vagina stenosis; pat not fit for anesthesia poor condition bedsores documented 29.09.93
EUO/F 1 cm, F/C 2 cm 152.0 cm

04/10-93 freshening, dissection alsp of bladder from R pubic bone completely tension-free transverse bladder/urethra closure by single layer of inverting chromic catgut starting with fixation of R lateral bladder wall onto R symphysis, transverse avw closure with everting chromic catgut and 5x supramid, FOLEY Ch 18, pack; free urine flow, good bladder capacity (EUO/BW 11 cm), good elevation, EUO/B 3 cm anesthetic
no pain whatsoever confirming that the earlier it is as well as the more extensive the damage, the more anesthesia very difficult!

17.10 cath blocked/changed 30.10 + 07.11.93 leaking cath removed drill
13.11.93 not leaking at all, no incontinence, normal miction
insp/ healed, good elevation, stress incontinence **++**
28.11 + 09.01.94 idem
10.01.94 idem
gv: EUO/BW 8 cm, good elevation, EUO/B 2 cm, no leakage, urge +
bladder drill
27/03-94 not leaking at all, no incontinence, normal miction adter bladder drill
insp/ healed, good elevation, no stress incontinence condition ok



3 cm

KANO

cath 259

bhg (kano)

female

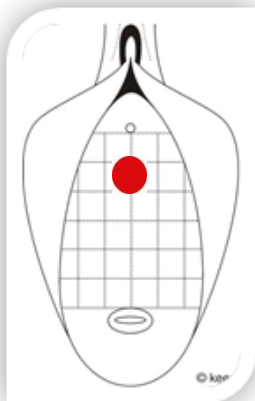
15 yr

04/10-93

diagnosis: PI, \pm 1.5 cm 0 urethrovesicovaginal fistula **IIAa** at midline, **leaking urine for 29 days** which started immediately following obstructed labor for 2 days, in hospital (eclampsia) live male which died 7 days later, married 2 yr ago post(menarche at 3 mth earlier), not living with husband, no menstruation, no RVF, no h/o drop foot (but R grade 4)
 EUO/F 1.5 cm, F/C 6 cm 152.0 cm

04/10-93 freshening, dissection, transverse bladder/urethra closure with inverting chromic catgut, transverse avw closure with everting chromic catgut and 4x supramid, FOLEY Ch 18, pack; free urine flow, good bladder capacity (EUO/BW 10 cm), moderate elevation, EUO/B 2 cm anesthetic
 slight pain at paraurethral avw closure

17.10 + 31.10.93 not leaking at all cath removed bladder drill
 07.11.93 not leaking at all, no incontinence, normal miction
 insp/ healed, good elevation, no stress incontinence
 21.11 + 22.12.93 idem
 20.02.94 not leaking at all, no incontinence, normal miction healed, no stress
 26/06-94 **amenorrhea for 3 mth** not leaking at all **instructions**



1.5 cm

hyb (kano)

female

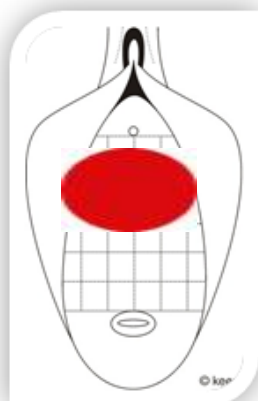
19 yr

04/10-93

diagnosis: PII (1 alive), ± 5x3 cm urethrovesicovaginal fistula **IIBb** with circumferential defect and still some necrosis, **leaking urine for 25 days** which started immediately following obstructed last labor for 4 days, in hospital SB female by vacuum, married 9 yr ago pre(menarche 3 yr later), not living with husband, no RVF, no menstruation, drop foot R (grade 3) and L (grade 3); when seen 19/9-93 catheter balloon (inserted 12.09) was inside necrotic fistula
 EUO/F 1 cm, F/C 3 cm 148.0 cm

04/10-93 freshening, **debridement**, dissection, bladder dissection from symphysis, "circumferential" closure by inverting chromic catgut starting by fixation of lateral bladder walls onto symphysis (!adaptation anteriorly!), transverse avw closure by everting chromic catgut/supramid 5x leaving it open laterally, FOLEY Ch 18, pack; free flow of urine, good bladder capacity (EUO/BW 10 cm), good elevation, EUO/B 2 cmq anesthetic
only slight pain at avw closure, not even at fixation of bladder to symphysis, very difficult!

- 18/07-94 leaking & normal miction gv: **leakage at L**
- 25/07-94 operation: UVVF-repair** **VVF 843**
- 03.10.94 leaking insp_gv/ fistula
- 13/03-95 operation: UVVF-repair** **VVF 997**
- 27.03.95 not leaking at all cath removed bladder drill
- 03.04.95 not leaking, incontinence ±, normal miction
 insp/ healed, good elevation, no stress incontinence
- 18.04 + 22.05 + 19.06.95 idem
- 12.09.95 not leaking, incontinence ±, normal miction healed, no stress



5x3 cm

hjab (kano city)

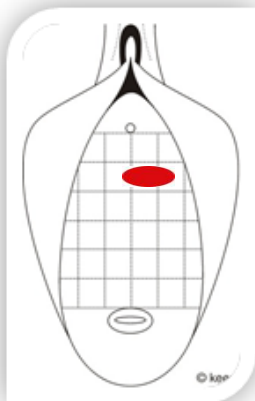
female 15 yr

04/10-93

diagnosis: PI, overflow incontinence due to atonic bladder, **leaking urine for 14 days which started 3 days** following vacuum extraction b.c.o. obstructed labor for 1 day, a live female, married 1 yr ago post(menarche 1 yr earlier), still living with husband, no menstruation, no h/o drop foot (but both R & L grade 4), no RVF \pm 1.5x1 cm avw trauma (due to vacuum) midline/L bladder neck **IIAa**
 EUO/AVWT 3 cm, AVWT/C 8 cm 150.0 cm

4/10-93 suprapubic mass, avw bulging into vagina, bladder overdistended (EUO/BW 18 cm), EUO/B 4 cm, > 1,500 ml urine FOLEY Ch 18 **increased** bladder capacity (longitudinal diameter 18-4 = 14 cm, **atonic bladder**)

17.10 + 31.10 not leaking 21.1193 cath out x 8/7 bladder drill
 21.11.93 not leaking at all, no incontinence, normal miction
 insp/ healed, good elevation, no stress incontinence
 15.12.93 not leaking at all, no incontinence, normal miction healed, no stress



1.5x1 cm

KANO
intrinsic incontinence 12.05.13

cath 262

hysdb (kano) female 16 yr 04/10-93

diagnosis: PI, overflow incontinence (but is it atonic bladder??), **leaking urine for 14 days** which started immediately following obstructed labor for 1 day, in hospital live male which died 2 days later, married 2 yr ago post(menarche 1 yr earlier), still living with husband, no h/o drop foot (both R & L grade 4-5), no RVF; \pm 1 cm necrotic avw over urethra type **IIAa**, \pm 2 cm avw trauma L bladder base in front of cervix
EUO/AVWN 1 cm, AVWN/AVWT 5 cm, AVWT/C 0 cm 163.0 cm
atonic bladder in healing phase??????

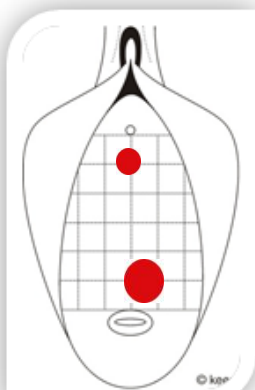
4/10-93 no suprapubic mass (pat mildly fat), avw bulging into vagina, no elevation, bladder distension?? (EUO/BW 13 cm), EUO/B 3 cm, < 500 ml urine FOLEY Ch 18, avw traumata will heal

17.10 + 31.10.93 leaking insp_gv/ healed cath removed bladder drill

13.11.93 not leaking at all, no incontinence, normal miction
insp/ healed, good elevation, no stress incontinence

05.01 + 30.01.94 idem

27.03.94 not leaking at all, no incontinence, normal miction healed, no stress



multiple trauma

KANO

cath 263

tskj (kano city)

female

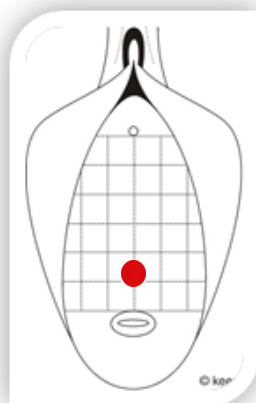
39 yr

05/10-93

diagnosis: PXI (6 alive), \pm 1 cm 0 vesicovaginal fistula I midline bladder base, **leaking urine for 72 days** which started immediately upon removal of catheter (for 17 days) following CS (25/7-93) b.c.o. obstructed last labor for 1 days, SB male, married 27 yr ago pre(menarche 1 yr later), still living with husband, no menstruation, drop foot R (grade 3) and L (grade 2), no RVF, slight vagina shortening
EUO/F 6 cm, F/C 1 cm 148.0 cm

05/10-93 freshening, dissection, transverse bladder closure by inverting chromic catgut, transverse avw closure by everting chromic catgut/3x supramid FOLEY Ch 18, pack; a free urine flow, moderate bladder capacity (EUO/BW 8 cm), good elevation, EUO/B 4 cm anesthetic
no pain whatsoever

24.10 + 31.10.93 not leaking at all cath removed bladder drill
07.11.93 not leaking at all, no incontinence, normal miction
insp/ healed, good elevation, no stress incontinence
28.11 + 24.01.94 idem
24.04.94 not leaking at all, no incontinence, normal miction healed, no stress



1 cm

KANO

cath 264

bamb (kano)

female

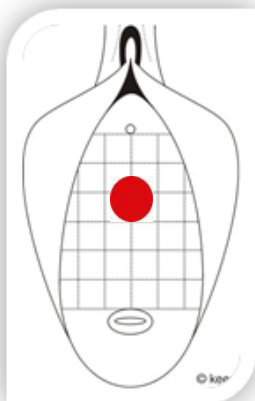
15 yr

11/10-93

diagnosis: PI, \pm 1.5 cm 0 urethrovesicovaginal fistula **IIAb** midline with minimal circumferential defect, **leaking urine for 48 days which started 2 days** following obstructed labor for 2 days, in hospital live female, married 2 yr ago pre(menarche 4 mth later), not with husband, no menstruation, drop foot R (grade 1-2), no RVF; slight/ moderate vagina stenosis
EUO/F 2.5 cm, F/C 3 cm 159.0 cm

11/10-93 freshening, dissection, transverse bladder/urethra closure with inverting chromic catgut, transverse avw closure with everting chromic catgut/3x supramid, FOLEY Ch 18, pack; free urine flow, moderate bladder capacity (EUO/BW 9 cm), good elevation, EUO/B 3 cm anesthetic
no pain whatsoever

25.10 + 07.11.93 not leaking at all cath removed bladder drill
13.11.93 not leaking at all, no incontinence, normal miction
insp/ healed, good elevation, no stress incontinence
28.11.93 not leaking at all, no incontinence, normal miction healed, no stress



1.5 cm

KANO

cath 265

auk (kano)

female

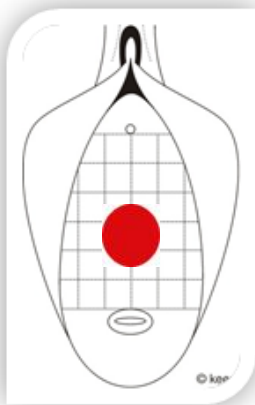
15 yr

11/10-93

diagnosis: PI, extensive \pm 1.5 cm 0 urethrovesicovaginal fistula **IIAb** with small circumferential defect, **leaking urine for 70 days** which started immediately following obstructed labor for 3 days, in hospital live male which died 2 days later, married 2 yr ago pre(menarche 1 mth later), not living with husband, no menstruation, drop foot R (grade 3-4) no RVF, moderate vagina stenosis poor_moderate general condition
 EUO/F 2 cm, F/C 1 cm 148.0 cm

11/10-93 freshening, dissection, transverse bladder/urethra closure by inverting chromic catgut, transverse avw closure by everting chromic catgut/3x supramid, FOLEY Ch 18, pack; free urine flow, moderate bladder capacity (EUO/BW 7 cm), good elevation, EUO/B 2.5 cm anesthetic nervous, but no pain

25.10 + 07.11.93 not leaking at all cath removed bladder drill
 13.11.93 not leaking, no incontinence, normal miction condition ok
 insp/ healed, good elevation, no stress incontinence
 23.12.93 not leaking at all, no incontinence, normal miction healed, no stress



1.5 cm

KANO

cath 266

fatk (kano)

female

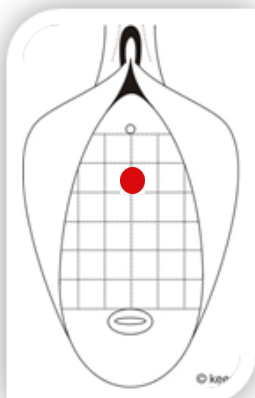
14 yr

11/10-93

diagnosis: PI, \pm 1 cm 0 urethrovesicovaginal fistula **IIAa** at midline, **leaking urine for 24 days** which started immediately following obstructed labor for 3 days, in hospital (eclampsia) SB male, married 1 yr 2 mth ago pre(menarche 3 mth later), not living with husband, no menstruation, drop foot R (grade 4) and L (grade 4), no RVF, still open episiotomy L
EUO/F 2 cm, F/C 6 cm 162.0 cm

11/10-93 freshening, dissection, transverse bladder/urethra closure with inverting chromic catgut, transverse avw closure with everting chromic catgut and 4x supramid, FOLEY Ch 18, vagina pack; free urine flow, good bladder capacity (EUO/BW 10 cm), good elevation, EUO/B 3 cm anesthetic only slight pain at avw closure

25.10 + 07.11.93 not leaking at all cath removed bladder drill
13.11.93 not leaking at all, no incontinence, normal miction
insp/ healed, good elevation, no stress incontinence
28.11 + 30.01.94 idem
27.03.94 not leaking at all, no incontinence, normal miction healed, no stress



1 cm

rkik (kano city)

female

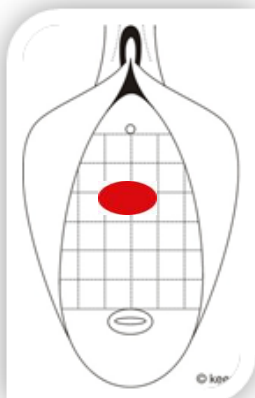
15 yr

18/10-93

diagnosis: PI, ± 2x1.5 cm 0 clean urethrovesicovaginal fistula **IIAa** at midline, **leaking urine for 27 days** which started 1 day following an obstructed labor for 2 days, in hospital SB male, married 2 yr ago post(menarche 3 mth earlier), not living with husband, no menstruation, drop foot R (grade 3), no RVF, slight/moderate vagina stenosis, open episiotomy L; when seen 11/10-93 at 20-day duration fistula still necrotic FOLEY Ch 18 EUO/F 2.5 cm, F/C 5 cm 158.0 cm

18/10-93 freshening, dissection, transverse bladder/urethra closure with inverting chromic catgut, transverse avw closure with everting chromic catgut and 4x supramid, FOLEY Ch 18, pack; free urine flow, good bladder capacity (EUO/BW 11 cm), good elevation, EUO/B 4 cm anesthetic only slight pain at R paraurethral avw suture 1x

25.10 + 13.11.93 not leaking at all cath removed bladder drill
 21.11.93 not leaking at all, no incontinence, normal miction
 insp/ healed, good elevation, no stress incontinence
 23.01.94 not leaking at all, no incontinence, normal miction healed, no stress



2x1.5 cm

sjbs (kano city)

female

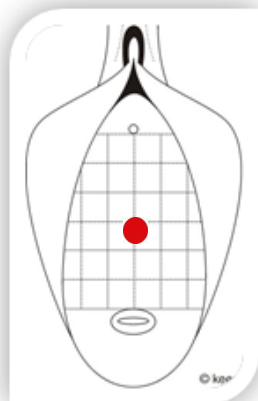
15 yr

18/10-93

diagnosis: PI, \pm 1 cm 0 "clean" vesicovaginal fistula I midline bladder base **leaking urine for 6 days** which started immediately following an obstructed labor for 2 days, in hospital SB male, married 3 yr ago pre(menarche 1 yr later), not living with husband, no RVF, no menstruation, drop foot R (grade 3) and L (grade 4); slight/ moderate vagina stenosis
 EUO/F 6 cm, F/C 4 cm 150.0 cm

18/10-93 freshening, dissection, transverse bladder closure by inverting chromic catgut, transverse avw closure by everting chromic catgut and 3x supramid FOLEY Ch 18, pack; free flow of urine, good bladder capacity (EUO/BW 12 cm), good elevation, EUO/B 4 cm anesthetic
almost at the end of the procedure the pt asked when the doctor would start because she was waiting for it!!

31.10 + 13.11.93 not leaking at all cath removed bladder drill
 21.11.93 not leaking at all, no incontinence, normal miction
 insp/ healed, good elevation, no stress incontinence
 28.11 + 09.01 + 06.03.94 idem pat started to menstruate
 01.05.94 not leaking at all, no incontinence, normal miction healed, no stress



1 cm

aywl (kano city)

female

16 yr

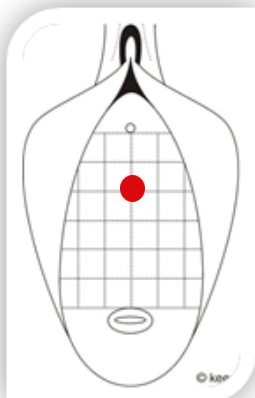
17/10-93

diagnosis: PI, urethrovesicovaginal fistula, leaking urine for 7 mth which started immediately following obstructed labor for 2 days, at home SB male, married 3 yr ago post(menarche 2 mth earlier), not living with husband, no menstruation, bilateral drop foot for 3 mth (R now grade 5, L still grade 4), no RVF
NB indwelling catheter for over 6 mth!?!; now not leaking, but incontinence \pm , normal micurition catheter removed

24/10-93 not leaking, no incontinence, normal micturition bladder drill
insp/ healed \pm 1 cm 0 avw with granulations type **IIAa**, no stress inconti-
nence, good elevation
EUO/F? 3 cm, F?/C 6 cm 148.0 cm

21.11.94 not leaking at all, no incontinence, normal miction
insp/ healed, good elevation, no stress incontinence

24.01.94 not leakimng at all, no incontinence, normal miction healed, no stress



1 cm

amgd (kano city)

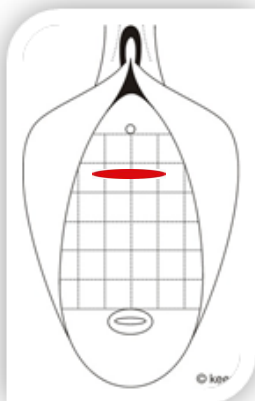
female 15 yr

24/10-93

diagnosis: PI, \pm 2.5x0.2 cm necrotic/traumatized avw **IIAa** over UV-junction with stress incontinence ++, **leaking urine for 9 days which started 6 days** following vacuum extraction bco obstructed labor for 1 day, live male, married 1 yr ago post(menarche 1 yr earlier), not living with husband, no menstruation, no h/o drop foot, no RVF; stress incontinence ++
EUO/AVWT 2 cm, AVWT/C 6 cm 150.0 cm

24/10-93 FOLEY Ch 18; free urine flow, bladder full but not overfilled, good bladder capacity (EUO/BW 11 cm), good elevation, EUO/B 2.5 cm

07.11 + 21.11.93 cath out x 1/7 not leaking at all bladder drill
23/11-93 not leaking, no incontinence, normal miction
insp/ healed, good elevation, no stress incontinence



2.5x0.2 cm

KANO

cath 271

multiple obstetric necrotic + cs fistula

mak (kano city) female 17 yr 18/10-93

diagnosis: PII (1 alive), ± 2 cm 0 necrotic urethrovesicovaginal fistula L bladder neck **IIAa, leaking urine for 14 days** which started immediately following removal of catheter (for 7 days) after CS b.c.o. obstructed last labor for 1 day, live male which died 9 days later, married 4 yr ago post(menarche 2 mth earlier), not living with husband, no menstruation, no h/o drop foot, no RVF
EUO/F 3 cm 152.0 cm

18/10-93 FOLEY Ch 18; EUO/BW 14 cm, good elevation, EUO/B 3 cm; prepare for early closure next week

25/10-93 insp/ **completely healed**

still some leakage; further inspection reveals 2 cm 0 **CS-fistula as well**; for repair under spinal

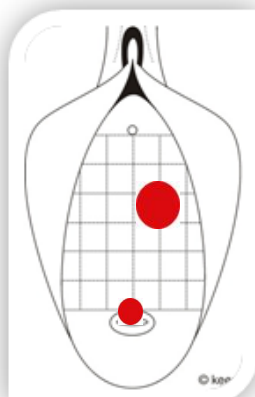
26/10-93 operation: CS_VCVF-repair vvf 677

09.11 + 21.11.93 not leaking at all cath removed bladder drill

28.11.93 not leaking at all, no incontinence, normal miction
insp/ **both** healed, good elevation, no stress incontinence

15.12 + 20.02 + 24.04.94 idem

26.06.94 not leaking at all, no incontinence, normal miction **both** healed, no stress



multiple fistulas

KANO

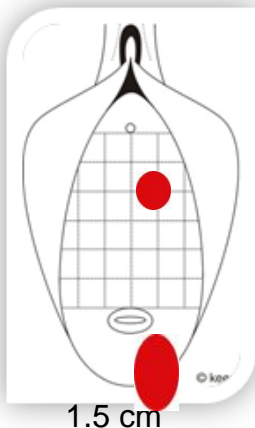
cath 272
RVF

sdgwr (kano city) female 15 yr 25/10-93

diagnosis: PI, "clean" ± 1.5 cm 0 urethrovesicovaginal fistula **IIAa** slightly at L, **leaking urine for 12 days** which started immediately following obstructed labor for 2 days, in hospital SB male, married 2 yr ago pre(menarche 3 mth later), not living with husband, no menstruation, drop foor R (grade 2-3) and L (grade 4), no RVF; open episiotomy L, further traumatized avw/distal pvw (no fistula?)
EUO/F 2 cm, F/C 8 cm, I/F 0 cm 145.0 cm

25/10-93 freshening, dissection, transverse bladder/urethra closure with inverting chromic catgut, transverse avw closure with everting chromic catgut and 3x supramid, FOLEY Ch 18, pack; free urine flow, good bladder capacity (EUO/BW 11 cm), moderate elevation, EUO/B 3.5 cm anesthetic normal bladder capacity (longitudinal diameter 11-3.5 = 7.5 cm)
too early??

07.11 cath out reinserted 21.11.93 not leaking at all cath removed drill
28.11.93 not leaking at all, no incontinence, normal miction
insp/ healed, good elevation, no stress incontinence
22.12 + 30.01.94 idem
15.05.94 not leaking at all, no incontinence, normal miction healed, no stress



KANO

cath 273

aakw (kano city)

female

15 yr

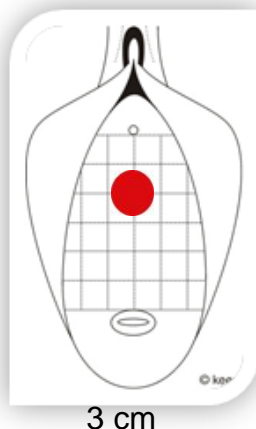
24/10-93

diagnosis: PI, necrotic \pm 3 cm 0 urethrovesicovaginal fistula at midline bladder neck
IIAa, leaking urine for 16 days which started immediately following obstructed labor for 3 days, in hospital (eclampsia) live female, married 3 yr ago pre(menarche 1 yr later), not living with husband, no h/o drop foot, no menstruation, no RVF, open episiotomy R
EUO/F 2 cm, F/C 6 cm 154.0 cm

24/10-93 FOLEY Ch 18; later for early closure

1/11-93 now clean \pm 1 cm 0 urethrovesicovaginal fistula midline bladder neck, EUO/F 2 cm, F/C 6 cm anesthetic freshening, dissection, transverse bladder/urethra closure with inverting chromic catgut, transverse avw closure with everting chromic catgut and 3x supramid, FOLEY Ch 18, vagina pack; free flow of urine, EUO/BW 11 cm, good elevation, EUO/B 2.5 cm
normal bladder capacity (11-2.5 = 8.5 cm) nervous but no pain

21.11 + 15.12.93 not leaking at all cath removed bladder drill
22.11.93 not leaking, incontinence +, normal miction healed, stress +
05.01.94 not leaking, incontinence \pm , normal miction healed, stress \pm
20/03-94 not leaking at all, no incontinence, normal miction
insp/ healed, good elevation, no stress incontinence



KANO

cath 274

smsgs (kano city)

female

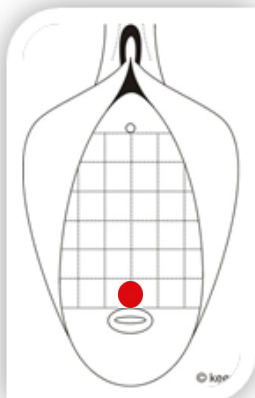
31 yr

01/11-93

diagnosis: PVII (0 alive), \pm 5 mm 0 vesicovaginal fistula midline bladder base in front of cervix I, **leaking urine for 22 days which started 9 days** following obstructed last labor for 2 days, at home SB female, married 20 yr ago pre(menarche 1.5 yr later), still living with husband, no menstruation, no h/o drop foot, no RVF
EUO/F 7 cm, F/C 0 cm 155.0 cm

01/11-93 transverse incision through fistula, dissection, a transverse bladder closure of 1 cm 0 defect with inverting chromic catgut, transverse avw closure with 3x everting supramid, FOLEY Ch 18, vagina pack; free urine flow, EUO/BW 8 cm, moderate elevation, EUO/B 3 cm anesthetic moderate bladder capacity (8-3 = 5 cm 0) no pain whatsoever

13.11 + 28.11.93 not leaking at all cath removed bladder drill
08.12.93 not leaking at all, no incontinence, normal miction
insp/ healed, moderate elevation, no stress incontinence
22.12.93 not leaking at all, no incontinence, normal miction healed, no stress



0.5 cm

KANO

cath 275

mss (kano)

female

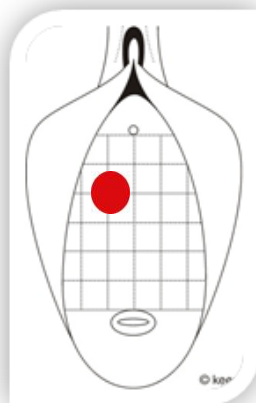
24 yr

01/11-93

diagnosis: PIII (2 alive), \pm 1.5 cm 0 urethrovesicovaginal fistula fixed to R symphysis with urethra block **IIAb, leaking urine for 43 days which started 7 days** upon removal of catheter following CS b.c. o. obstructed last labor for 2 days, SB male, married 12 yr ago pre(menarche 1 yr later), still living with husband, drop foot R (grade 3) and L (grade 3), no menstruation, no RVF EUO/F 2 cm 154.0 cm

01/11-93 freshening, dissection, deblocking, transverse bladder/urethra closure with inverting chromic catgut, transverse avw closure by everting chromic catgut and 4x supramid, FOLEY Ch 20, pack; free flow of urine, EUO/BW 11 cm, good elevation, EUO/B 3 cm anesthetic cervix cannot be visualized, too high up fixed intraabdominally, another fistula???
normal bladder capacity (11-3 = 8 cm 0)

13.11 + 28.11.93 not leaking at all cath removed bladder drill
08.12.93 not leaking, incontinence +, normal miction healed, stress
22.12.93 not leaking at all, no incontinence, normal miction healed, stress +
20/03-94 not leaking at all, no incontinence, normal miction
insp/ healed, good elevation, no stress incontinence



1.5 cm

KANO

cath 276

andk (kano city)

female

31 yr

24/10-93

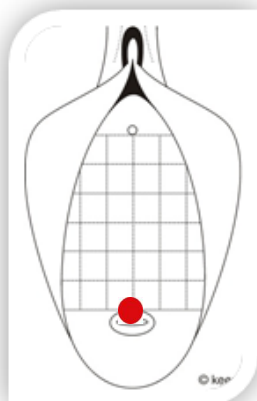
diagnosis: PI (0 alive), \pm 5 mm 0 vesicovaginal fistula I midline at vagina vault, **leaking urine for 66 days which started 24 days** following total abdominal hysterectomy (private hospital ZARIA), married 20 yr ago pre(menarche 2 yr later), not living with husband, no RVF
EUO/F 10 cm, F/V 0 cm 162.0 cm

24/10-93 FOLEY Ch 18; free flow of urine, EUO/BW 11 cm, good elevation, EUO/B 3 cm normal bladder capacity (11-3 = 8 cm 0)

1/11-93 not leaking at all; gv: no leakage

15/11-93 100 ml gv: no leakage but urine in vaginae ureter fistula?

15/12-93 leaking & normal miction
insp/ **dry!; healed, good elevation, no stress incontinence**



0.5 cm

KANO

cath 277
RVF

zgr (kano) female 15 yr 26/10-93

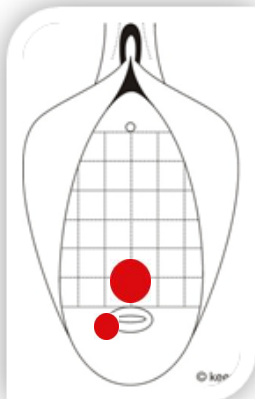
diagnosis: PI, \pm 2 cm 0 necrotic vesicocervicovaginal fistula I and \pm 2 cm 0 necrotic pvw at R cervix, **leaking urine for 15 days which started 5 days** (upon removal of catheter) following CS b.c.o. an obstructed labor for 2 days, a live male which died same day, married 2 yr ago pre(menarche 5 mth later), not living with husband, no menstruation, no h/o drop foot
EUO/F 8 cm, F/C 0 cm 149.0 cm

26/10-93 FOLEY Ch 18; free flow of urine, EUO/BW 10 cm, good elevation, EUO/B 3 cm; later for early closure
normal bladder capacity (10-3 = 7 cm 0)

1/11-93 gv: leakage from cervix

13/11-93 catheter out x 1 day leaking ++ & normal miction Ch 18
stools ok pvw healed

28/11-93 not leaking at all catheter removed bladder drill



2 cm

shsmf (katsina)

female

37 yr

07/11-93

diagnosis: PX (5 alive), ± 5x1 cm longitudinal necrotic avw **IIBa** necrosis bladder neck/urethra, **leaking urine for 6 days which started 1 day** following obstructed last labor for 1 day, at home SB female, married 25 yr ago pre(menarche 1 yr later), not living with her husband, no menstruation, no h/o drop foot, no RVF; on examination stress incontinence ++
EUO/AVWN 1 cm 151.0 cm

7/11-93 FOLEY Ch 18; free urine flow, EUO/BW 11 cm, moderate elevation, EUO/B 3 cm normal bladder capacity (11-3 = 8 cm 0) will it heal or will it become a fistula?? **documented**

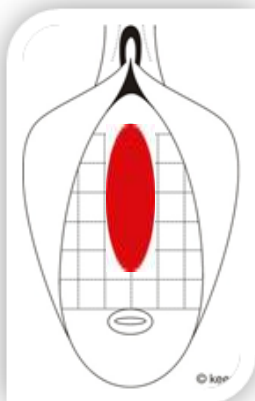
22/11-93 **now 1 cm 0 VVF** at 5 cm from EUO within a 5 cm avw defect up to cervix; portion over urethra has healed anesthetic freshening, dissection, longitudinal bladder closure by inverting chrom ic catgut, longitudinal avw closure by 4x everting supramid, FOLEY Ch 18, pack; free urine flow, EUO/BW 11 cm, good elevation, EUO/B 3 cm normal bladder capacity (longitudinal diameter 11-3 = 8 cm)

08.12 + 22.11.93 not leaking at all cath removed bladder drill

05.01.94 not leaking at all, no incontinence, normal miction insp/ healed, good elevation, no stress incontinence

17.01.94 idem

28.01.94 not leaking at all, no incontinence, normal miction healed, no stress



5x1 cm

bkad (kano city)

female

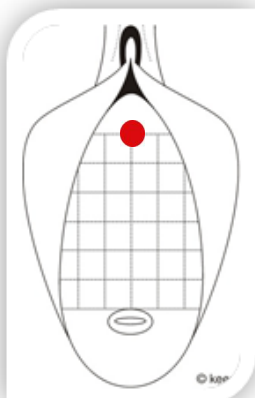
16 yr

13/11-93

diagnosis: PI, urine stress incontinence, **leaking urine for 10 days which started 20 days** following obstructed labor for 2 days, in hospital SB male, married 3 yr ago pre(menarche 3 mth later), not living with husband, no menstruation, drop foot R (grade 4), no RVF; normal micturition as well 158.0 cm

13/11-93 FOLEY Ch 18; free urine flow, EUO/BW 10 cm, moderate elevation, EUO/B 3 cm normal bladder capacity (10-3 = 7 cm 0)

28.11 + 08.12.93 not leaking at all cath removed bladder drill
15.12.93 not leaking at all, no incontinence, normal miction
insp/ healed, good elevation, no stress incontinence
30.01.94 idem
28.01.94 not leaking at all, no incontinence, normal miction healed, no stress



KANO

cath 280

askw (kano city)

female

35 yr

22/11-93

diagnosis: PV (3 alive), total urine incontinence, normal micturition and **leaking always for 9 days** which started immediately following obstructed labor for 3 days, in hospital (eclampsia) live male, married 22 yr ago post(menarche 3 mth earlier), not living at husband, no menstruation, no drop foot, no RVF; NB avw over urethrocele traumatized 154.0 cm

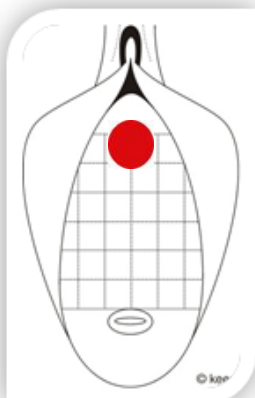
22/11-93 FOLEY Ch 18; free urine flow, EUO/BW 11 cm, no elevation (urethrocele), EUO/B 3 cm stress incontinence demonstrated!
normal bladder capacity (11-3 = 8 cm 0)

09.01.94 not leaking at all cath removed bladder drill

17.01.94 not leaking at all, no incontinence, normal miction
insp/ healed, moderate elevation, no stress incontinence

27.02 + 03.04 + 01.05,94 idem

26.06.94 not leaking at all, no incontinence, normal miction healed, no stress



KANO

cath 281

hrydb (kano)

female

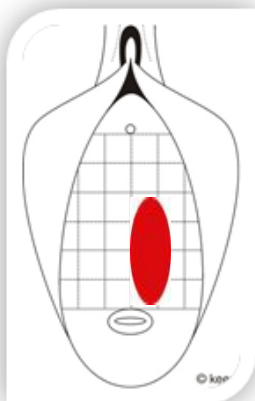
32 yr

10/01-94

diagnosis: PVIII (5 alive), \pm 2 mm 0 vesicovaginal fistula **IIAa** within 5x1.5 cm avw trauma at L, **leaking urine for 4 days which started 25 day!** following CS b.c.o. obstructed last labor for 2 days, SB male, married 20 yr ago pre(menarche 1 yr later), still living with husband, no menstruation, drop foot R (grade 3) and L (grade 4) no RVF
EUO/AVW 3 cm, AVW/C 0 cm 154.0 cm

10/01-94 freshening, minimal dissection, a longitudinal bladder closure by inverting chromic catgut, longitudinal avw closure by everting chromic catgut/4x supramid, FOLEY Ch 18, pack; free urine flow, EUO/BW 8 cm, moderate elevation, EUO/B 3 cm anesthetic
moderate bladder capacity (8-3 = 5 cm) no pain whatsoever

31.01 + 06.02.94 not leaking at all cath removed bladder drill
20.02.94 not leaking at all, no incontinence, normal miction
insp/ healed, moderate elevation, no stress incontinence
07.03 + 03.04 + 15.05.94 idem
10.07.94 not leaking at all, no incontinence, normal miction healed, no stress



5x1.5 cm

KANO

cath 282

hjmfs (kano) female 37 yr 10/01-94

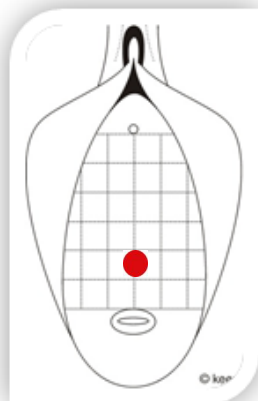
diagnosis: PXI (2 alive), \pm 1 cm 0 vesicovaginal fistula I midline bladder base, **leaking urine for 7 days which started 27 days!** following obstructed last labor for 1 day, at home a live male which died same day, married 25 yr ago pre(menarche 9 mth later), still living with husband, no menstruation, no h/o drop foot, no RVF
EUO/F 6 cm, F/C 2 cm 155.0 cm

10/01-94 freshening, dissection, transverse bladder closure by inverting chromic catgut, transverse avw closure by everting chromic catgut/4x supramid FOLEY Ch 18, vagina pack; a free flow of urine, EUO/BW 10 cm, good elevation, EUO/B 4 cm nervous but no pain whatsoever moderate bladder capacity (10-4 = 6 cm) anesthetic

17.04.94 not leaking at all, no incontinence, normal miction
insp/ healed, good elevation, no stress incontinence

29.05.94 idem

10.07.94 not leaking at all, no incontinence, normal miction healed, no stress



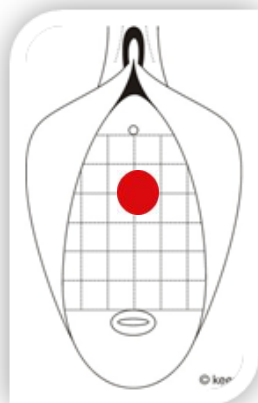
1 cm

hsnmd (kano) female 15 yr 16/01-94

diagnosis: PI, necrotic \pm 2 cm 0 urethrovesicovaginal fistula at midline bladder neck **IIAa** (with seeping through), **leaking for 7 days** which started immediately following obstructed labor for 6 days, in hospital SB male, married 2.5 yr ago pre(menarche 5 mth later), not living with husband, no menstruation, no RVF, drop foot L (grade 3); bilateral pressure ulcers over buttocks
EUO/F 2.5 cm, F/C 5 cm 153.0 cm

16/1-94 FOLEY Ch 18; free urine flow, EUO/BW 13 cm, moderate elevation, EUO/B 3 cm, will it heal spontaneously??
normal bladder capacity (13-3 = 10 cm)

30.01 not leaking 20.02.94 cath out x 2/7 not leaking at all, normal miction
28.02.94 not leaking at all, no incontinence, normal miction
insp/ healed, good elevation, no stress incontinence
08.04 + 29.05.94 idem
03.07.94 not leaking at all, no incontinence, normal miction healed, no stress



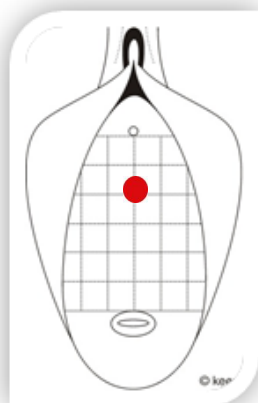
2 cm

jyps (plateau) female 18 yr 17/01-94

diagnosis: PI, ± 1 cm 0 urethrovesicovaginal fistula with circumferential defect **IIAb**, **leaking urine for 35 days** which started 1 day following obstructed labor for 3 days, in hospital SB male, married 16 mth ago post(menarche 4 yr earlier), not living with husband, no menstruation, drop foot R (grade 4) and L (grade 3), passing stools as well?? small proximal rvf, narrow pubic angle, moderate vagina stenosis; pat finished form 3 at secondary school
EUO/F 2 cm, F/C 5 cm 143.0 cm

17/01-94 freshening, dissection, transverse bladder/urethra closure with inverting chromic catgut, transverse avw closure with everting chromic catgut and 3x supramid, FOLEY Ch 18, vagina pack; free flow of urine, EUO/BW 10 cm, good elevation, EUO/B 3 cm anesthetic
normal bladder capacity (10-3 = 7 cm) nervous but no pain!

31.01 + 20.02.94 not leaking at all cath removed bladder drill
27.02.94 not leaking at all, no incontinence, normal miction
insp/ healed, good elevation, no stress incontinence
30.03.94 not leaking at all, no incontinence, normal miction healed, no stress



1 cm

hauu (kano city)

female

14 yr

17/01-94

diagnosis: PI, necrotic \pm 6 mm 0 urethrovesicovaginal fistula **IIAa** at L bladder neck (seeping through), **leaking urine for 15 days which started 7 days** following vacuum extraction b.c.o. obstructed labor for 1 day, SB female, married 1 yr ago post(menarche 1 mth earlier) not living with husband, no menstruation, drop foot R (grade 3) and L (grade 4), no RVF
 EUO/F 2 cm, F/C 7 cm 150.0 cm

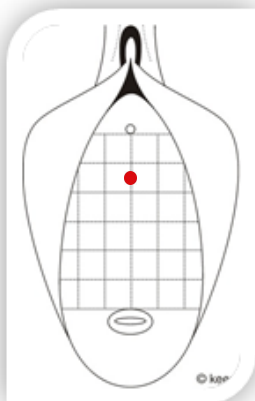
17/01-94 FOLEY Ch 18; free urine flow, EUO/BW 10 cm, moderate elevation, EUO/B 2.5 cm probably it will heal spontaneously
 normal bladder capacity (10-2.5 = 7.5 cm)

27.02.94 not leaking at all healed cath removed bladder drill

14.03.94 not leaking at all, no incontinence, normal miction
 insp/ healed, good elevation, no stress incontinence

10.04 + 09.05.94 idem

03.07.94 not leaking at all, no incontinence, normal miction healed, no stress



0.6 cm

KANO

cath 287

hmb (kano)

female

16 yr

17/01-94

diagnosis: PI, extensive \pm 3x2 cm urethrovesicovaginal fistula **IIAa** midline/L bladder neck, **leaking urine for 24 days** which started immediately following CS (24/12-93) b.c.o. obstructed labor for 2 days a SB male, married 3 yr ago post(menarche 2 mth earlier), not living with husband, no menstruation, no h/o drop foot, no RVF; slight vagina stenosis
 EUO/F 2 cm, F/C 3 cm 148.0 cm

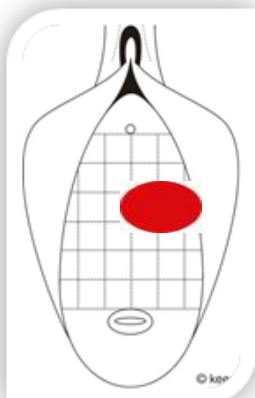
17/01-94 freshening, dissection, transverse bladder/urethra closure with inverting chromic catgut, transverse avw closure with everting chromic catgut and 4x supramid, FOLEY Ch 18, vagina pack; free urine flow, EUO/BW 8 cm, good elevation, EUO/B 3 cm anesthetic
 moderate bladder capacity (8-3 = 5 cm) no pain whatsoever

20.02.94 not leaking at all cath removed bladder drill

27.02.94 not leaking at all, no incontinence, normal miction
 insp/ healed, good elevation, no stress incontinence

14.03 + 17.04 + 29.05.94 idem

10.07.94 not leaking at all, no incontinence, normal miction healed, no stress



3x2 cm

KANO

cath 288
rvf

hgmf (katsina) female 14 yr 16/01-94

diagnosis: PI, necrotic \pm 2.5 cm 0 vesicovaginal fistula **IIAa** midline bladder neck, **leaking urine for 13 days** which started immediately following obstructed labor for 1 days, in hospital SB female, married 2 yr ago pre(menarche 1 yr later), still living with husband, no menstruation, no h/o drop foot, no RVF, open episiotomy midline
EUO/F 4 cm, F/C 3 cm 149.0 cm

16/01-94 extirpation of necrosis, FOLEY Ch 18, next week for early closure

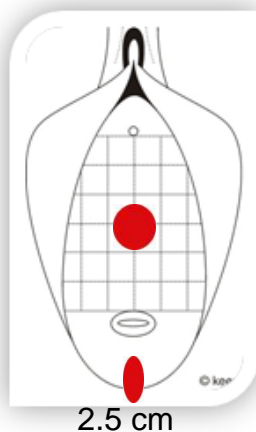
23/1-94 now clean \pm 2.5 cm vesicovaginal fistula anesthetic freshening, dissection, transverse bladder/urethra closure with inverting chromic catgut, transverse avw closure with everting chromic catgut and 5x supramid, FOLEY Ch 18, vagina pack; free flow of urine, EUO/BW 11 cm, good elevation, EUO/B 3 cm slight pain at paraurethral avw closure normal bladder capacity (11-3 = 8 cm)

30.01 + 20.02.94 not leaking at all cath removed bladder drill

27.02.94 not leaking at all, no incontinence, normal miction insp/ healed, good elevation, no stress incontinence

27.03 + 29.05.94 not leaking at all

09.10.94 not leaking at all, no incontinence, normal miction healed, no stress



KANO

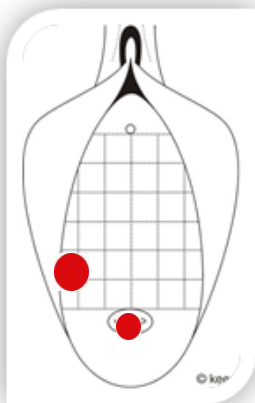
cath 289
rvf

hgbk (kano city) female 25 yr 25/01-94

diagnosis: PVI (5 alive), ± 1.5 cm **necrotic** vesicovaginal fistula R bladder base I, **leaking urine for 2 days which started 12 days** following obstructed last labor for 2 days, in hospital live male, married 13 yr ago pre(menarche 6 mth later), still living with husband, no h/o drop foot, no RVF but **necrotic** ± 2 cm 0 pvw at cervix; **avw/bladder wall indurated**
EUO/F 8 cm, F/C 1 cm 150.0 cm

25/01-94 FOLEY Ch 18; free urine flow, EUO/BW 13 cm, no elevation, EUO/B 4 cm; will it heal spontaneously?
normal bladder capacity (13-4 = 9 cm)

- 20.02.94 not leaking at all cath removed bladder drill
- 28.02.94 now leaking x 4/7 following abd pain foley ch 18
- 06.03 + 20.03.94 not leaking at all gv/ healed cath removed blad drill
- 03.04.94 not leaking at all, no incontinence, normal miction
insp/ **both** healed, good elevation, no stress incontinence
- 01.05 + 18.06.94 idem
- 31.07.94 not leaking at all, no incontinence, normal miction healed, no stress



1.5 cm

jdlk (kano city)

female

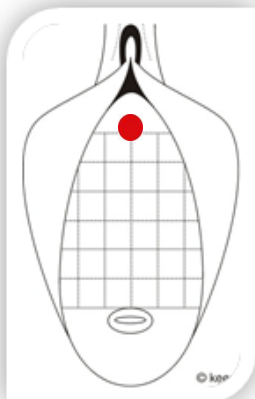
14 yr

31/01-94

diagnosis: PI, stress incontinence, **leaking now when standing walking but not when sitting/lying unless coughing (before leaking always; atonic bladder in healing phase?) for 58 days** which started immediately following an obstructed labor for 2 days, in hospital (eclampsia) live female, married 1 yr ago pre(menarche 2 mth later), not living with husband, no menstruation, no h/o drop foot, no RVF 150.0 cm

31/01-94 FOLEY Ch 18; free urine flow (full bladder but not overdistended!), EUO/BW 12 cm, moderate elevation, EUO/B 4 cm
normal bladder capacity (12-4 = 8 cm)

20.02.94 cath out x 2/7 not leaking at all, no incontinence, miction
06/03-94 not leaking at all, no incontinence, normal miction
insp/ healed, moderate elevation, no stress incontinence



KANO

cath 291

mabm (kano) female 17 yr 31/01-94

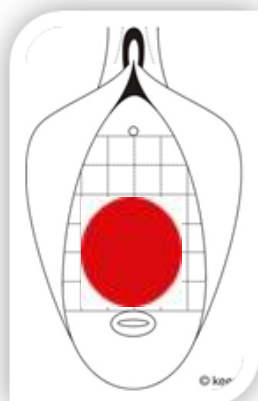
diagnosis: PIII (0 alive), ± 3 mm 0 urethrovesicovaginal fistula **IIAa** at top of ± 4 cm 0 avw trauma, **leaking urine for 13 days** which started im mediately following obstructed last labor for 1 day, at home SB male, married 5 yr ago pre(menarche 1 yr later), still living with husband, no menstruation, no h/o drop foot, no RVF
EUO/F 2.5 cm, F/C 4 cm 148.0 cm

31/01-94 transverse incision thru fistula, dissection, transverse bladder/urethra closure by inverting chromic catgut, transverse avw closure with everting chromic catgut/3x supramid, FOLEY Ch 18, vagina pack; free flow of urine, EUO/BW 11 cm, good elevation, EUO/B 3 cm anesthetic normal bladder capacity (11-3 = 8 cm) no pain whatsoever

20.02 + 28.02.94 not leaking at all cath removed bladder drill
06.03.94 not leaking at all, no incontinence, normal miction insp/ healed, good elevation, no stress incontinence
27.03 + 01.05.94 idem
05.06.94 not leaking at all, no incontinence, normal miction healed, no stress

second obstetric fistula completely ok until PIV (0 alive) SB female by CS
05.09.95 operation: UVVF-repair vvf 1118
not leaking at all

new fistula seems yankan gishiri
03.11.98 operation: urethra/closure/suspension vvf 1789
16.10.98 leaking & miction pat **not** drinking healed, stress + bladder drill
29.01.01 **??another yankan gishiri??** for urethra/avw



4 cm

midn (kano city)

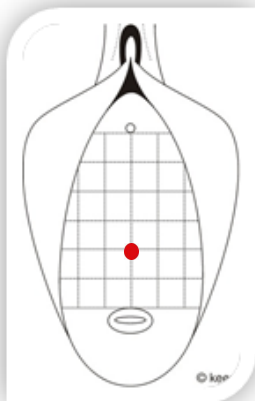
female 15 yr

20/02-94

diagnosis: PI, stress incontinence grade III, **leaking always day/night when lying down (little)/sitting/standing/walking (no micturition) of 36 days** which started immediately following obstructed labor for 2 days, in hospital (eclampsia) live male by vacuum extraction, married 2 yr ago pre(menarche 2 mth later), not living with husband, no menstruation, no h/o drop foot, no RVF; \pm 3 mm 0 avw trauma midline bladder neck **IIAa**
 EUO/AVT 5 cm, AVT/C 2 cm 148.0 cm

20/02-94 FOLEY Ch 18; a free urine flow \pm , EUO/BW 7 cm, no elevation and EUO/B 3 cm
 moderate bladder capacity (7-3 = 4 cm) later for gv!

06.03 + 27.03,94 not leaking at all cath removed bladder drill
 10.04.94 not leaking, incontinence +, normal miction healed, stress +
 29.05.94 not leaking at all, no incontinence, normal miction
 insp/ healed, moderate elevation, no stress incontinence
 31.07.94 not leaking at all, no incontinence, normal miction healed, no stress



0.3 cm

KANO

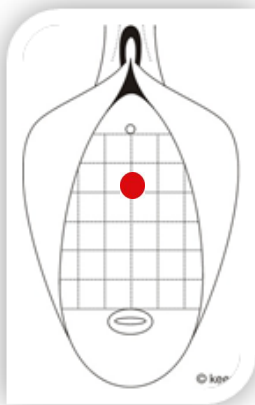
cath 293

hrag (kano) female 36 yr 28/02-94

diagnosis: PXII (6 alive), \pm 1 cm o urethrovesicovaginal fistula **IIAa** midline, **leaking urine for 54 days** which started immediately following obstructed last labor for 1 day, at home SB female, married 25 yr ago pre(menarche 1.5 yr later), not living with husband, no menstruation, drop foot L (grade 3), no RVF
EUO/F 2 cm, F/C 4 cm 145.0 cm

28/02-94 freshening, dissection, transverse bladder/urethra closure with inverting chromic catgut, transverse avw closure with everting chromic catgut and 3x supramid, FOLEY Ch 18, vagina pack; free flow of urine, EUO/BW 11 cm, good elevation, EUO/B 3 cm anesthetic
normal bladder capacity (11-3 = 8 cm) no pain whatsoever

20.03 + 27.03.94 not leaking at all cath removed bladder drill
17.04.94 not leaking at all, no incontinence, normal miction
insp/ healed, good elevation, no stress incontinence
30.05.94 idem
31.07.94 not leaking at all, no incontinence, normal miction healed, no stress



1 cm

hsrz (kano city)

female

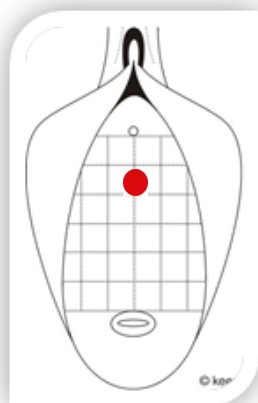
14 yr

28/02-94

diagnosis: PI, \pm 0.5 cm 0 urethrovesicovaginal fistula **IIAa** at midline, **leaking urine for 66 days** which started immediately following obstructed labor for 2 days, in hospital (eclampsia) SB female, married 1 yr ago post(menarche 1 mth earlier), not living with her husband, no menstruation, drop foot R (grade 2) and L (grade 4) no RVF, narrow pubic angle and narrow introitus (bilateral epi)
 EUO/F 2.5 cm, F/C 6 cm 155.0 cm

28/02-94 freshening, dissection, transverse bladder/urethra closure with inverting chromic catgut, transverse avw closure with everting chromic catgut and 3x supramid, FOLEY Ch 18, vagina pack; free flow of urine, EUO/BW 10 cm, good elevation, EUO/BW 3 cm anesthetic
 normal bladder capacity (10-3 = 7 cm) difficult, no pain whatsoever

20.03 + 27.03.94 not leaking at all cath removed bladder drill
 03.04.94 not leaking at all, no incontinence, normal miction
 insp/ healed, good elevation, no stress incontinence
 17.04 + 18.06 + 14.08.94 idem
 11.09.94 not leaking at all, no incontinence, normal miction healed, no stress



0.5 cm

fmg (plateau)

female

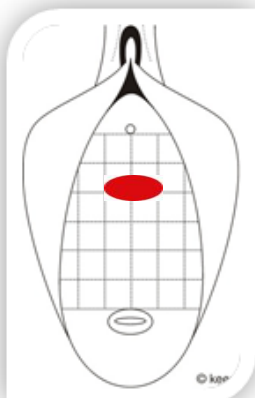
16 yr

28/02-94

diagnosis: PI, ± 2x1 cm urethrovesicovaginal fistula with circumferential defect **IIAb**, **leaking urine for 55 days which started 4 days** following obstructed labor for 2 days, in hospital SB female, married 1 yr ago post(menarche 1.5 yr earlier), not living with husband no menstruation, drop foot R (grade 4) and L (grade 4), no RVF; narrow pubic angle and pvw stricture
 EUO/F 1.5 cm, F/C 4 cm 145.0 cm

28/02-94 freshening, dissection, transverse bladder/urethra closure with inverting chromic catgut (circumferential repair would be too complicated), transverse avw closure by everting chromic catgut 4x supramid, FOLEY Ch 18, pack; free urine flow, EUO/BW 10 cm, good elevation, EUO/B 2 cm
 normal bladder capacity (10-2 = 8 cm) anesthetic
 slight pain at paraurethral avw closure

20.03 + 27.03-.94 not leaking at all cath removed bladder drill
 03.04.94 not leaking at all, no incontinence, normal miction
 insp/ healed, good elevation, no stress incontinence
 17.04.94 not leaking at all, no incontinence, normal miction healed, no stresses



2x1 cm

usaps (kano city)

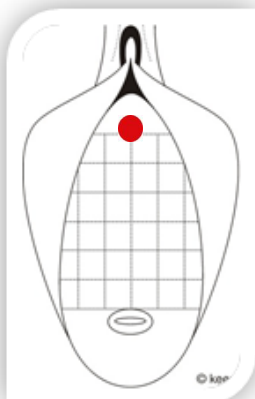
female 19 yr

06/03-94

diagnosis: PI, stress incontinence grade I, **leaking urine whilst standing up/on cough (first 2 wk leaking day/night when lying/sitting/ standing/ walking) for 28 days** which started immediately following obstructed labor for 2 days, in hospital SB male, married 7 yr ago pre(menarche 6 mth later), not living with her husband no menstruation, drop foot R (grade 3) and L (grade 2), no RVF, stress incontinence demonstrated by cough
153.0 cm

06/03-94 FOLEY Ch 18; a free urine flow, EUO/BW 10 cm, no elevation at all, EUO/B 3 cm
normal bladder capacity (10-3 = 7 cm)

20.03 + 05.04.94 not leaking at all cath removed bladder drill
17.04.94 not leaking at all, no incontinence, normal miction
insp/ healed, **good** elevation, no stress incontinence
24.04 + 29.05 + 08.08.94 idem
18.09.94 not leaking at all, no incontinence, normal miction healed, no stress



KANO

cath 297

bhg (kano)

female

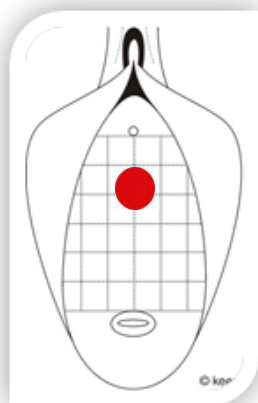
33 yr

07/03-94

diagnosis: PIII (1 alive), \pm 2 cm 0 urethrovesicovaginal fistula **IIAb** with circumferential defect, **leaking urine of 29 days** which started immediately following obstructed last labor for 3 days, in hospital SB male, married 20 yr ago pre(menarche 2 mth later), not living with husband, no menstruation, no h/o drop foot, no RVF; slough removed on 20/2-94
EUO/F 2 cm, F/C 5 cm, AB/AU 0.5 cm 152.0 cm

07/03-94 incision at fistula edge, dissection, transverse bladder/urethra closure by inverting chromic catgut, transverse avw closure by 5x everting supramid, FOLEY Ch 18, vagina pack; free flow of urine, EUO/BW 12 cm, good elevation, EUO/B 4 cm normal anesthetic
bladder capacity (12-4 = 8 cm)
only slight pain at paraurethral avw closure!

27.03 + 03.04.94 not leaking at all cath removed bladder drill
17.04.94 not leaking at all, no incontinence, normal miction
insp/ healed, good elevation, stress incontinence \pm
25.04 + 01.05 + 15.05 + 12.06.94 idem
09.10.94 not leaking at all, no incontinence, normal miction healed, no stress



2 cm

hagd (kano city)

female

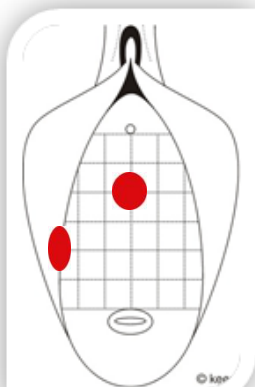
14 yr

07/03-94

diagnosis: PI, \pm 1.5 cm 0 urethrovesicovaginal fistula midline **IIAa**, 1.5x0.5 cm necrotic avw R lateral side, **leaking of urine for 21 days** which started immediately following an obstructed labor for 1 day, in hospital SB male, married 1 yr ago post(menarche 3 mth earlier) not living with husband, no menstruation, no h/o drop foot (but L grade 4-5), no RVF
 EUO/F 2 cm, F/C 5 cm 150.0 cm

07/03-94 freshening, dissection, transverse bladder/urethra closure with inverting chromic catgut, transverse avw closure with everting chromic catgut and 4x supramid, FOLEY Ch 18, vagina pack; free flow of urine, EUO/BW 10 cm, good elevation, EUO/B 3 cm anesthetic
 normal bladder capacity (10-3 = 7 cm)

27.03 + 03.04.94 not leaking at all cath removed bladder drill
 17.04.94 not leaking at all, no incontinence, normal miction
 insp/ healed, good elevation, no stress incontinence
 24.04 + 09.05 + 29.05 + 24.07.94 idem
 25.09.94 not leaking at all, no incontinence, normal miction healed, no stress



multiple trauma

KANO

cath 299

mabk (kano)

female

16 yr

14/03-94

diagnosis: PI, ± 1 cm 0 urethrovesicovaginal fistula **IIAa** slightly L at bladder neck, leaking urine of 3 mth (delivered 15/12-93) which started immediately following obstructed labor for 3 days, in hospital (eclampsia) a SB female, married 5 yr ago pre(menarche 2 yr later), not living with husband, no menstruation, no RVF, no h/o drop foot; moderate vagina shortening/ slight stenosis

EUO/F 3.5 cm, F/C 2 cm

153.0 cm

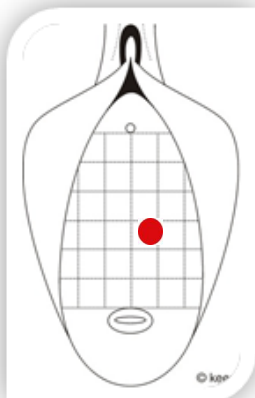
14/03-94 freshening of scarred fistula, dissection, oblique bladder/urethra closure with inverting chromic catgut, oblique avw closure by everting chromic catgut and 2x supramid, FOLEY Ch 18, pack; free flow of urine, EUO/BW 12 cm, good elevation, EUO/B 4 cm anesthetic normal bladder capacity (12-4 = 8 cm) no pain whatsoever

03.04 + 17.04.94 not leaking at all cath removed bladder drill

29.04.94 not leaking at all, no incontinence, normal miction insp/ healed, good elevation, no stress incontinence

01.05 + 15.05 + 18.06.94 idem

11.09.94 not leaking at all, no incontinence, normal miction healed, no stress



1 cm

hyktg (kano city)

female

16 yr

14/03-94

diagnosis: PI, \pm 3 cm 0 urethrovesicovaginal fistula with circumferential defect **IIAb** (anterior bladder wall hanging loose), **leaking urine for 66 days** which started immediately following CS b.c.o. obstructed labor of 2 days, a SB male, married 4 yr ago pre(menarche 8 mth later), not living with husband, no menstruation, drop foot R (grade 4) and L (grade 3); also RVF and sphincter ani rupture slight vagina stenosis/shortening; still poor general condition not fit for anesthesia
 EUO/F 2 cm, F/C 3 cm 147.0 cm

14/03-94 freshening, dissection, circumferential UVVF-"repair" by end-to-end vesicourethrostomy by inverting chromic catgut starting anteriorly with loose hanging anterior bladder wall, transverse avw closure with everting chromic catgut and 3x supramid, FOLEY Ch 18, vagina pack; free urine flow, EUO/BW 8 cm, good elevation, EUO/B 3 cm anesthetic
 moderate bladder capacity (8-3 = 5 cm)
 only slight pain at paraurethral avw closure

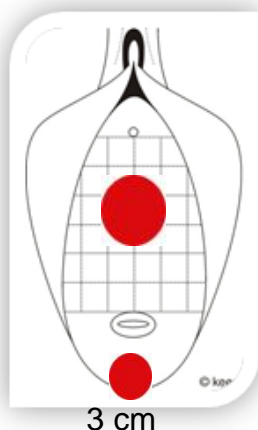
26/06-94 leaking & normal miction
 insp/ healed, poor elevation, stress incontinence ++
 gv: residual fistulas R/L lungu

26/07-94 operation: UVVF-/RVF-repair rvf 117 vvf 847

09.08.94 cath out not leaking at all bladder drill

27/11-94 not leaking, incontinence \pm , normal miction stools ok
 insp/ **both** healed, good elevation, stress incontinence +
?still sphincter rupture?

21/03-95 not leaking at all, no incontinence, normal miction stools ok
 insp/ **both** healed, good elevation, no stress incontinence
sphincter ani healed!



KANO

cath 301

samfl (kano city)

female

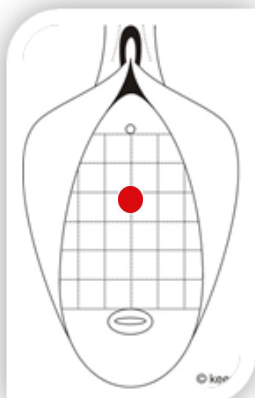
23 yr

21/03-94

diagnosis: PV (4 alive), \pm 1 cm 0 urethrovesicovaginal fistula **IIAa** at midline, **leaking urine for 29 days** which started immediately following obstructed last labor for 2 days, in hospital SB male, married 10 yr ago pre(menarche 5 mth later), still living with husband, no menstruation, drop foot R (grade 4), no RVF
 EUO/F 3.5 cm, F/C 5 cm 154.0 cm

21/03-94 freshening, dissection, scarring/inflammation +, transverse bladder/urethra closure by inverting chromic catgut, transverse avw closure by everting chromic catgut and 4x supramid, FOLEY Ch 18, pack; free urine flow, EUO/BW 11 cm, good elevation, EUO/B 3 cm anesthetic
 normal bladder capacity (11-3 = 8 cm) no pain whatsoever

10.04 + 01.05.94 not leaking at all cath removed bladder drill
 08.05.94 not leaking, incontinence \pm , normal miction healed, stress +
 29.05 + 27.06.94 idem bladder drill
 28.08.94 not leaking at all, no incontinence, normal miction
 insp/ healed, good elevation, no stress incontinence
 02.10.94 not leaking at all, no incontinence, normal miction healed, no stress



1 cm

mmggm (kano city)

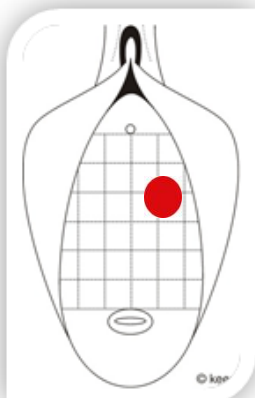
female 14 yr

21/03-94

diagnosis: PI, \pm 1.5 cm 0 urethrovesicovaginal fistula L bladder neck **IIAb** with small circumferential defect, **leaking urine for 41 days** which started immediately following obstructed labor for 2 days, in hospital live male, married 1 yr ago post(menarche 1 mth earlier), not living with husband, no menstruation, drop foot R (grade 4) and L (grade 4), no RVF
 EUO/F 2 cm, F/C 4 cm 154.0 cm

21/03-94 freshening, dissection, dissection of bladder from symphysis, "circumferential" bladder/urethra closure with a single layer of inverting chromic catgut, transverse avw closure by everting chromic catgut and 3x supramid, FOLEY Ch 18, vagina pack; free urine flow, EUO/BW 11 cm, good elevation, EUO/B 2.5 cm anesthetic
 normal bladder capacity (11-2.5 = 8.5 cm)
 slight pain at paraurethral avw closure L

10.04 + 01.05.94 not leaking at all cath removed bladder drill
 08.05.94 not leaking at all, no incontinence, normal miction
 insp/ healed, good elevation, no stress incontinence
 30.05 + 26.06 + 14.08.94 idem
 11.09.94 not leaking at all, no incontinence, normal miction healed, no stress



1.5 cm

KANO

cath 303

zsk (kano city)

female

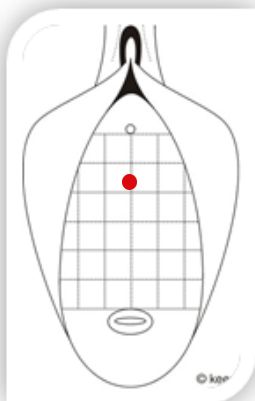
16 yr

21/03-94

diagnosis: PI, ± 3 mm 0 urethrovesicovaginal fistula **IIAa** midline within traumatized avw, **leaking urine for 21 days** which started immediately following obstructed labor for 3 days, in hospital SB male, married 4 yr ago pre(menarche 6 mth later), not living with her husband, no menstruation, no RVF, drop foot R (grade 2-3) and L (grade 3)
 EUO/F 2 cm, F/C 5 cm 152.0 cm

21/03-94 freshening, dissection, transverse bladder/urethra closure with inverting chromic catgut, transverse avw closure with everting chromic catgut and 3x supramid, FOLEY Ch 18, vagina pack; free flow of urine, EUO/BW 11 cm, good elevation, EUO/B 2 cm anesthetic
 normal bladder capacity (11-2 =9 cm) no pain whatsoever

10.04 + 01.05.94 not leaking at all cath removed bladder drill
 08.05.94 not leaking at all, no incontinence, normal miction
 insp/ healed, good elevation, no stress incontinence
 15.05 + 29.05 + 26.06 + 21.08.94 idem
 02.10.94 not leaking at all, no incontinence, normal miction healed, no stress



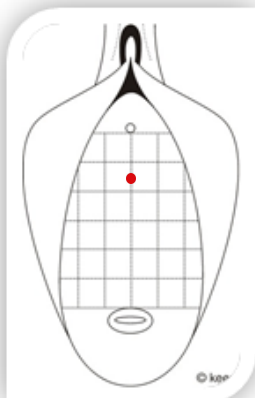
0.3 cm

ruk (kano) female 14 yr 17/04-94

diagnosis: PI, minute \pm 1 mm 0 urethrovesicovaginal fistula midline bladder neck
IIAa, leaking urine for 14 days which started 1 day following obstructed labor for 3 days, in hospital (eclampsia) an SB female, married 1.5 yr ago pre(menarche 4 mth later), not living with husband, no menstruation, no (h/o) drop foot, no RVF
EUO/F 2 cm, F/C 7 cm 156.0 cm

17/4-94 FOLEY Ch 18, vagina pack; free urine flow, EUO/BW 10 cm, good elevation, EUO/B 3 cm; will probably heal spontaneously normal bladder capacity (10-3 = 7 cm)

28.05 + 15.05.94 not leaking insp_gv/ healed cath removed blad drill
29.05.94 not leaking at all, no incontinence, normal miction
insp/ healed, good elevation, no stress incontinence
26.06 + 21.08 + 18.09.94 idem
21.02.95 not leaking at all, no incontinence, normal miction healed, no stress



0.1 cm

rims (kano city)

female

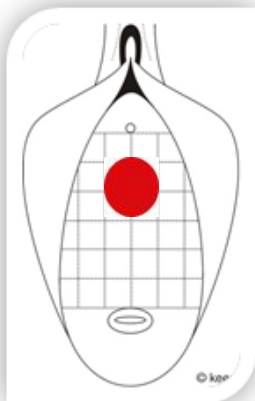
15 yr

16/05-94

diagnosis: PI, \pm 2.5 cm 0 urethrovesicovaginal fistula **IIAb** with small circumferential defect, **leaking urine for 11 days which started 3 day** following obstructed labor for 2 days, in hospital a SB female, married 2 yr ago pre(menarche 1 mth later), not living with her husband, no menstruation, drop foot R (grade 4), no RVF
 EUO/F 1.5 cm, F/C 4 cm 148.0 cm

16/05-94 freshening, dissection, transverse bladder/urethra closure by inverting chromic catgut (!adaptation anteriorly!), transverse avw closure by evert ing chromic catgut/5x supramid, FOLEY Ch 18, pack; free urine flow, EUO/BW 11 cm, good elevation, EUO/B 3 cm anesthetic
 normal bladder capacity (11-3 = 8 cm)

- 29.05 + 12.06.94 incontinence cath removed bladder drill
- 18.06.94 not leaking, incontinence \pm , normal miction healed, no stress
- 03.07.94 idem
- 31.07.94 not leaking at all, no incontinence, normal miction
 insp/ healed, good elevation, no stress incontinence
- 25.09.94 idem
- 21.11.94 not leaking at all, no incontinence, normal miction healed, no stress
- 20/10-95 operation: live male by **CS** under spinal anesthesia**



2.5 cm

KANO

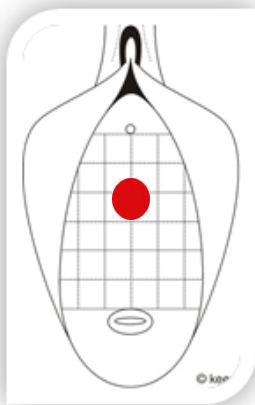
cath 306

hssg (kano) female 14 yr 16/05-94

diagnosis: PI, \pm 1 cm 0 urethrovesicovaginal fistula **IIAa, leaking urine for 15 days which started 10 days** following obstructed labor for 4 day at home SB female, married 1.5 yr ago pre(menarche 6 mth later) not living with husband, no menstruation, no (h/o) drop foot, no RVF
EUO/F 2 cm, F/C 3 cm 144.0 cm

16/05-94 freshening, dissection, transverse bladder/urethra closure with inverting chromic catgut, transverse avw closure with everting chromic catgut and 3x supramid, FOLEY Ch 18, vagina pack; free flow of urine, EUO/BW 11 cm, good elevation, EUO/B 3 cm anesthetic
normal bladder capacity (11-3 = 8 cm) no pain whatsoever

29.05 + 12.06.94 not leaking at all cath removed bladder drill
18.06.94 not leaking at all, no incontinence, normal miction
insp/ healed, good elevation, no stress incontinence
03.07 + 31.07 + 25.09.94 idem
21.11.94 not leaking at all, no incontinence, normal miction healed, no stress



1 cm

KANO

cath 307

mddu (kano city)

female

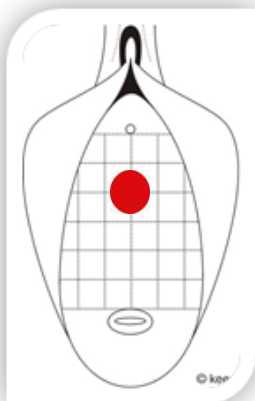
14 yr

24/05-94

diagnosis: PI, \pm 2 cm 0 urethrovesicovaginal fistula **IIAa, leaking urine for 22 days which started 3 days** following obstructed labor for 4 days in hospital an SB female, married 1 yr 4 mth ago pre(menarche 4 mth later), not living with husband, no menstruation, drop foot R (grade 2-3) and L (grade 2-3), no RVF
EUO/F 2 cm, F/C 5 cm 153.0 cm

24/05-94 freshening, dissection, transverse bladder/urethra closure with inverting chromic catgut, transverse avw closure with everting chromic catgut and 4x supramid, FOLEY Ch 18, vagina pack; free flow of urine, EUO/BW 11 cm, good elevation, EUO/B 2.5 cm anesthetic
normal bladder capacity (11-2.5 = 8.5 cm) no pain whatsoever

05.06 + 18.06.94 not leaking at all cath removed bladder drill
26.06.94 not leaking at all, no incontinence, normal miction
insp/ healed, good elevation, no stress incontinence
10.07 + 07.08 + 11.09 + 09.10.94 idem
04.12.94 not leaking at all, no incontinence, normal mictiob healed, no stress



2 cm

KANO

cath 308
RVF

hukr (kano) female 14 yr 29/05-94

diagnosis: PI, ± 1 mm 0 urethrovesicovaginal fistula distally at ± 5 cm 0 avw defect **IIAa**, small proximal rectovaginal fistula as well, **leaking urine/ passing stools per vaginam for 12 days which started 2 days** after obstructed labor for 3 days, at home SB female, married 2 yr ago pre(menarche 8 mth later), not living with husband, no menstruation, drop foot R (grade 2) EUO/AVWT 2 cm, AVWT/C 0 cm 155.0 cm

29/05-94 FOLEY Ch 18, spontaneous healing or later for primary suturing?

21/06-94 freshening, dissection, transverse bladder/urethra closure with inverting chromic catgut, transverse avw closure by 3x everting supramid, FOLEY Ch 18 and pack; free urine flow, EUO/BW 12 cm, good elevation, EUO/B 3 cm no pain whatsoever anesthetic normal bladder capacity (longitudinal diameter 12-3 = 9 cm)

17/7-94 **breakdown**

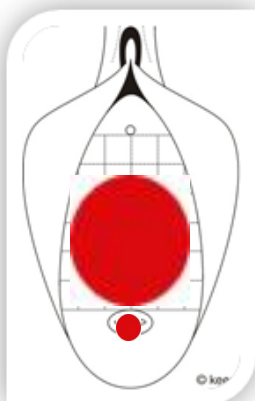
22/11-94 operation: UVVF-repair vvf 933

06.12.94 not leaking at all cath removed bladder drill

11.12.95 not leaking at all, no incontinence, normal miction stools ok insp/ **both** healed, good elevation, no stress incontinence

29.12 + 13.02.95 idem

10.04.95 not leaking at all, normal miction, stools ok **both** healed, no stress



5 cm

smtk (kano city)

female

22 yr

29/05-94

diagnosis: PIV (1 alive), \pm 1 cm 0 necrotic vesicovaginal fistula I midline in front of cervix, **leaking urine for 8 days which started 17 days** following obstructed labor for 4 days, in hospital SB male married 10 yr ago pre(menarche 1 yr later), not living with her husband, no menstruation, drop foot R (grade 3), no RVF
 EUO/F 7 cm, F/C 0 cm 155.0 cm

29/05-94 FOLEY Ch 18, EUO/BW 12 cm, EUO/B 3.5 cm later for primary suturing

05.06.94 **debridement**

12.06 + 18.06.94 not leaking at all still fistula

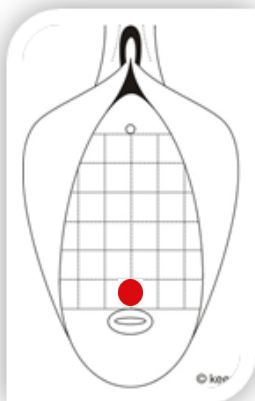
21/06-94 operation: VVF-repair **vvf 814**

05.07 + 17.07.94 not leaking at all cath removed bladder drill

24.07.94 not leaking at all, no incontinence, normal miction
 insp/ healed, moderate elevation, no stress incontinence

14.08 + 11.09 + 06.11.94 idem

16.01.95 not leaking at all, no incontinence, normal miction healed, no stress



1 cm

KANO

cath 310

hssr (kano city)

female

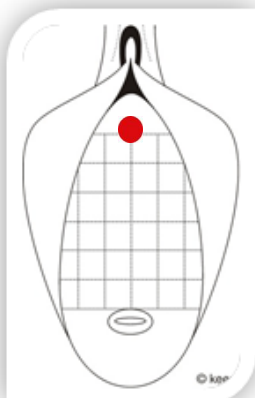
16 yr

29/05-94

diagnosis: PI, urine stress incontinence, **leaking of urine only at daytime for 14 days which started 4 days** following obstructed labor for 2 days, in hospital live female, married 4 yr ago pre(menarche 1 yr later), still living with husband, no menstruation, drop foot R (grade 2), no RVF; normal micturition 151.5 cm

29/5-94 FOLEY Ch 18, EUO/BW 10 cm, good elevation, EUO/B 3 cm
normal bladder capacity (10-3 = 7 cm)

05.06 + 26.06.94 not leaking at all cath removed bladder drill
03/07-94 not leaking at all, no incontinence, normal miction
insp/ healed, good elevation, no (stress) incontinence



aag (kano) female 31 yr 29/05-94

diagnosis: PIX (1 alive), ± 4 cm 0 necrotic urethrovesicovaginal fistula **IIAa**, proximal rectovaginal fistula, **leaking urine/passing stools per vaginam for 23 days which started 3 days** following craniotomy b.c.o. an obstructed last labor for 2 days, SB male, married 20 yr ago pre(menarche 2 yr later), not living with husband, no menstruation no (h/o) drop foot
EUO/F 2 cm, F/C 0 cm 156.5 cm

29/05-94 FOLEY Ch 18, EUO/BW 13 cm, EUO/B 3 cm later for primary suturing

clean fistulas vvf/rvf

14/06-94 operation: UVVF-repair and RVF-repair rvf 110 vvf 810

28.06 + 10.07.94 not leaking, stools ok cath removed bladder drill

11.09.94 **!hypocalcemia!** calcium gluconate iv + oral calcium

25.03.96 not leaking, incontinence ±, stools ok **both** healed, stress ±

20.05.96 not leaking, incontinence ++, normal miction stools ok
insp/ **both** healed, moderate elevation, no stress incontinence

08.06.05 **new leakage** PIX (1 alive) menopause 3 yr ago

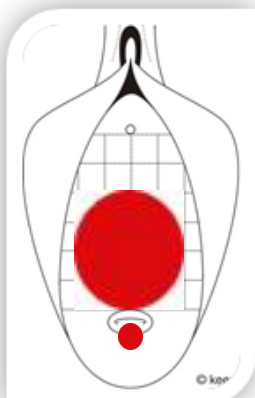
10.07.06 operation: fascia refixation last resort vvf 3626

30.07 + 10.08.06 not leaking at all cath removed bladder drill

01.10.06 not leaking at all, no incontinence, normal miction
insp/ healed, good elevation, no stress incontinence

26.11.06 idem

07.01.07 not leaking at all, no incontinence, normal miction healed, no stress



4 cm

KANO
total intrinsic incontinence 10.05.13

cath 312

hmrk (kano city) female 21 yr 18/04-94

diagnosis: **PI, leaking urine all the time (with normal micturition) for 30 days** which started immediately following vacuum extraction b.c. o. obstructed labor for 2 days, SB male, married 8 yr ago pre(menarthe 1 mth later), not living with husband, no menstruation, no (h/o) drop foot, no RVF; 100 ml gv: no fistula 162.0 cm

18/04-94 FOLEY Ch 18; free flow of urine, EUO/BW 11 cm, good elevation, EUO/BW 4 cm
normal bladder capacity (11-4 = 7 cm)

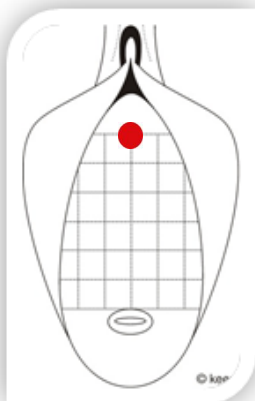
24/04 + 08.05.94 not leaking at all

30/05-94 not leaking at all; 100 ml gv: no leakage catheter removed

31.05.94 not leaking at all, no incontinence, normal miction
insp/ healed, good elevation, no stress incontinence

12.06 + 17.07.94 idem

18.09.94 not leaking at all, no incontinence, normal miction healed, no stress



zwadk (kano city)

female

28 yr

18/04-94

diagnosis: PVII (5 alive), stress incontinence grade III, **leaking urine at day/night when lying/sitting/standing/walking for 57 days** which started 9 days following CS b.c.o. obstructed last labor for 3 days, live male, married 15 yr ago pre(menarche 1 mth later), still living with husband, no menstruation, no (h/o) drop foot, no RVF; or is it a small vesicouterocervicovaginal fistula?????

18/04-94 FOLEY Ch 18; free flow of urine, EUO/BW 11 cm, good elevation, EUO/B 4 cm 155.0 cm
normal bladder capacity (11-4 = 7 cm)

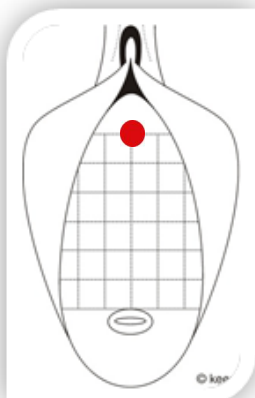
01/05-94 not leaking at all

30/05-94 not leaking at all; 100 ml gv: no leakage catheter removed

31.05.94 not leaking at all, no incontinence, normal miction
insp/ healed, good elevation, no stress incontinence

05.06.94 idem

18.06.94 not leaking at all, no incontinence, normal miction healed, no stress



misr (kano city)

female

15 yr

01/05-94

diagnosis: PI, stress/urge incontinence??, leaking urine (with normal micturition) for 11 mth which started 2 days following obstructed labor for 2 days, in hospital a live female, married 3 yr ago pre(menarche 1 yr later), still living with her husband, normal menstruation, drop foot R (grade 4) and L (grade 4), no RVF 152.0 cm

01/05-94 FOLEY Ch 18; free flow of urine, EUO/BW 9 cm, good elevation, EUO/B 3 cm
moderate bladder capacity (9-3 = 6 cm)

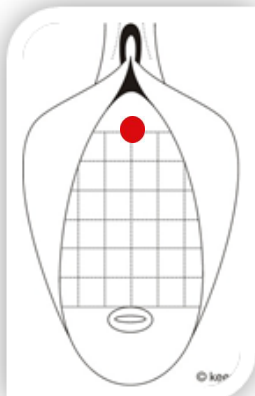
15/05-94 not leaking at all

30/05-94 not leaking at all; 50 ml gv: no leakage catheter removed

31.05.94 not leaking at all, no incontinence, normal miction
insp/ healed, moderate elevation, no stress incontinence

05.06 + 18.06 + 17.07 + 11.09.94 idem

09.10.94 not leaking at all, no incontinence,normal miction healed, no stress



KANO

cath 315

furg (kano city)

female

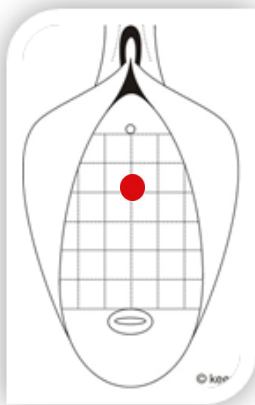
15 yr

06/06-94

diagnosis: PI, \pm 1 cm 0 urethrovesicovaginal fistula L bladder neck **IIAa, leaking urine for 17 days which started 7 days** following obstructed labor for 1 day, at home SB female, married 3 yr ago pre(menarche 1 yr later), not living with husband, no menstruation, drop foot R (grade 3), no RVF (pvw trauma!); narrow pubic angle, moderate vagina stenosis
 EUO/F 2 cm, F/C 6 cm 161.0 cm

06/06-94 freshening, dissection, transverse bladder/urethra closure with inverting chromic catgut, transverse avw closure with everting chromic catgut and 3x supramid, FOLEY Ch 18, vagina pack; free urine flow, EUO/BW 9 cm, good elevation, EUO/B 3 cm anesthetic
 moderate bladder capacity (9-3 = 6 cm)

26.06 + 03.07.94 not leaking at all cath removed bladder drill
 10.07.94 not leaking, incontinence \pm , normal miction healed, no stress
 14.08.94 not leaking at all, no incontinence, normal miction
 insp/ healed, good elevation, no stress incontinence
 14.11.94 not leaking at all, no incontinence, normal miction healed, no stress



1 cm

KANO

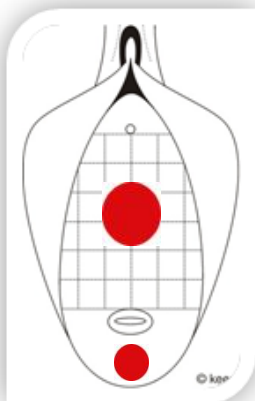
cath 316
RVF

bams (kano) female 14 yr 06/06-94

diagnosis: PI, stress/overflow incontinence, **leaking urine day/night when lying/sitting/standing/walking for 3 days**, stool incontinence for 1 day which started immediately following obstructed labor for 2 days, at home SB male, married 1 yr ago pre(menarche 2 mth later, not living with husband, no menstruation, no (h/o) drop foot; \pm 2.5 cm 0 avw trauma/necrosis? **IIAa**, \pm 3 cm 0 pvw trauma no suprapubic mass, but avw bulging into vagina
EUO/AVWT 2 cm, AVWT/C 5 cm 155.0 cm

06/06-94 FOLEY Ch 18; a free urine flow, EUO/BW 12 cm, no elevation and EUO/B 3 cm
normal bladder capacity (12-3 = 9 cm) **documented 6.6.94**

26.06 + 03.07.94 not leaking at all cath removed bladder drill
10.07.94 not leaking at all, no incontinence, normal miction stools ok
insp/ **both** healed, good elevation, no stress incontinence
24.07 + 18.09.94 idem
20.11.94 not leaking at all, no incontinence, normal miction **both** healed, no stress



2.5 cm

smsys (kano)

female

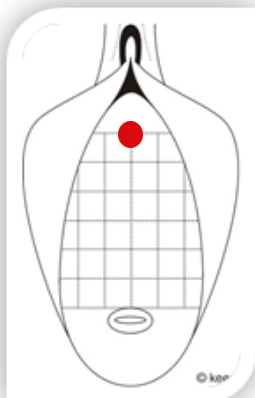
17 yr

13/06-94

diagnosis: PI, stress urine incontinence, only **coital leaking** of urine for 4 mth which started 2 mth following obstructed labor for 2 day, in hospital (eclampsia) live male which died 16 days later married 4.5 yr ago pre(menarche 1 yr later), normal menstruation, divorced by husband due to this problem, no RVF; stress incontinence only as demonstrated by 100 ml gv 157.0 cm

13/06-94 FOLEY Ch 18; a free urine flow, EUO/BW 13 cm, no elevation, UV-junction kinked (urethra against symphysis), EUO/B 3 cm normal bladder capacity (13-3 = 10 cm) bladder drill + instructions if no improvement, later for vaginal colposuspension

18.06 + 10.07.94	not leaking at all	cath removed	bladder drill
17.07.94	not leaking at all, no incontinence, normal miction insp/	healed, good elevation, no stress incontinence	
11.09.94	not leaking at all, no incontinence, normal miction	healed, no stress	



mlyk (kano city)

female

17 yr

19/06-94

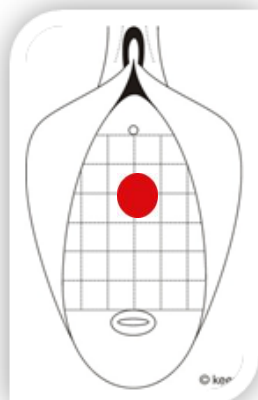
diagnosis: PII (1 alive), ± 2 cm 0 necrotic (to cause fistula?) avw trauma over UV-junction, **leaking of urine (from EUO) for 11 days** which started immediately following obstructed last labor for 1 day, in hospital vacuum extraction of SB male, married 4 yr ago pre(menarche 3 mth later), still living with husband, no menstruation, no h/o drop foot (but R grade 4), no RVF

EUO/AVWT 2 cm, AVWT/C 5 cm

155.0 cm

19/06-94 FOLEY Ch 18; free urine flow, EUO/BW 13 cm, moderate elevation, EUO/B 4 cm; will it heal spontaneously??
normal bladder capacity (13-4 = 9 cm)

03.07 + 18.07.94 not leaking insp_gv/ healed cath removed blad drill
24.07.94 not leaking at all, no incontinence, normal miction
insp/ healed, good elevation, no stress incontinence
08.08 + 18.09.94 idem
14.11.94 not leaking at all, no incontinence,normal miction healed, no stress



2 cm

mam (kano) female 16 yr 19/06-94

diagnosis: PI, ± 2x0.5 cm longitudinal avw trauma I midline in front of cervix (with seeping thru?), **leaking urine for 21 days** which started immediately following obstructed labor for 3 days, in hospital live male, married 3 yr ago post(menarche 2 mth earlier), not living with husband, no menstruation, no (h/o) drop foot, no RVF; open episiotomy L EUO/AVWT 6 cm, AVWT/C 0 cm 154.0 cm

19/06-94 FOLEY Ch 18; probably it will heal spontaneously, a free urine flow, EUO/BW 9 cm, good elevation, EUO/B 3 cm moderate bladder capacity (9-3 = 6 cm)

17.07.94 not leaking, incontinence insp_gv/ healed cath removed

24.07.94 not leaking, incontinence ±, normal miction healed, no stress

08.08.94 idem

11.09.94 not leaking at all, no incontinence, normal miction insp/ healed, good elevation, no stress incontinence

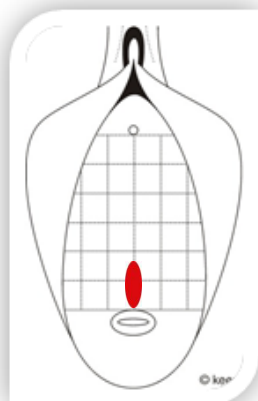
16.01.95 not leaking at all, no incontinence, normal miction healed, no stress

16/09-01 **new obstetric leakage** PIII (3 alive) atonic bladder **cath 606**

14.10.01 not leaking at all cath removed bladder drill

28/10-01 not leaking at all, no incontinence, normal miction insp/ healed, moderate elevation, no stress incontinence

30.12.01 not leaking at all, no incontinence, normal miction healed, no stress



2x0.5 cm

KANO

cath 320

zdmtn (kano city)

female 14 yr

27/06-94

diagnosis: PI, \pm 5 mm 0 vesicovaginal fistula **IIAa** midline bladder neck, **leaking urine for 38 days which started 12 days** following obstructed labor for 2 days, in hospital a SB male, married 1.5 yr ago pre(menarche 5 mth later), not living with husband, no menstruation, drop foot R (grade 3), no RVF; slight vagina stenosis
 EUO/F 4 cm, F/C 4 cm 158.0 cm

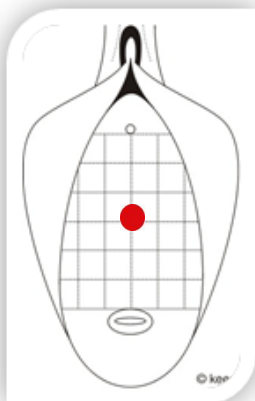
27/06-94 freshening, dissection, transverse bladder/urethra closure with inverting chromic catgut, transverse avw closure with everting chromic catgut and 3x supramid, FOLEY Ch 18, vagina pack; free flow of urine, EUO/BW 12 cm, good elevation, EUO/B 4 cm anesthetic
 normal bladder capacity (12-4 = 8 cm)

17.07.94 cath out x 2/7 leaking \pm /incontinence \pm foley ch 18
 31.07.94 not leaking at all cath removed bladder drill

21/08-94 not leaking, incontinence ++, normal miction
 insp/ **fistula**

30/08-94 operation (il): UVVF-repair vuf 8

14/11-94 not leaking at all, no incontinence, normal miction
 insp/ healed, good elevation, no stress incontinence



0.5 cm

KANO

cath 321

tbskm (kano city)

female

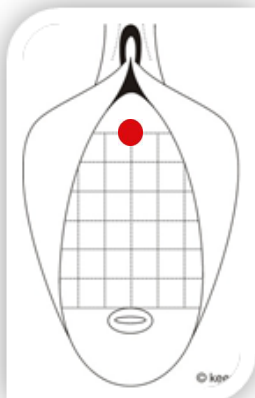
15 yr

03/07-94

diagnosis: PI, incontinence???, **leaking urine for 16 days which started 5 days** following labor for 1 day, at home live male, married 2 yr ago post(menarche 2 mth earlier), not living with husband, no menstruation, no (h/o) drop foot, no RVF; no fistula seen; no stress demonstrated, mental retardation
154.5 cm

03/07-94 FOLEY Ch 18; a free urine flow, EUO/BW 10 cm, no elevation and EUO/B 3 cm
normal bladder capacity (10-3 = 7 cm)

31.07.94 not leaking at all cath removed bladder drill
21/11-94 not leaking at all, no incontinence, normal miction
insp/ healed, good elevation, no stress incontinence



bthk (kano city)

female

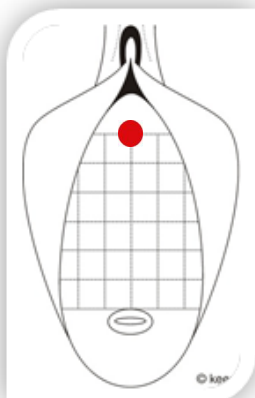
16 yr

17/07-94

diagnosis: PI, overflow incontinence due to atonic bladder, **leaking urine for 28 days** which started 2 days following obstructed labor for 1 day, in hospital (eclampsia) SB male, married 6 yr ago pre(menarche 3 yr later), still living with husband, no menstruation, no (h/o) drop foot, no RVF 170.0 cm

17/07-94 suprapubic mass, avw bulging into vagina, bladder overdistended (EUO/BW 24 cm!!!), EUO/B 3 cm, no elevation, > 1500 ml urine increased bladder capacity (24-3 = 21 cm!!!) FOLEY Ch 18

31.07 + 28.08.94 not leaking at all cath removed bladder drill
25.09.94 not leaking at all, no incontinence, normal miction
insp/ healed, good elevation, no stress incontinence
23.10 + 20.12.94 idem
23.01.95 not leaking at all, no incontinence, normal miction healed, no stress



KANO

cath 324

samtr (kano)

female

28 yr

17/07-94

diagnosis: PI, ± 5x1 cm avw trauma L bladder neck/base **IIAa** with seeping thru/necrosis?, **leaking urine for 14 days which started 5 days** following vacuum extraction b.c.o. obstructed labor for 4 days, SB female, married 15 yr ago pre(menarche 3 mth later), not living with husband, no menstruation, no RVF, drop foot R (grade 4-5) and L (grade 4); trauma due to vacuum extraction????

EUO/AVWT 2 cm, AVWT/C 0 cm

152.0 cm

17/07-94 FOLEY Ch 18; free urine flow, EUO/BW 10 cm, moderate elevation, EUO/B 2 cm

good bladder capacity (10-2 = 8 cm)

will it heal spontaneously?

31.07 + 14.08.94 not leaking, incontinence cath removed bladder drill

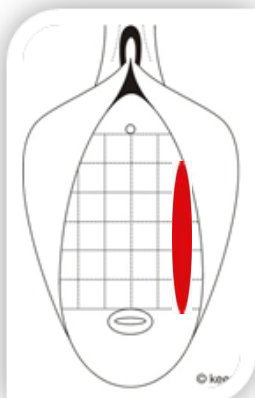
21.08.94 not leaking, incontinence ±, normal miction healed, stress +

18.09.94 idem

21.11.94 not leaking at all, no incontinence, normal miction

insp/ healed, moderate elevation, no stress incontinence

23.01.95 not leaking at all, no incontinence, normal miction healed, stress +



5x1 cm

saml (kano)

female

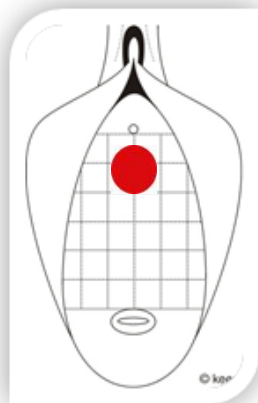
15 yr

18/07-94

diagnosis: PI, \pm 1 cm 0 urethrovaginal fistula **IIAa** within \pm 2 cm 0 avw trauma, **leaking urine for 29 days** which started 1 day after obstructed labor for 2 days, in hospital an SB male, married 3 yr ago pre(menarche 1.5 yr later), not living with husband, no menstruation, drop foot R (grade 4), no RVF; slight vagina stenosis
 EUO/F 1 cm, AVW/C 5 cm 160.0 cm

18/07-94 freshening, minimal dissection, transverse urethra closure by single layer of inverting chromic catgut, transverse avw closure with everting chromic catgut and 3x supramid, FOLEY Ch 18, vagina pack; a free urine flow, EUO/BW 12 cm, good elevation, EUO/B 3 cm anesthetic
 normal bladder capacity (12-3 = 9 cm)

31.07 + 14.08.94 not leaking at all cath removed bladder drill
 28.08.94 not leaking at all, no incontinence, normal miction
 insp/ healed, good elevation, no stress incontinence
 25.09.94 idem
 20.11.94 not leaking at all, no incontinence, normal miction healed, no stress



2 cm

mahs (kano city)

female 36 yr

18/07-94

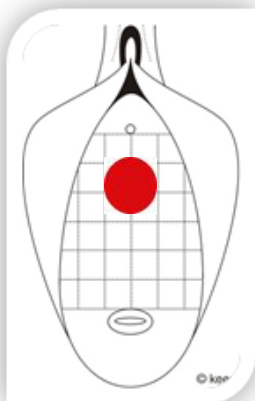
diagnosis: PIX (9 alive), \pm 2.5 cm 0 urethrovesicovaginal fistula **IIAa, leaking urine for 27 days** which started upon removal of catheter 3 days following CS bco retained 2nd twin (SB male) and spontaneous delivery for 1 day of first twin at home (live female), married 25 yr ago pre(menarche 1.5 yr later), still living with husband no menstruation, drop foot R (grade 3), no RVF

EUO/F 1.5 cm, F/C 5 cm

156.0 cm

18/07-94 **debrideement**, freshening, minimal dissection, transverse bladder/urethra closure by inverting chromic catgut, transverse avw closure by everting chromic catgut/5x supramid, FOLEY Ch 18, pack; free urine flow, EUO/BW 11 cm, good elevation, EUO/B 2 cm anesthetic normal bladder capacity (11-2 = 9 cm)

31.07 + 14.08.94 not leaking at all cath removed bladder drill
21.08.94 not leaking, incontinence \pm , normal miction healed, stress +
11.09 + 09.10 + 27.11 + 03.04.95 idem **bladder drill**
22/05-95 not leaking at all, no incontinence, normal miction insp/ healed, moderate elevation, stress incontinence \pm



2.5 cm

KANO

cath 327

bbg (kano city)

female

14 yr

25/07-94

diagnosis: PI, ± 3 mm 0 urethrovesicovaginal fistula **IIAa** midline, **leaking of urine for 15 days which started 14 days** following CS b.c.o. obstructed labor for 2 days, SB male, married 2 yr ago pre(menarche 6 mth later), not living with husband, no menstruation, no RVF, drop foot R (grade 4-5) and L (grade 4); still some necrosis, narrow pubic angle, slight vagina stenosis

EUO/F 1.5 cm, F/C 4 cm

146.5 cm

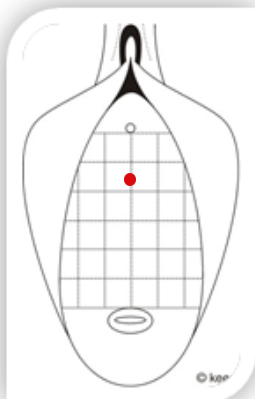
25/07-94 **debridement**, transverse incision thru fistula, dissection, transverse bladder/urethra closure by inverting chromic catgut, transverse avw closure by everting chromic catgut and 3x supramid, FOLEY Ch 18, pack; free urine flow, EUO/BW 9 cm, good elevation, EUO/B 2 cm anesthetic normal bladder capacity (9-2 = 7 cm)

14.08 + 21.08.94 not leaking at all cath removed bladder drill

28.08.94 not leaking at all, no incontinence, normal miction
insp/ healed, good elevation, no stress incontinence

25.09 + 30.11.94 idem

16.01.95 not leaking at all, no incontinence, normal miction healed, no stress



0.3 cm

KANO

cath 328

hgw (kano)

female

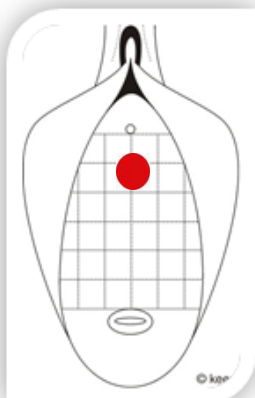
15 yr

25/07-94

diagnosis: PI, \pm 1.5 cm 0 urethrovesicovaginal fistula **IIAa, leaking urine for 59 days which started 2 days** after obstructed labor for 2 days, in hospital (25/5-94) SB female, married 2 yr ago post(menarche 1 mth earlier), not living with husband, no menstruation, no (h/o) drop foot, no RVF; very narrow pubic angle, severe vagina stenosis
 EUO/F 1 cm, F/C 5 cm 147.0 cm

25/07-94 freshening, dissection, transverse bladder/urethra closure with inverting chromic catgut, transverse avw closure with everting chromic catgut and 3x supramid, FOLEY Ch 18, vagina pack; free urine flow, EUO/BW 15 cm, good elevation, EUO/B 2 cm anesthetic
 increased bladder capacity (15-2 = 13 cm, atonic bladder?)

14.08 + 21.08.94 not leaking at all cath removed bladder drill
 28.08.94 not leaking at all, no incontinence, normal miction
 insp/ healed, good elevation, no stress incontinence
 25.09 + 20.11.94 idem
 23.01.95 not leaking at all, no incontinence, normal miction healed, no stress



1.5 cm

KANO

cath 329

hacl (kano city)

female

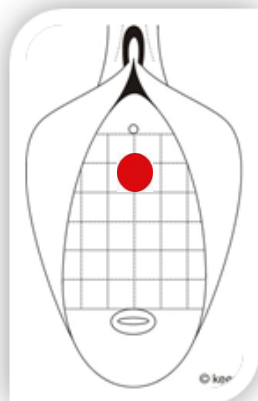
15 yr

26/07-94

diagnosis: PI, \pm 1.5 cm 0 urethrovesicovaginal fistula **IIAa, leaking urine for 15 days which started 4 days** following obstructed labor for 2 days, in hospital (eclapsia) SB female, married 2 yr ago pre(menarche 2 mth later), not living with husband, no menstruation, no RVF, no (h/o) drop foot; narrow pubic angle, slight vagina stenosis
EUO/F 1 cm, F/C 5 cm 150.0 cm

26/07-94 freshening, dissection, transverse bladder/urethra closure with inverting chromic catgut, transverse avw closure with everting chromic catgut and 3x supramid, FOLEY Ch 18, vagina pack; free flow of urine, EUO/BW 12 cm, good elevation, EUO/B 2 cm anesthetic
normal bladder capacity (12-2 = 10 cm)

14.08 + 21.08.94 not leaking at all cath removed bladder drill
28.08.94 not leaking, incontinence +, normal miction healed, stress +
18.09.94 not leaking, incontinence \pm , normal miction healed, stress \pm
14.11.94 not leaking at all, no incontinence, normal miction
insp/ healed, good elevation, no stress incontinence
13.02.95 not leaking at all, no incontinence, normal miction healed, no stress



1.5 cm

KANO

cath 330

mlt (kano)

female

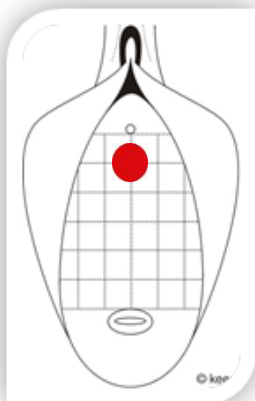
24 yr

26/07-94

diagnosis: PV (1 alive), \pm 1.5 cm 0 urethrovesicovaginal fistula **IIAa, leaking urine for 25 days** which started immediately following obstructed last labor for 2 days, in hospital SB female, married 12 yr ago pre(menarche 6 mth later), still living with her husband, no menstruation, no (h/o) drop foot, no RVF; extirpation of necrosis at 24/7-94
EUO/F 1 cm, F/C 7 cm 158.0 cm

26/07-94 freshening, dissection, transverse bladder/urethra closure with inverting chromic catgut, transverse avw closure with everting chromic catgut and 3x supramid, FOLEY Ch 18, vagina pack; free flow of urine, EUO/BW 13 cm, good elevation, EUO/B 3 cm anesthetic
normal bladder capacity (13-3 = 10 cm)

14.08 + 21.08.94 not leaking at all cath removed bladder drill
28.08.94 not leaking at all, no incontinence, normal miction
insp/ healed, good elevation, no stress incontinence
25.09.94 idem
21.11.94 not leaking at all, no incontinence, normal miction healed, no stress



1.5 cm

humr (kano city)

female

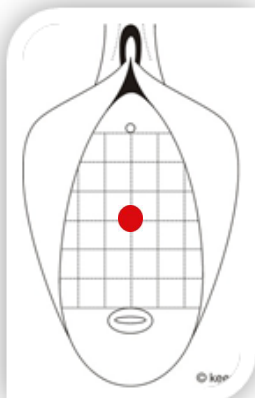
16 yr

04/09-94

diagnosis: PII (0 alive), \pm 1 cm 0 necrotic vesicovaginal fistula midline bladder neck
IIAa, leaking of urine for 12 days which started 8 days following
 obstructed last labor for 4 days, at home SB female, married 3 yr ago
 pre(menarche 1 mth later), still living with husband, no menstruation, drop
 foot L (grade 4), no RVF; slight vagina stenosis, borderline pubic angle
 EUO/F 4 cm, F/C 4 cm 144.0 cm

04/09-94 FOLEY Ch 18; free flow of urine, EUO/BW 12 cm, good elevation, EUO/B
 4 cm; will it heal spontaneously?
 normal bladder capacity (12-4 = 8 cm)

18.09 + 03.10.94 not leaking insp_gv/ healed cath removed blad drill
 09.10.94 not leaking, incontinence \pm , normal miction healed, no stress
 23.10.94 not leaking at all, no incontinence, normal miction
 insp/ healed, good elevation, no stress incontinence
 21.11.94 idem
 26.01.95 not leaking at all, no incontinence, normal miction healed, no stress



1 cm

KANO

cath 332

hrkr (kano)

female

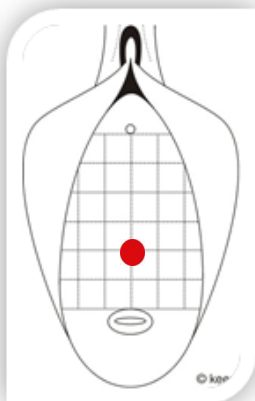
36 yr

12/09-94

diagnosis: PXII (5 alive), \pm 1 cm 0 vesicovaginal fistula **IIAa** midline bladder neck/base, **leaking urine for 26 days** which started immediately following obstructed last labor for 3 days, in hospital SB female, married 24 yr ago pre(menarche 1 yr later), still living with husband, no menstruation, no (h/o) drop foot, no RVF; normal pubic angle
EUO/F 5 cm, F/C 2 cm 153.0 cm

12/09-94 freshening, dissection, transverse bladder closure by inverting chromic catgut, transverse avw closure by everting chromic catgut and 3x supramid, FOLEY Ch 18, vagina pack; EUO/BW 11 cm, no elevation, EUO/B 4 cm anesthetic
normal bladder capacity (11-4 = 7 cm) no pain whatsoever!

25.09 + 09.10.94 not leaking at all cath removed bladder drill
16.10.94 not leaking at all, no incontinence, normal miction
insp/ healed, poor elevation, no stress incontinence
30.10.94 idem
27.11.94 not leaking at all, no incontinence, normal miction healed, no stress
menstruating at the moment



1 cm

KANO

cath 333

zdhau (kano city)

female

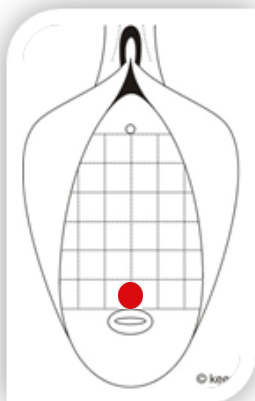
32 yr

12/09-94

diagnosis: PVIII (6 alive), \pm 5 mm 0 vesicovaginal fistula I midline and in front of cervix, **leaking urine for 15 days which started 11 day** following obstructed last labor of 3 days, in hospital SB male, married 20 yr ago pre(menarche 1 yr later), still living with husband, no menstruation, no (h/o) drop foot, no RVF; pubic angle normal
EUO/F 8 cm, F/C 0 cm 146.0 cm

12/09-94 freshening, dissection, longitudinal bladder closure by inverting chromic catgut, longitudinal avw closure by everting chromic catgut/supramid 3x, foley ch 18, pack; euo/bw 11 cm, no elevation, euo/b 3 cm anesthetic normal bladder capacity (11-3 = 8 cm)

25.09 + 09.10.94 not leaking at all cath removed bladder drill
16.10.94 not leaking at all, no incontinence, normal miction
insp/ healed, poor elevation, no stress incontinence
30.10 + 27.11.94 idem
14.03.95 not leaking at all, no incontinence, normal miction healed, no stress



0.5 cm

KANO

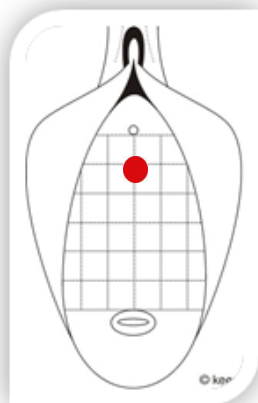
cath 334

jak (kano) female 17 yr 12/09-94

diagnosis: PI, \pm 1 cm 0 urethrovaginal fistula **IIAa, leaking urine for 29 days** which started 1 day following obstructed labor for 3 days, in hospital SB female, married 4 yr ago pre(menarche 2 mth later), not living with husband, no menstruation, no (h/o) drop foot, no RVF; very narrow pubic angle, moderate vagina stenosis
EUO/F 1.5 cm, F/C 8 cm 165.0 cm

12/09-94 freshening, dissection, since longitudinal closure not possible transverse urethra closure by inverting chromic catgut, transverse avw closure by 3x supramid, FOLEY Ch 18, pack; free flow of urine, EUO/BW 12 cm, good elevation, EUO/B 3 cm anesthetic
normal bladder capacity (12-3 = 9 cm)

09.10.94 not leaking, incontinence cath removed bladder drill
16.10.94 not leaking, incontinence \pm , normal miction healed, no stress
30/10-94 not leaking at all, no incontinence, normal miction
insp/ healed, good elevation, no stress incontinence

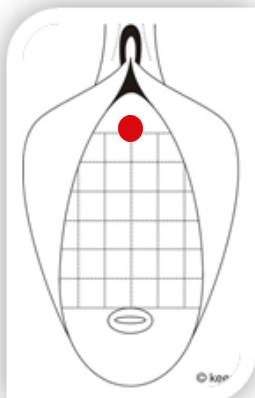


mif (kano city) female 15 yr 18/09-94

diagnosis: PI, stress incontinence??, **leaking urine on cough/sneeze for 8 days** which started immediately following obstructed labor for 1 day, in hospital (eclampsia) live female, married 2 yr ago post (menarche 3 mth earlier), still living with husband, no RVF, no menstruation, no (h/o) drop foot; normal pubic angle 162.0 cm

18/09-94 FOLEY Ch 18; bladder totally empty, EUO/BW 8 cm, no elevation, EUO/B 3 cm moderate bladder capacity (8-3 = 5 cm)

02.10 + 17.10.94 not leaking at all cath removed bladder drill
30.10.94 not leaking at all, no incontinence, normal miction
insp/ healed, poor elevation, no (stress) incontinence
27.11.94 idem
23.01.95 not leaking at all, no incontinence, normal miction healed, no stress



KANO

cath 336

azg (kano)

female

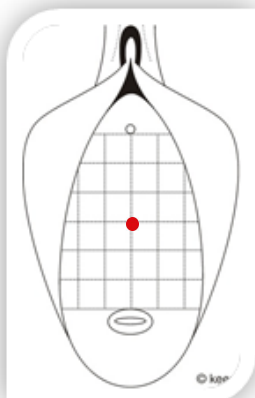
15 yr

19/09-94

diagnosis: PI, \pm 3 mm 0 vesicovaginal fistula **IIAa** midline bladder neck, **leaking urine for 53 days which started 14 days** following obstructed labor for 4 days, in hospital SB male, married 2 yr ago pre(menarche 2 mth later), not living with husband, no menstruation, no (h/o) drop foot, no RVF; normal pubic angle
 EUO/F 4.5 cm, F/C 4 cm 156.0 cm

19/09-94 transverse incision thru fistula, dissection, transverse bladder closure by inverting chromic catgut, transverse avw closure by everting chromic catgut and 3x supramid, FOLEY Ch 18, vagina pack; free urine flow, EUO/BW 12 cm, good elevation, EUO/B 4 cm anesthetic
 normal bladder capacity (12-4 = 8 cm)

16.10.94 not leaking at all cath removed bladder drill
 23.10.94 not leaking at all, no incontinence, normal miction
 insp/ healed, good elevation, no stress incontinence
 06.11 + 23.01.95 idem
 14.03.95 not leaking at all, no incontinence, normal miction healed, no stress



0.3 cm

KANO

cath 337

amhw (kano city)

female

14 yr

26/09-94

diagnosis: PI, \pm 5 mm 0 urethrovesicovaginal fistula **IIAa** at midline, **leaking urine for 14 days** which started immediately following CS (12/9-94) b.c.o. obstructed labor for 2 days, live male, married 3 yr ago pre(menarche 2 yr later), not living with husband, no (h/o) drop foot, no menstruation, no RVF; narrow pubic angle
 EUO/F 2.5 cm, F/C 5 cm 169.0 cm

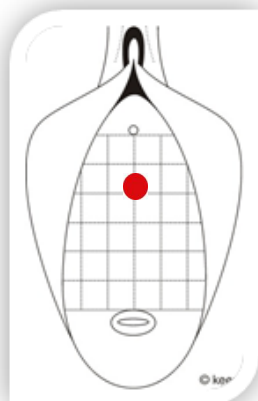
26/09-94 freshening, dissection, transverse bladder/urethra closure with inverting chromic catgut, transverse avw closure with everting chromic catgut and 3x supramid, FOLEY Ch 18, vagina pack; free flow of urine, EUO/BW 12 cm, good elevation, EUO/B 3 cm anesthetic
 normal bladder capacity (12-3 = 9 cm)

09.10 + 23.10.94 not leaking at all cath removed bladder drill
 30.10 + 14.11 + 20.12.94 not leaking, incontinence \pm , normal miction
 insp/ healed, good elevation, no stress incontinence

16/01-95 **leaking gv: leakage R ??early sex??**
17/05-95 operation: UVVF-repair **VVF 1019**

residual 0.5 cm fistula with traumatized euo
10/10-95 operation: urethra/avw reconstruction **VVF 1160**

24.10.95 not leaking at all cath removed bladder drill
 30.10 + 13.11.95 not leaking, incontinence \pm , normal miction healed, stress +
 04/03-96 not leaking at all, no incontinence, normal miction
 insp/ healed, good elevation, stress incontinence \pm



0.5 cm

zhmk (kano)

female

28 yr

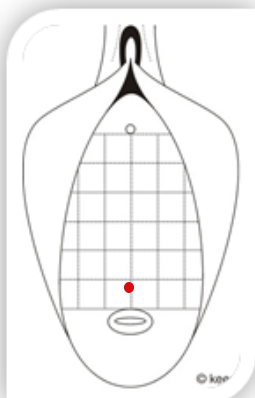
02/10-94

diagnosis: PIX (4 alive), minute 1 mm 0 vesicovaginal fistula midline at bladder base
I, leaking of urine for 12 days which started 5 days following obstructed last labor for 1.5 day, at home a SB male, married 15 yr ago pre(menarche 3 mth later), still living with husband, no menstruation, no (h/o) drop foot, no RVF; pubic angle normal
EUO/F 7 cm, F/C 1 cm 157.0 cm

02/10-94 FOLEY Ch 18; free urine flow, EUO/BW 12 cm, moderate elevation, EUO/B 3 cm will it heal spontaneously?
normal bladder capacity (12-3 = 9 cm)

31/10-94 not leaking at all gv: **still leakage**

01/11-94 though properly instructed (!planned for operation today!) pat went home



minute fistula

ampk (kano city)

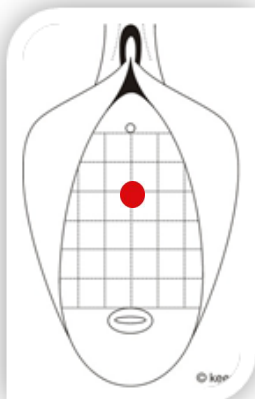
female 14 yr

02/10-94

diagnosis: PI, overflow incontinence due to atonic bladder, minimal avw trauma **IIAa**, **leaking urine of 18 days** which started immediately following obstructed labor for 3 days, in hospital (eclampsia) an SB male, married 2 yr ago pre(menarche 8 mth later), not living with husband, no menstruation, no (h/o) drop foot, no RVF; borderline pubic angle
EUO/AVWT 3 cm 154.0 cm

2/10-94 suprapubic mass, avw bulging into vagina, bladder overdistended (EUO/BW 17 cm), EUO/B 3 cm, no elevation, >1000 ml urine increased bladder capacity (17-3 = 14 cm) FOLEY Ch 18

14/11-94 not leaking at all catheter removed **bladder drill**



KANO

cath 340

ash (kano city)

female

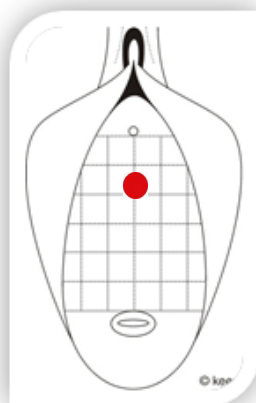
22 yr

03/10-94

diagnosis: PV (1 alive), \pm 1 cm 0 urethrovesicovaginal fistula **IIAa, leaking of urine for 51 days which started 3 days** following an obstructed last labor for 1 day, in hospital SB female, married 10 yr ago pre(menarche 7 mth later), still living with husband, no menstruation, drop foot L (grade 4), no RVF; narrow pubic angle, CS for delivery IV & V
EUO/F 2 cm, F/C 5 cm 157.0 cm

03/10-94 freshening, dissection, transverse bladder/urethra closure with inverting chromic catgut, transverse avw closure with everting chromic catgut and 3x supramid, FOLEY Ch 18, vagina pack; free flow of urine, EUO/BW 13 cm, good elevation, EUO/B 3 cm anesthetic
normal bladder capacity (13-3 = 10 cm)

16.10 + 30.10.94 not leaking at all cath removed bladder drill
06.11.94 not leaking at all, no incontinence, normal miction
insp/ healed, good elevation, no stress incontinence
20.11 + 20.12 + 23.01.95 idem
03.04.95 not leaking at all, no incontinence, normal miction healed, no stress



1 cm

KANO

cath 341

baag (kano city)

female

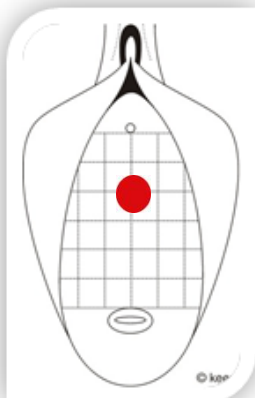
15 yr

03/10-94

diagnosis: PI, ± 1 cm 0 urethrovesicovaginal fistula **IIAa, leaking urine for 18 days** which started immediately following obstructed labor for 1 day, in hospital a live female which died 1 day later, married 2 yr ago post(menarche 3 mth earlier), not living with husband, no menstruation, no h/o drop foot (R grade 4), no RVF; narrow pubic angle
 EUO/F 2 cm, F/C 4 cm 162.0 cm

03/10-94 freshening, dissection, transverse bladder/urethra closure with inverting chromic catgut, transverse avw closure with everting chromic catgut and 3x supramid, FOLEY Ch 18, vagina pack; free flow of urine, EUO/BW 11 cm, good elevation, EUO/B 3 cm anesthetic
 normal bladder capacity (11-3 = 8 cm)

- 16.10 + 30.10.94 not leaking at all cath removed bladder drill
- 06.11.94 not leaking ?incontinence?, normal miction healed, stress ++
- 20.1.94 not leaking at all, no incontinence, normal miction
 insp/ healed, good elevation, no stress incontinence
- 20.12,94 idem
- 13.02.95 not leaking at all, no incontinence, normal miction healed, no stress



1 cm

KANO

cath 342

mdkg (kano)

female

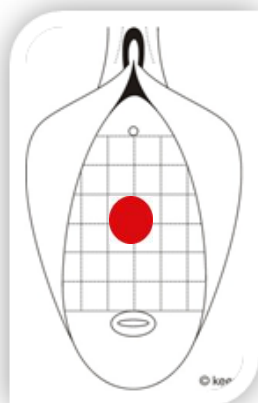
14 yr

03/10-94

diagnosis: PI, ± 1.5 cm 0 urethrovesicovaginal fistula **IIAa, leaking urine for 9 days which started 2 days** following obstructed labor for 5/7, in hospital live male which died 2 days later, married 1 yr ago pre(menarche 4 mth later), not living with husband, no menstruation, drop foot R (grade 3), no RVF; slight vagina shortening, borderline pubic angle
EUO/F 2 cm, F/C 2 cm 148.0 cm

03/10-94 freshening, dissection, transverse bladder/urethra closure with inverting chromic catgut, transverse avw closure with everting chromic catgut and 3x supramid, FOLEY Ch 18, vagina pack; free flow of urine, EUO/BW 10 cm, good elevation, EUO/B 2.5 cm anesthetic
normal bladder capacity (10-2.5 = 7.5 cm)

16.10 + 30.10.94 not leaking at all cath removed bladder drill
06.11.94 not leaking, incontinence +, normal miction
insp/ healed, good elevation, stress incontinence +
21.11.94 idem
20.02.94 not leaking, incontinence +, normal miction healed, stress +



1.5 cm

KANO

cath 343

hak (kano)

female

15 yr

02/10-94

diagnosis: PI, \pm 2 cm 0 avw trauma (necrosis?) I in front of cervix, **leaking urine for 4 days** which started immediately following obstructed labor for 1 day, in hospital SB male, married 3 yr ago pre(menarche 6 mth later), not living with husband, no menstruation, no (h/o) drop foot, no RVF; borderline pubic angle

EUO/AVWT 6 cm, AVWT/C 0 cm

164.0 cm

2/10-94 FOLEY Ch 18; free flow of urine, EUO/BW 12 cm, good elevation, EUO/B 4 cm; will it heal spontaneously?
normal bladder capacity (12-4 = 8 cm)

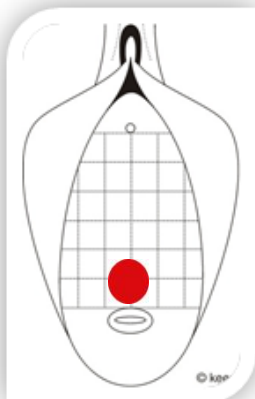
9/10-94 seems to heal spontaneously

31/10-94 not leaking at all insp_gv: **no** leakage cath removed

06.11.94 not leaking at all, no incontinence, normal miction
insp/ healed, good elevation, no stress incontinence

04.12 + 23.01.95 idem

21.03.95 not leaking at all, no incontinence, normal miction healed, no stress



2 cm

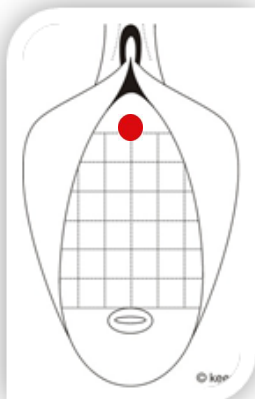
actually total intrinsic incontinence as "healing phase" 10.05.13

bhj (kano) female 14 yr 09/10-94

diagnosis: PI, overflow incontinence due to atonic bladder, **leaking urine for 14 days** which started immediately following obstructed labor for 2 days, in hospital SB male, married 2 yr ago pre(menarche 1 yr later), still living with husband, no menstruation, drop foot R (grade 4), no RVF; narrow pubic angle, open episiotomy L 154.0 cm

9/10-94 suprapubic mass, avw bulging into vagina, bladder overdistended (EUO/BW 15 cm), no elevation, EUO/B 3 cm, >1000 ml urine increased bladder capacity (15-3 = 12 cm) FOLEY Ch 18

23.10 + 14.11.94 not leaking at all cath removed bladder drill
27.11.94 not leaking at all, no incontinence, normal miction insp/ healed, moderate elevation, no stress incontinence
21.03.95 not leaking at all, no incontinence, normal miction healed, no stress



KANO

cath 345

uw hw (kano city)

female

16 yr

16/10-94

diagnosis: PI, \pm 2 cm avw trauma UV-junction **IIAa** with stress incontinence III, no seeping thru, **leaking urine for 7 days** which started immediately following obstructed labor for 3 days, in hospital an SB male, married 11 mth ago post(menarche 2 yr earlier), not living with husband, no menstruation, drop foot R (grade 4) and L (grade 2-3), no RVF; narrow pubic angle

EUO/AVWT 2 cm, AVWT/C 6 cm

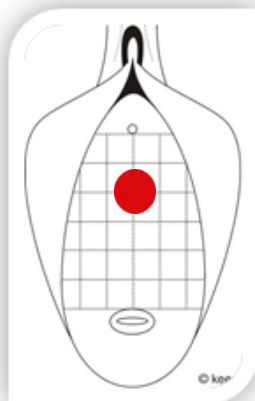
156.0 cm

16/10-94 FOLEY Ch 18; free urine flow, EUO/BW 11 cm, good elevation, EUO/B 3 cm

normal bladder capacity (11-3 = 8 cm)

will it heal spontaneously?

30.11 + 14.11.94 not leaking at all cath removed bladder drill
20.11.94 not leaking at all, no incontinence, normal miction
insp/ healed, good elevation, no stress incontinence
04.12 + 02.01 + 21.02.95 idem
18.04.95 not leaking at all, no incontinence, normal miction healed, no stress



2 cm

KANO

cath 346

auu (kano city)

female

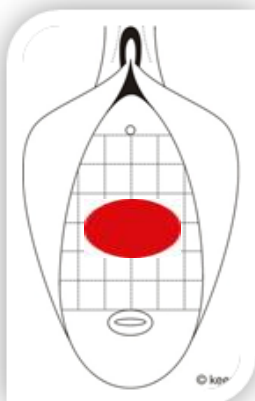
16 yr

17/10-94

diagnosis: PI, extensive \pm 2x1 cm urethrovesicovaginal fistula **IIAa, leaking urine for 15 days which started 14 days** following obstructed labor for 1 day, at home live female which died 7 days later, married 3 yr ago pre(menarche 3 mth later), not living with husband, no menstruation, no (h/o) drop foot, no RVF; pubic angle narrow, severe vagina stenosis/shortening
 EUO/F 1.5 cm, F/c 1 cm 153.0 cm

17/10-94 freshening, dissection, transverse bladder/urethra closure with inverting chromic catgut, transverse avw closure with everting chromic catgut and 3x supramid, FOLEY Ch 18, vagina pack; free flow of urine, EUO/BW 9 cm, good elevation, EUO/B 2.5 cm anesthetic
 moderate bladder capacity (9-2.5 = 6.5 cm)

13.10 + 13.11.94 not leaking at all cath removed bladder drill
 20.11.94 not leaking at all, no incontinence, normal miction healed, stress \pm
 04.12.94 idem
 14/03-95 not leaking, occasionally incontinence $\pm\pm$, normal miction **bladder drill**
 insp/ healed, good elevation, stress incontinence \pm



2x1 cm

siyk (kano city)

female

18 yr

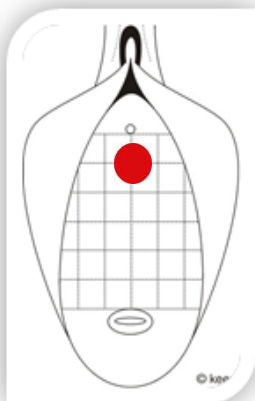
17/10-94

diagnosis: PI, \pm 2 cm 0 urethrovesicovaginal fistula with circumferential defect **IIBb**, **leaking urine for 21 days** which started immediately after obstructed labor for 7 days, in hospital SB male, married 5 yr ago pre(menarche 5 mth later), not living with husband, no menstruation, drop foot R (grade 4), no RVF; anterior bladder wall hanging loose, narrow pubic angle; when seen 2/10-94 at 6-day duration necrotic fistula and pressure ulcer L buttock
 EUO/F 1 cm, F/C 7 cm, AU/AB 0.5 cm 160.0 cm

17/10-94 freshening, dissection, transverse bladder/urethra closure with inverting chromic catgut (!adaptation anteriorly!), transverse avw closure with evert-ing chromic catgut and 3x supramid, FOLEY Ch 18, pack; free flow of urine, EUO/BW 11 cm, good elevation, EUO/B 2 cm anesthetic
 normal bladder capacity (11-2 = 9 cm)

30.10 + 13.11.94 not leaking at all cath removed bladder drill
 20.11 + 04.12.94 not leaking, incontinence \pm , miction healed, stress \pm
 13.02.95 not leaking at all, no incontinence, normal miction
 insp/ healed, good elevation, no stress incontinence
 10.04.95 not leaking at all, no incontinence, normal miction healed, no stress

second obstetric fistula completely ok until PIII (0 alive) sb male in hospital
06/10-97 operation: UVVF-repair **vvf 1569**
 20.10 + 03.11.97 not leaking at all cath removed bladder drill
 17.11.97 not leaking at all, no incontinence, normal miction
 insp/ healed, good elevation, no stress incontinence
 24.11 + 08.12 + 30.12.97 idem
 08.02.98 not leaking at all, no incontinence, normal miction healed, no stress



2 cm

KANO
second obstetric fistula

cath 348
cath 100

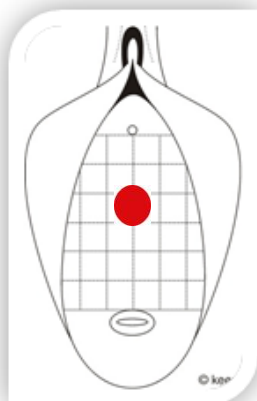
bgnb (kano city) female 16 yr 17/10-94

diagnosis: PII (1 alive), \pm 1 cm 0 urethrovesicovaginal fistula **IIAa, leaking urine for 8 days** which started immediately following vacuum extraction bco obstructed labor for 1 day, live male, married 4 yr ago pre(menarche 6 mth later), still living with husband, no menstruation, no (h/o) drop foot, no RVF; normal pubic angle
EUO/F 2 cm, F/C 3 cm 160.5 cm!

17/10-94 freshening, dissection, scarring +, transverse bladder/urethra closure with inverting chromic catgut, a transverse avw closure by everting chromic catgut and 3x supramid, FOLEY Ch 18, pack; free flow of urine, EUO/BW 12 cm, good elevation, EUO/B 2 cm anesthetic
normal bladder capacity (12-2 = 10 cm)

30.10 + 13.11.94 not leaking at all cath removed bladder drill
20.11.94 not leaking at all, no incontinence, normal miction
insp/ healed, good elevation, no stress incontinence
11.12.94 not leaking at all, no incontinence, normal miction healed, no stress
delivered twice at home and then 1x by cs

third obstetric fistula completely ok until PV (2 alive) sb female by cs
13/11-00 operation: early UVVF-repair vvf 2134
04.12 + 11.12.00 not leaking at all cath removed bladder drill
18.12.00 not leaking at all, no incontinence, normal miction
insp/ healed, good elevation, no stress incontinence



1 cm

uhh (jigawa)

female

14 yr

23/10-94

diagnosis: P0, residual minute 1 mm 0 urethrovesicovaginal fistula **IIBa**, leaking urine for 3 mth which started immediately following yankan gishiri by wanzami bco ba hanya (no proper opening), married 2 yr ago pre(menar-che 1 yr later), not living with her husband, normal menstruation, operated 1x (HADEJIA)

EUO/F 1.5 cm, F/C 7 cm

172.0 cm

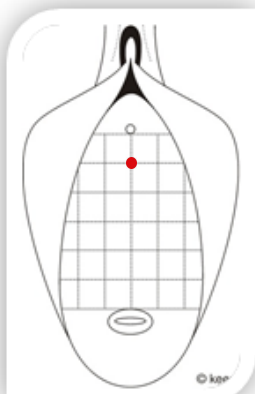
23/10-94 FOLEY Ch 18; free flow of urine, EUO/BW 11 cm, good elevation, EUO/B 2 cm; it will probably heal spontaneously
normal bladder capacity (11-2 = 9 cm)

22/11-94 not leaking at all gv: **no** leakage catheter removed

27.11.94 not leaking at all, no incontinence, normal miction
insp/ healed, good elevation, no stress incontinence

08.01.95 idem

07.03.95 not leaking at all, no incontinence, normal miction healed, no stress



minute fistula

uskw (kano city)

female

14 yr

13/11-94

diagnosis: PI, overflow incontinence due to atonic bladder with 5 mm 0 necrotic avw **IIAa** at midline bladder neck, **leaking of urine for 5 days which started 2 days** following obstructed labor for 2 days, at home live female, married 1 yr ago pre(menarche 4 mth later), not living with husband, no menstruation, drop foot R (grade 3-4), no RVF; borderline pubic angle EUO/AVWT 2 cm, AVWT/C 6 cm 165.0 cm

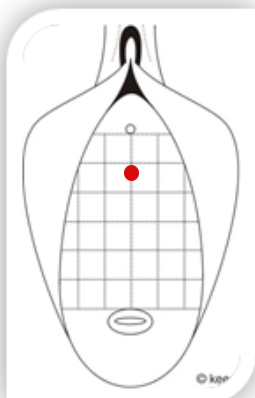
13/11-94 suprapubic mass, avw bulging into vagina, bladder overdistended (EUO/BW 14 cm), no elevation, EUO/B 2 cm, > 500 ml urine increased bladder capacity (14-2 = 12 cm) FOLEY Ch 18

28.11 + 11.12.94 not leaking at all cath removed bladder drill

20.12.94 not leaking at all, no incontinence, normal miction insp/ healed, moderate elevation, no stress incontinence

16.01.95 idem

21.03.95 not leaking at all, no incontinence, normal miction healed, no stress



0.5 cm

KANO

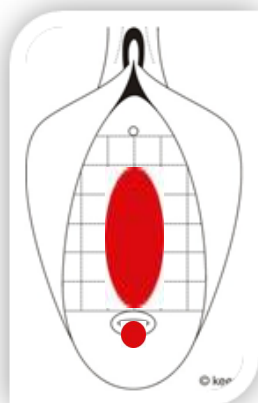
cath 351
rvf

jadk (kano city) female 42 yr 13/11-94

diagnosis: PXII (7 alive), overflow incontinence due to atonic bladder and \pm 7x3 cm (sub)necrotic avw trauma **IIAa**, \pm 3 cm necrotic pvw **Ia** trauma, **leaking of urine for 7 days which started 2 days** following obstructed last labor for 2 days, at home SB male, married 30 yr ago pre(menarche 1 yr later), still living with her husband, no menstruation, no (h/o) drop foot; normal pubic angle
EUO/AVWT 2 cm, AVWT/C 0 cm, I/PVWT 8 cm 163.5 cm

13/11-94 huge suprapubic mass, avw bulging into vagina, bladder overdistended (EUO/BW 24 cm!!), no elevation, EUO/B 3 cm, > 4000 ml !! of urine; will fistula(s) develop????
increased bladder capacity (24-3 = 21 cm!!) FOLEY Ch 18

28.11 + 11.12.94 not leaking at all cath removed bladder drill
20.12.94 not leaking at all, no incontinence, normal miction
insp/ healed, moderate elevation, no stress incontinence
16.01.95 idem
21.03.95 not leaking at all ,no incontinence, normal miction healed, no stress



7x3 cm

msb (kano)

female

15 yr

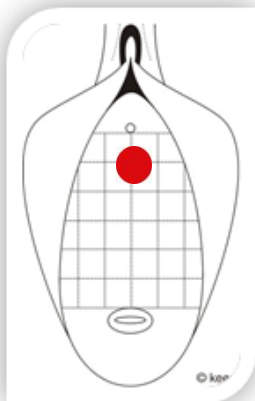
21/11-94

diagnosis: PI, \pm 1.5 cm 0 urethrovesicovaginal fistula with circumferential defect **IIAb, leaking urine of 28 days** which started 1 day following obstructed labor of 3 days, in hospital SB male, married 2 yr ago pre(menarche 3 mth later), not living with husband, no menstruation, drop foot R (grade 0) and L (grade 2-3), no RVF?; very narrow pubic angle, moderate vagina stenosis; almost healed pressure ulcer over R trochanter major; poor general condition, pat cannot stand/walk without support!
 EUO/F 1 cm, F/C 6 cm, AU/AB 0.5 cm 164.0 cm

21/11-94 freshening, dissection (also bladder from symphysis), circumferential bladder/urethra closure with inverting chromic catgut starting with fixation of lateral bladder walls onto symphysis (adaptation anteriorly!!!), transverse avw closure by everting chromic catgut and 3x supramid, FOLEY Ch 18, vagina pack; free urine flow, EUO/BW 12 cm, good elevation, EUO/B 3 cm anesthetic
 normal bladder capacity (12-3 = 9 cm) difficult, slight pain!

20.12.94 leaking cath removed bladder drill
 08.01.95 leaking & miction healed, stress ++ fair condition but far better
 14.03.95 not leaking, incontinence \pm , normal miction **bladder drill**
 healed, good elevation, no stress incontinence condition ok
 19.06.95 idem insp_gv/ healed, no stress, urge \pm **bladder drill**
 02/10-95 not leaking at all, no incontinence, normal miction
 insp/ healed, good elevation, no stress incontinence

second obstetric fistula completely ok until PIV (3 alive) live female at home
01/10-02 operation: UVVF-repair as first stage **vvf 2724**
 20.10 + 03.1.02 not leaking at all cath removed bladder drill
 24.11.02 not leaking at all, no incontinence, normal miction
 insp/ healed, good elevation, no stress incontinence
 05.01 + 02.03.03 idem
 27.04.03 not leaking at all, no incontinence, normal miction healed, no stress



1.5 cm

hssb (kano city)

female 14 yr

15/01-95

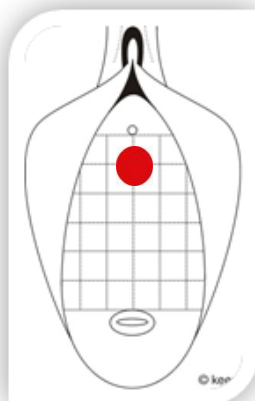
diagnosis: PI, \pm 2 cm 0 avw trauma **IIBa** at proximal urethra/bladder neck, **leaking urine (seeping thru or incontinence) of 10 days which started 12 days** following vacuum b.c.o. obstructed labor of 2 days, in hospital (eclampsia) SB male, married 2 yr ago pre(menarche 1 yr later), not living with husband, no menstruation, no (h/o) drop foot, no RVF; narrow pubic angle

EUO/AVWT 1 cm, AVWT/C 7 cm

158.0 cm

15/01-95 FOLEY Ch 18; free flow of urine, EUO/BW 11 cm, good elevation, EUO/B 3 cm; will it heal spontaneously (seems to be penetrating distally)?? normal bladder capacity (longitudinal diameter 11-3 = 8 cm)

29.01 + 13.02.95 not leaking at all cath removed bladder drill
14/03-95 not leaking, incontinence $\pm\pm$, normal miction
insp/ healed, good elevation, no stress incontinence



2 cm

KANO

cath 354

kstw (kano)

female

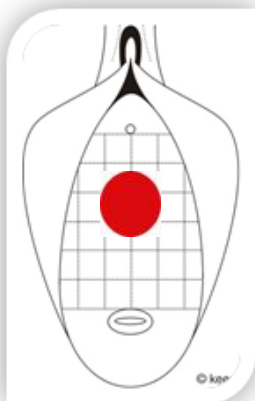
26 yr

23/01-95

diagnosis: PV (4 alive), \pm 4 cm 0 urethrovesicovaginal fistula **IIAa, leaking of urine of 43 days** which started immediately following obstructed last labor for 2 days, in hospital a SB male, married 15 yr ago pre(menarche 2 yr later), still living with husband, no RVF, no h/o drop foot (but both grade 4); normal pubic angle
EUO/F 2 cm, F/C 4 cm 151.0 cm

23/1-95 freshening, dissection, transverse bladder/urethra closure with inverting chromic catgut, transverse avw closure with everting chromic catgut and 5x supramid, FOLEY Ch 18, vagina pack: free flow of urine, EUO/BW 10 cm, good elevation, EUO/B 2 cm anesthetic no pain whatsoever!!!
normal bladder capacity (longitudinal diameter 10-2 = 8 cm)

06.02 + 20.02.95 not leaking at all cath removed bladder drill
06.03 + 21.03.95 not leaking at all, no incontinence, miction healed, stress ++
02/05-95 not leaking at all, no incontinence, normal miction
insp/ healed, good elevation, stress incontinence +



4 cm

ihda (kano)

female

15 yr

29/01-95

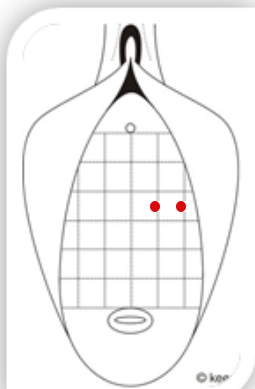
diagnosis: PI, two minute <1 mm 0 urethrovesicovaginal fistula **IIAa** within scar tissue at L bladder neck, leaking urine for 3 mth (last 2 weeks only leaking little and normal micturition) which started immediately following obstructed labor for 2 days, in hospital a SB female, married 2 yr ago pre(menarche 4 mth later), not living with husband, no menstruation, no (h/o) drop foot, no RVF; narrow pubic angle, pt had catheter for 12 days
 EUO/F 4 cm, F/C 5 cm 157.0 cm

29/1-95 FOLEY Ch 18; free flow of urine, EUO/BW 13 cm, good elevation, EUO/B 4 cm; will it still heal spontaneously??
 normal bladder capacity (longitudinal diameter 13-4 = 9 cm)

06.03.95 not leaking at all insp_gv/ minimal leakage cath removed

14.03.95 not leaking at all, no incontinence, normal miction
 insp/ healed, good elevation, no stress incontinence

10.04.95 not leaking at all, no incontinence, normal miction healed, no stress



multiple fistulas

KANO

cath 356

epj (kano city)

female

19 yr

06/02-95

diagnosis: PI, necrotic \pm 6x3 cm urethrovesicovaginal fistula **IIAa, leaking of urine for 9 days** which started immediately following obstructed labor for 3 days, in hospital a SB male, married 1 yr ago post(menarche 5 yr earlier), still living with husband, no menstruation, drop foot L (grade 4), no RVF; narrow pubic angle
EUO/F 2 cm, F/C 0 cm 156.0 cm

06.02.95 FOLEY Ch 18; free urine flow (bladder full), EUO/BW 10 cm, moderate elevation, EUO/B 3 cm wait till slough removal
normal bladder capacity (longitudinal diameter 10-3 = 7 cm)

13/02-95 **debridement**

20.02.95 leaking 0.5 cm fistula within 3x1.5 cm avw defect

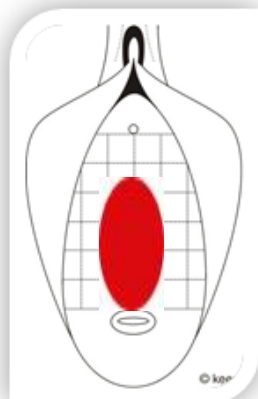
21/02-95 operation: VVF-repair vvf 972

07.03 + 20.03.95 not leaking at all cath removed bladder drill

26.03.95 not leaking at all, no incontinence, normal miction
insp/ healed, good elevation, no stress incontinence

11.04.95 idem

07.08.95 not leaking at all, no incontinence, normal miction healed, no stress



6x3 cm

KANO
fistula healing by catheter only

cath 357

zahn (kano) female 14 yr 13/02-95

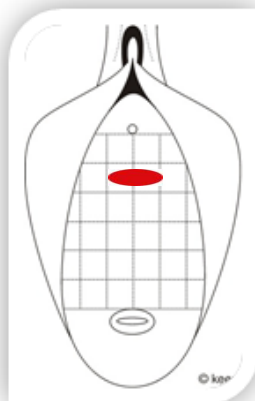
diagnosis: PI, scarred healed \pm 2x0.5 cm avw **IIAa** bladder neck, **leaking urine for 30 days** which started immediately following obstructed labor for 1 day, in hospital SB female, married 2 yr ago pre(menarche still to come as she conceived before), not living with husband, no menstruation, no (h/o) drop foot, no RVF; pubic angle narrow; FOLEY Ch 16 since she started to leak EUO/F 2 cm, F/C 6 cm 151.0 cm

13/2-95 seems healed, avw indurated (as she had not been instructed to drink as much as possible), **catheter removed (balloon 40 ml!)**
EUO/BW 10 cm, moderate elevation, EUO/B 2 cm
normal bladder capacity (longitudinal diameter 10-2 = 8 cm)

07.03.95 not leaking at all, no incontinence, normal miction avw still indurated
Insp/ healed, moderate elevation, stress +

10.04.95 not leaking at all, no incontinence, normal miction
insp/ healed, moderate elevation, no stress incontinence

10.07.95 not leaking at all, no incontinence, normal miction healed, no stress



2x0.5 cm

aak (kano)

female

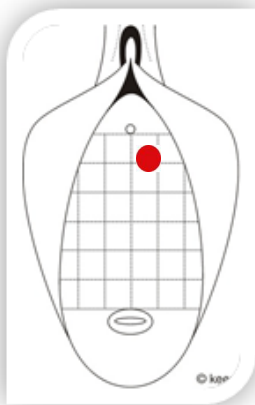
14 yr

21/02-95

diagnosis: PI, healing \pm 5 mm 0 avw defect **IIAa** (seeping thru with incontinence or overflow?) at L bladder neck, **leaking urine for 22 days** that started 1 day following obstructed labor for 1 day, in hospital live female, married 1 yr ago pre(menarche 2 mth later), still living with husband, no menstruation, drop foot R (grade 2) and L (grade 2-3), no RVF; narrow pubic angle; original defect must have been larger and it is healing nicely
 EUO/AVWT 1 cm, F/C 6 cm 161.0 cm

21/2-95 FOLEY Ch 18; free urine flow, EUO/BW 13 cm, no elevation except distal 1 cm urethra, EUO/B 2 cm
 increased bladder capacity (long diameter 13-2 = 11 cm)

21.03.95 cath out x 9/7 not leaking at all bladder drill
 10.04.95 not leaking at all, no incontinence, normal miction
 insp/ healed, good elevation, no stress incontinence
 19.06 + 22.08.95 idem
 25.09.95 not leaking at all, no incontinence, normal miction healed, no stress



0.5 cm

KANO

cath 359

hht (kano) female 24 yr 20/02-95

diagnosis: PV (2 alive), small vesicocervicovaginal fistula??, leaking of urine of 3 mth that started 2 days following CS-(hysterectomy?) b.c.o. ruptured uterus due to obstructed last labor for 1 day, SB male, married 12 yr ago pre(menarche 1 yr later), not living with husband, no menstruation, no (h/o) drop foot, no RVF; normal pubic angle, mutilated "cervix"; ureter fistula??, brownish fluid type I fistula
EUO/"VCVF" 10 cm, "VCVF"/"C" 0 cm 148.5 cm

20/2-95 FOLEY Ch 18; free urine flow, EUO/BW 10 cm, moderate elevation, EUO/B 3 cm; gv check next week
normal bladder capacity (longitudinal diameter 10-3 = 7 cm)

24.07.95 incontinence ++ insp_gv/ minute fistula type I

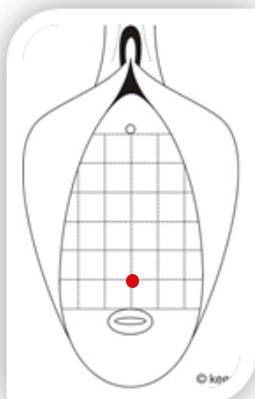
13/11-95 operation: VVF-repair vvf 1202

normal menstruation **no hysterectomy**

27.11.95 not leaking at all cath removed bladder drill

18.12.95 not leaking at all, no incontinence, normal miction
insp/ healed, poor elevation, no stress incontinence

16.01.96 not leaking at all, no incontinence, normal miction healed, no stress



small fistula

KANO

cath 360
RVF

hsut (kano) female 15 yr 27/02-95

diagnosis: PI, extensive \pm 6x2 cm **necrotic** urethrovesicovaginal fistula **IIBb**, \pm 1.5 cm **necrotic** proximal rectovaginal fistula at cervix, **leaking urine and passing stools per vaginam for 5 days** which started immediately following obstructed labor for 2 days, in hospital an SB male, married 1 yr ago post(menarche 6 mth earlier), not living with husband, no menstruation, no h/o drop foot (but R grade 3) narrow pubic angle, also necrosis at lateral/posterior vagina walls
EUO/F 1 cm, F/C 0 cm 157.0 cm

27/2-95 FOLEY Ch 18; free flow of urine, EUO/BW 12 cm, good elevation, EUO/B 4 cm; avw necrosis does not seem to be very deep so will it heal spontaneously??
normal bladder capacity (longitudinal diameter 12-4 = 8 cm)

14.03.95 leaking 2 cm fistula

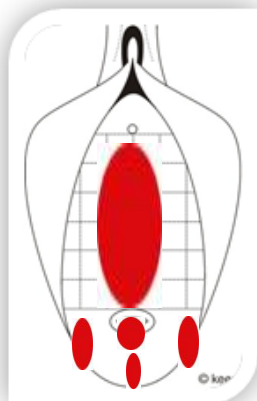
20/03-95 operation: circumferential UVVF-repair vvf 1003

03.04 + 18.04.95 not leaking at all cath removed bladder drill

24.04 + 22.05.95 not leaking, incontinence +, normal miction heales, stress +

30.07.95 not leaking at all, no incontinence, normal miction
insp/ healed, good elevation, no stress incontinence

02.10.95 not leaking at all, no incontinence, normal miction healed, no stress



6x2 cm

rnzh (kano city)

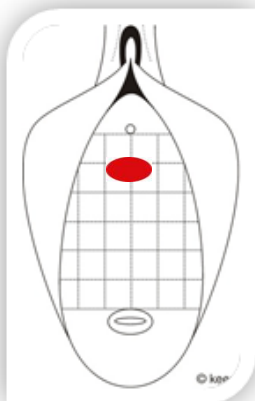
female 18 yr

27/02-95

diagnosis: PI, \pm 2x1 cm avw trauma **IIAa** with (stress) incontinence, **leaking urine day/night for 14 days** which started immediately following obstructed labor for 1 day, in hospital SB female, married 5 yr ago pre(menarche 5 mth later), not living with husband, no menstruation, no (h/o) drop foot, no RVF; narrow pubic angle
 EUO/AVWT 1.5 cm, AVWT/C 6 cm 161.5 cm

27/2-95 stress incontinence objectively demonstrated, FOLEY Ch 18; free urine flow, EUO/BW 12 cm, good elevation, EUO/B 3 cm
 normal bladder capacity (longitudinal diameter 12-3 = 9 cm)

13.03 + 26.03.95 not leaking at all cath removed bladder drill
 03.04.95 not leaking at all, no incontinence, normal miction
 insp/ healed, good elevation, no stress incontinence
 30.05.95 not leaking at all, no incontinence, normal miction healed, no stress



2x1 cm

hmska (benue)

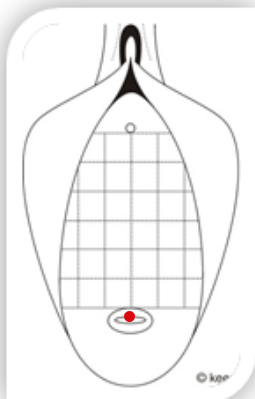
female 20 yr

27/02-95

diagnosis: PII (3 alive!), small vesicocervicovaginal fistula?, **leaking of urine for 55 days** which started immediately? (first she thought it was normal lochia, later she noticed it was urine) following CS b.c.o. obstructed last labor of 1 day, live male twins, married 4 yr ago post(menarche > 3 yr earlier), still living with husband, no menstruation, no h/o drop foot, no RVF; pubic angle normal, ureter fistula???, subtotal hysterectomy???, everything totally fixed intraabdominally
EUO/C 10 cm 168.0 cm

27/2-95 gv: no leakage, no urine in vaginae; FOLEY Ch 18, free flow of urine, EUO/BW 12 cm, good elevation, EUO/B 5 cm
normal bladder capacity (longitudinal diameter 12-5 = 7 cm)

22/03-95 80 ml gv/ no leakage but **clear urine in vaginae** ?ureter fistula?
for methylene blue



KANO

cath 363

bsww (kano city)

female

14 yr

06/03-95

diagnosis: PI, ± 2.5x1 cm necrotic urethrovesicovaginal fistula **IIAb** with seeping thru, **leaking of urine for 7 days** which started immediately following obstructed labor of 2 days, in hospital SB male, married 3 yr ago pre(menarche 2 yr later), still with husband, no menstruation, drop foot R (grade 2-3) and L (grade 4-5) and no RVF; normal pubic angle, open episiotomy R
 EUO/F 1.5 cm, F/C 7 cm 158.0 cm

06/03-95 FOLEY Ch 18; free flow of urine, EUO/BW 11 cm, good elevation, EUO/B 2.5 cm; will it heal spontaneously??
 normal bladder capacity (longitudinal diameter 11-2.5 = 8.5 cm)

13/03-95 **fistula**

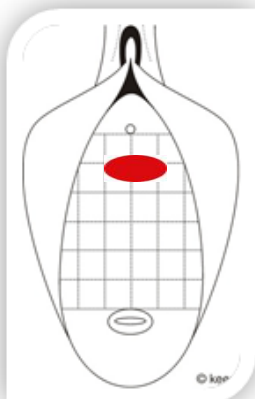
20/03-95 operation: circumferential UVVF-repair **vvf 1004**

03.04 + 18.04.95 not leaking at all cath removed bladder drill

24.04 + 22.05.95 not leaking, incontinence +, normal miction healed, stress +

18.07.95 not leaking at all, no incontinence, normal miction
 insp/ healed, good elevation, no stress incontinence

12.09.95 not leaking at all, no incontinence, normal miction healed, no stress



2.5x1 cm

hmmtm (kano city)

female

24 yr

14/03-95

diagnosis: PV (4 alive), ± 2 cm 0 urethrovesicovaginal fistula midline and R bladder neck **IIAa, leaking urine for 16 days which started 14 days** following obstructed last labor of 3 days, in hospital SB male, married 11 yr ago pre(menarche 5 mth later), still living with husband, no menstruation, no (h/o) drop foot, no RVF; a normal pubic angle, necrosis extirpation yesterday

EUO/F 2 cm, F/C 3 cm

161.0 cm

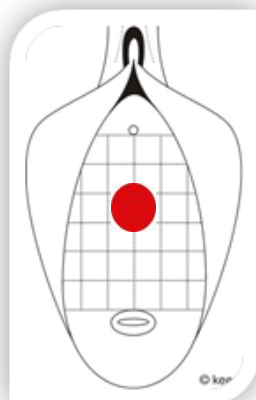
14/03-95 freshening, dissection, transverse bladder/urethra closure with inverting chromic catgut, transverse avw closure with everting chromic catgut and 3x supramid, FOLEY Ch 18, vagina pack; free flow of urine, EUO/BW 12 cm, good elevation, EUO/B 3 cm anesthetic normal bladder capacity (longitudinal diameter 12-3 = 9 cm)

10.04.95 not leaking at all cath removed bladder drill

18.04.95 not leaking at all, no incontinence, normal miction insp/ healed, good elevation, no stress incontinence

02.05 + 03.07.95 idem

12.09.95 not leaking at all, no incontinence, normal miction healed, no stress



2 cm

KANO

cath 365

ryigm (kano)

female

16 yr

24/04-95

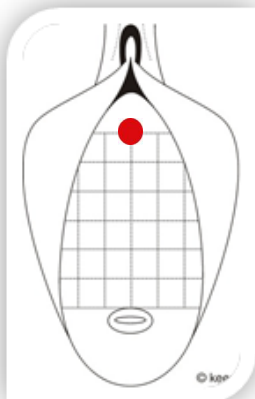
diagnosis: PI, stress incontinence ++, **leaking urine day/night when lying/sitting/standing/walking for 26 days which started 4 days** following obstructed labor of 1 day, in hospital live female, married 3 yr ago post(menarche 2 mth earlier), not living with her husband, no menstruation, no (h/o) drop foot, no RVF; a normal pubic angle 147.0 cm

24/4-95 FOLEY Ch 18; free urine flow, EUO/BW 11 cm, moderate elevation, EUO/B 4 cm
normal bladder capacity (longitudinal diameter 11-4 = 7 cm)

21.05 + 29.05.95 not leaking at all

30/05-95 gv: **no** leakage cath removed stress incontinence ++

12/06-95 not leaking at all, no incontinence, normal miction after bladder drill insp/ healed, good levation, stress incontinence \pm



KANO

cath 366

aahb (kano city)

female

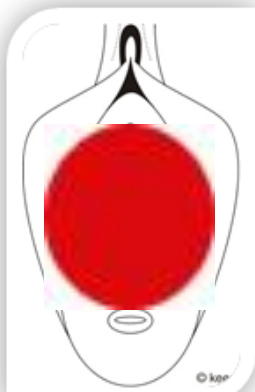15 yr

02/05-95

diagnosis: PI, overflow incontinence due to atonic bladder, **leaking urine for 2 days** which started immediately following obstructed labor for 1 day, in hospital SB female, married 2 yr ago pre(menarche 1 mth later), still living with husband, no menstruation, no h/ o drop foot (but R grade 4-5), no RVF; narrow pubic angle
avw completely bruised 161.5 cm

02/05-95 suprapubic mass, avw bulging into vagina, bladder overdistended (EUO/BW 19 cm), FOLEY Ch 18, > 1,000 ml urine, moderate to good elevation after drainage, EUO/B 3 cm
increased bladder capacity (longitudinal diameter 19-3 = 16 cm)

21.05 + 12.06.95 not leaking at all cath removed bladder drill
19.06.95 not leaking at all, no incontinence, normal miction
insp/ healed, good elevation, no stress incontinence
18.07.95 idem
12.09.95 not leaking at all, no incontinence, normal miction healed, no stress



total avwtrauma

hsya (kano city) female 16 yr 15/05-95

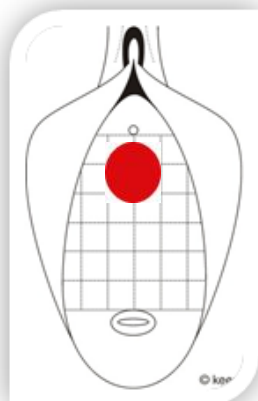
diagnosis: PI, overflow incontinence (also seeping through?) due to atonic bladder, ± 3 cm 0 "necrotic" avw trauma midline urethra/bladder neck, **leaking urine of 4 days which started 2 days** following an obstructed labor for 2 days, in hospital a live male which died almost immediately, married 11 mth ago post(menarche 2 yr earlier), still living with husband, no menstruation, no h/o drop foot (but R grade 4 and L grade 4), no RVF; narrow pubic angle EUO/AVWT 1 cm, AVWT/C 7 cm type **IIBa** 151.0 cm

15/5-95 suprapubic mass, avw bulging into vagina, bladder overdistended (EUO/BW 20 cm), FOLEY Ch 18, > 1,000 ml urine, moderate elevation after drainage, EUO/B 2 cm
increased bladder capacity (longitudinal diameter 20-2 = 18 cm)
probably it will become a fistula considering degree avw trauma

29/5-95 leaking, now ± 1 cm 0 distal urethrovesicovaginal fistula within 2 cm 0 avw defect **IIBa**; EUO/F 1 cm, AVW/C 6 cm

30/5-95 **primary suturing:** freshening, transverse bladder/urethra closure with inverting chromic catgut, transverse avw closure by everting chromic catgut/3x supramid, FOLEY Ch 18 and vagina pack; free urine flow, EUO/BW 10 cm, good elevation, EUO/B 2 cm anesthetic
normal bladder capacity (longitudinal diameter 10-2 = 8 cm)

24.06.95 not leaking at all cath removed bladder drill
03.07.95 not leaking at all, no incontinence, normal miction
insp/ healed, good elevation, no stress incontinence
18.07 + 22.08 + 25.09.95 idem
26.11.95 not leaking at all, no incontinence, normal miction healed, no stress



3 cm

aadt (kano city)

female

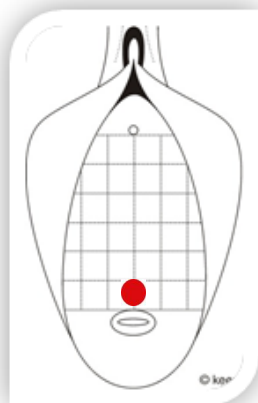
35 yr

17/05-95

diagnosis: PX (5 alive), \pm 1 cm 0 vesicovaginal fistula I (a 5 mm 0 bladder defect within 1 cm 0 avw defect), **leaking of urine for 42 days which started 7 days** following obstructed last labor of 2 days, in hospital a live female, married 25 yr ago pre(menarche 4 yr later), still living with husband, no menstruation, no (h/o) drop foot, no RVF; normal pubic angle, when seen 2/5-95 at 27-day duration still some necrosis
 EUO/F 8 cm, F/C 0 cm 155.0 cm

17/05-95 incision at fistula edge, sharp dissection, completely tension-free transverse bladder closure by single layer inverting chromic catgut, transverse avw closure by everting chromic catgut/3x supramid, foley ch 18, pack; free urine flow, euo/bw 10 cm, no elevation, euo/b 3.5 cm anesthetic moderate bladder capacity (long diameter 10-3.5 = 6.5 cm)

- 04.06 + 12.06.95 not leaking at all cath removed bladder drill
- 20.06.95 not leaking at all, no incontinence, normal miction
 insp/ healed, poor elevation, no stress incontinence
- 03.07 + 04.09.95 idem
- 30.10.95 not leaking at all, no incontinence, normal miction healed, no stress



1 cm

sumg (kano)

female

16 yr

17/05-95

diagnosis: PII (1 alive), \pm 2 cm 0 urethovesicovaginal fistula **IIBb** with circumferential defect, **leaking urine of 45 days** which started immediately following obstructed last labor of 1 day, in hospital SB female, married 4 yr ago post(menarche 3 mth earlier), not living with husband, no menstruation, no (h/o) drop foot, healed pvw trauma but no RVF; normal pubic angle, pressure ulcer at R sacrum
 EUO/F 1 cm, F/C 6 cm, AU/AB 1 cm 155.0 cm

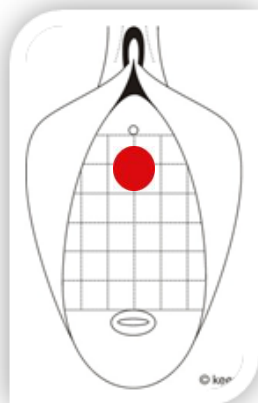
17/05-95 incision at fistula edge, sharp dissection of avw, completely tension-free transverse bladder/urethra closure by inverting chromic catgut (with adaptation of loose anterior bladder wall to "urethra" wall), transverse avw closure by everting chromic catgut/3x supramid, FOLEY Ch 18, pack; free urine flow, EUO/BW 11 cm, good elevation, EUO/B 1.5 cm anesthetic normal bladder capacity (longitudinal diameter 11-1.5 = 9.5 cm)

07/08-95 leaking & normal miction
 gv: EUO/BW 12 cm, moderate_good elevation, EUO/B 1 cm
 no leakage, stress/urge incontinence +
 total incontinence not responding to bladder drill

11/03-96 operation: colposuspension vfv 1256

01.04.96 not leaking at all cath removed bladder drill

07/06-97 not leaking, incontinence \pm , normal miction
 healed, good elevation, stress incontinence \pm



2 cm

KANO

cath 371

dism (kano city)

female

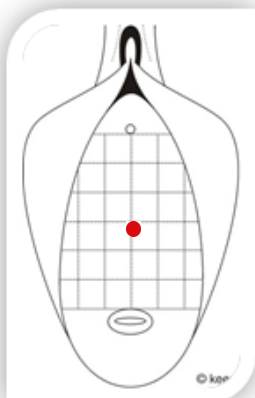
17 yr

22/05-95

diagnosis: PII (0 alive), \pm 3 mm 0 urethrovesicovaginal fistula midline **IIAa, leaking urine for 16 days** which started immediately following obstructed last labor for 2 days, in hospital SB male, married 4 yr ago pre(menarche 2 mth later), not living with husband, no menstruation, drop foot R (grade 3) and no RVF; normal pubic angle
 EUO/F 4 cm, F/C 3 cm 153.0 cm

22/05-95 transverse incision thru fistula, a sharp dissection of avw, transverse bladder/urethra closure by inverting chromic catgut, transverse avw closure by 3x everting supramid, FOLEY Ch 18 and vagina pack; free urine flow, EUO/BW 13 cm, moderate elevation, EUO/B 3 cm anesthetic
 normal bladder capacity (longitudinal diameter 13-3 = 10 cm)

12.06 + 20.06.95 not leaking at all cath removed bladder drill
 26.06.95 not leaking at all, no incontinence, normal miction
 insp/ healed, good elevation, no stress incontinence
 10.07 + 07.08 + 02.10.95 idem
 06.11.95 not leaking at all, no incontinence, normal miction healed, no stress



0.3 cm

KANO

cath 372

ajmj (kano)

female

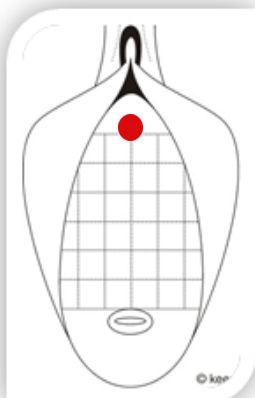
25 yr

04/06-95

diagnosis: PV (1 alive), overflow incontinence due to atonic bladder, **leaking urine of 18 days** which started immediately following obstructed last labor for 3 days, in hospital SB male, married 15 yr ago pre(menarche 6 yr later), still living with husband, no menstruation, no h/o drop foot (but R grade 4 and L grade 4), no RVF; normal pubic angle, CS for delivery IV 153.0 cm

04/06-95 suprapubic mass, avw bulging into vagina, bladder overdistended (EUO/BW 19 cm), > 2,000 ml urine, EUO/B 2.5 cm, good elevation after draining
increased bladder capacity (long diameter 19-2.5 = 16.5 cm)

25.06 + 17.07.95 not leaking at all cath removed bladder drill
04/09-95 not leaking at all, no incontinence, normal miction
insp/ healed, good elevation, no stress incontinence



KANO

cath 373

dmkd (kano city)

female

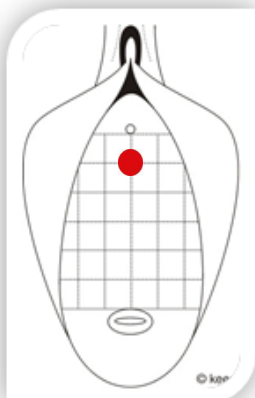
15 yr

12/06-95

diagnosis: PI, ± 1 cm 0 urethrovesicovaginal fistula **IIAa, leaking urine for 58 days that started 10 days** following obstructed labor of 2 days, at home a SB female, married 3 yr ago pre(menarche 1 yr later), not living with husband, no menstruation, no h/o drop foot (but both grade 4), no RVF; narrow pubic angle
 EUO/F 1 cm, F/C 6 cm 153.5 cm

12/06-95 incision at fistula edge, sharp dissection, transverse bladder/ urethra closure with inverting chromic catgut, a transverse avw closure by 3x everting supramid, FOLEY Ch 18 and pack; free urine flow, EUO/BW 12 cm, moderate elevation, EUO/B 2 cm anesthetic
 normal bladder capacity (longitudinal diameter 12-2 = 10 cm)

26.06 + 10.07.95 not leaking at all cath removed bladder drill
 17.07.95 not leaking at all, no incontinence, normal miction
 insp/ healed, moderate elevation, no stress incontinence
 16.11.95 not leaking at all, no incontinence, normal miction healed, no stress



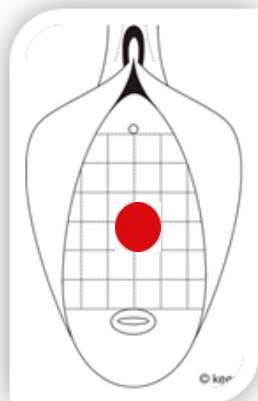
1 cm

haj (taraba) female 26 yr 12/06-95

diagnosis: PI, \pm 2 cm 0 urethrovesicovaginal fistula **IIAb** with minimal circumferential defect, **leaking urine for 41 days** which started immediately following obstructed labor for 2 days, in hospital a SB male, married 13 yr ago post(menarche 5 mth earlier), still living with husband, no menstruation, no (h/o) drop foot, no RVF; narrow pubic angle, pvw stricture; on 4/6-95 still necrosis \pm
EUO/F 2.5 cm, F/C 2 cm, AU/AB 0.2 cm 162.0 cm

12/06-95 incision at fistula edge, sharp dissection, transverse bladder/urethra closure by inverting chromic catgut, transverse avw closure by everting chromic catgut/5x supramid, FOLEY Ch 18, pack; free urine flow, EUO/BW 11 cm, good elevation, EUO/B 2.5 cm anesthetic
normal bladder capacity (longitudinal diameter 11-2.5 = 8.5 cm)

26.06 + 10.07.95 not leaking at all cath removed bladder drill
17.07.95 not leaking at all, no incontinence, normal miction
insp/ healed, good elevation, no stress incontinence
07.08 + 10.10 + 27.11.95 idem
09.01.96 not leaking at all, no incontinence, normal miction healed, no stress



2 cm

KANO

cath 375

bhb (kano city)

female

16 yr

12/06-95

diagnosis: PI, overflow due to atonic bladder with seeping thru?? necrotic \pm 1 cm 0 - urethrovesicovaginal fistula?? L bladder neck **IIAa, leaking urine for 15 days which started 3 days** following an obstructed labor for 1 day, in hospital SB male, married 3 yr ago pre(menarche 2 mth later), not living with husband, no menstruation, no (h/o) drop foot, no RVF; narrow pubic angle

EUO/"F" 2 cm, "F"/C 7 cm

159.0 cm

12/06-95 no suprapubic mass, avw bulging into the vagina, bladder overdistended (EUO/BW 14 cm), \pm 500 ml urine, EUO/B 2 cm, good elevation after draining

FOLEY Ch 18

increased bladder capacity (longitudinal diameter 14-2 = 12 cm)

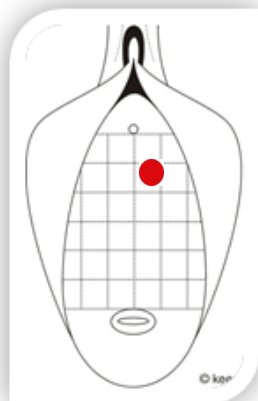
will it heal or will it become a fistula????

02.07 + 24.07.95 not leaking at all cath removed bladder drill

22.08.95 not leaking at all, no incontinence, normal miction
insp/ healed, good elevation, no stress incontinence

16.10.95 idem

09.01.96 not leaking at all, no incontinence, normal miction healed, no stress



1 cm

KANO

cath 376

study this patient carefully; see later developments 10.05.13

juk (kano city) female 14 yr 02/07-95

diagnosis: PI, atonic bladder in the healing phase??, **leaking urine for 60 days (2 mth)** which started immediately following CS b.c.o. obstructed labor for 2 days, live female which died 1 day later, married 1 yr ago post (menarche 3 mth earlier), not living with husband, no menstruation, no RVF, drop foot R (grade 4-5) and L (grade 4); narrow pubic angle, dribbling of urine from the EUO without stress 147.5 cm

02/07-95 FOLEY Ch 14; free urine flow, EUO/BW 14 cm, good elevation and EUO/B 4 cm gv check before catheter removal!
normal bladder capacity (longitudinal diameter 14-4 = 10 cm)

16.07 + 14.08.95 not leaking at all cath removed bladder drill

29/10-95 leaking & normal miction **strange 0.3 cm 0 fistula IIAa midline**
06/11-95 operation: UVVF-repair vvf 1193

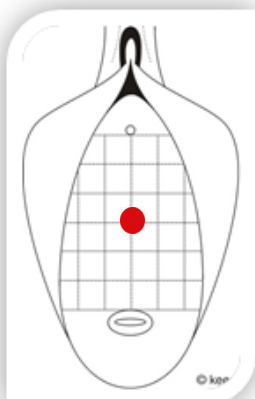
20.11.95 not leaking at all cath removed bladder drill

24/11-96 not leaking, incontinence ±, normal miction
insp/ healed, moderate elevation, no stress incontinence

second obstetric leakage PV (2 alive) sb male in hosp **cath aahaf**
20.07.05 operation: urethralization/fascia fixation vvf 3423

07.08 + 21.08.05 not leaking at all cath removed bladder drill

07.09.05 not leaking at all, no incontinence, normal miction
Insp/ healed, good elevation, no stress incontinence



kskr (kano city)

female

15 yr

02/07-95

diagnosis: PI, stress incontinence ++, **leaking of urine for 12 days which started 3 days** following obstructed labor for 1 day, in hospital a live male, married 2 yr ago post(menarche 1 mth earlier), still living with husband, no menstruation, no RVF, drop foot R (grade 4) and L (grade 4); narrow pubic angle 164.0 cm

02.07.95 **objective stress ++**; FOLEY Ch 18; free urine flow, EUO/BW 12 cm, good elevation and EUO/B 3 cm; no avw trauma
normal bladder capacity (longitudinal diameter 12-3 = 9 cm)

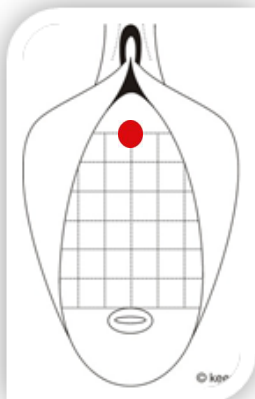
gv check before catheter removal!

16.07 + 31.07.95 not leaking insp_gv/ healed cath removed blad drill

07.08.95 not leaking at all, no incontinence, normal miction
insp/ healed, good elevation, no stress incontinence

04.09.95 idem

30.10.95 not leaking at all, no incontinence, normal miction healed, no stress



KANO

cath 378

kmhk (kano)

female

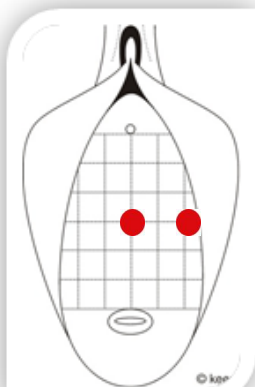
27 yr

03/07-95

diagnosis: PV (2 alive), \pm 1 cm 0 vesicovaginal fistula L bladder neck **IIAa** and avw trauma midline, **leaking of urine for 35 days** which started 5 days following obstructed last labor for 1 day, in hospital a SB male, married 15 yr ago pre(menarche 1 yr later), not living with husband, drop foot R (grade 1-2) and L (grade 2), no RVF; normal pubic angle, pat needs support whilst standing/walking
 EUO/F 4 cm, F/C 3 cm 152.0 cm

03/07-95 incision at fistula edge, sharp dissection of avw, transverse bladder closure with inverting chromic catgut, transverse avw closure with 3x everting supramid, FOLEY Ch 18 and pack; free urine flow, EUO/BW 10 cm, moderate elevation, EUO/B 3 cm avw trauma will heal spontaneously
anesthetic
 normal bladder capacity (longitudinal diameter 10-3 = 7 cm)

17.07 + 11.08.95 not leaking at all cath removed bladder drill
 18.09.95 not leaking at all, no incontinence, normal miction **needs support**
 insp/ healed, moderate elevation, no stress incontinence
 06.11.95 not leaking at all, no incontinence, normal miction healed, no stress
pat still needs support



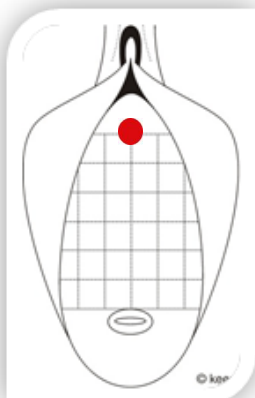
multiple trauma

zad (jigawa) female 16 yr 10/07-95

diagnosis: PI, stress incontinence + (atonic bladder in healing phase?), leaking urine for 3 mth which started immediately following obstructed labor for 3 days, at home live male which died 5 days later, married 4 yr ago pre(menarche 1 yr later), not living at husband, normal menstruation, drop foot L (grade 4); narrow pubic arch, avw bulging into vagina 148.0 cm

10/7-95 FOLEY Ch 18; free urine flow, EUO/BW 12 cm (bladder not over-distended), no elevation, EUO/B 3 cm
normal bladder capacity (longitudinal diameter 12-3 = 9 cm)

30.07 + 21.08.95	not leaking at all	cath removed	bladder drill
04.09.95	not leaking at all, no incontinence, normal miction		healed, stress ++
11.09.95	not leaking at all, no incontinence, normal miction		after bladder drill
	insp/	healed, good elevation, no stress incontinence	
23.10.95	idem		
09.01.96	not leaking at all, no incontinence, normal miction		healed, no stress



KANO

cath 380

haiw (kano) female 36 yr 16/07-95

diagnosis: PIX (5 alive), ± 6x1 cm **necrotic** urethrovesicovaginal fistula **IIAa** at R, **leaking urine for 13 days** which started immediately after CS b.c.o. obstructed last labor for 2 days, SB male, married 25 yr ago pre(menarche 2 yr later), still living with husband, no menstruation, no (h/o) drop foot, no RVF; normal pubic arch, pt comes with catheter Ch 16 in situ
EUO/F 2 cm, F/C 0 cm 157.5 cm

16/7-95 too early for extirpation; EUO/BW 12 cm, good elevation, EUO/B 4 cm, free urine flow thru catheter, to cleanse properly, leave catheter normal bladder capacity (longitudinal diameter 12-4 = 8 cm)

23/7-95 not leaking at all; insp/ surprisingly it is almost healed!! so this will heal spontaneously

21/08-95 leaking **fistula**

04/09-95 operation: VVF-repair vvf 1112

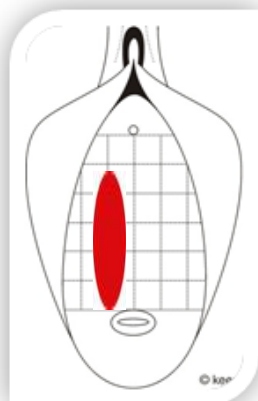
18.09 + 02.10.95 not leaking at all cath removed bladder drill

16.10.95 not leaking at all, no incontinence, normal miction
insp/ healed, good elevation, no stress incontinence

30.10 + 27.11 + 23.01.96 idem

26.02.96 not leaking at all, no incontinence, normal miction healed, no stress

18/11-96 **amenorrhea for 4 mth** not leaking at all **instructions**



6x1 cm

KANO
atypical atonic bladder

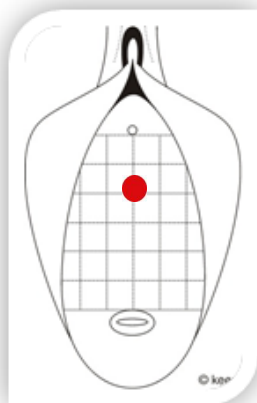
cath 381

barb (kano city) female 15 yr 23/07-95

diagnosis: PI, overflow incontinence due atonic bladder, **leaking urine for 7 days** which started immediately following obstructed labor for 2 days, in hospital (eclampsia) an SB female, married 1 yr ago post(menarche 1 yr earlier), not living with husband, no menstruation, no h/o drop foot (but both grade 4), no RVF; borderline pubic arch, \pm 1x0.5 cm avw trauma midline UV-junction **IIAa**
EUO/AVWT 2 cm, AVWT/C 5 cm 161.0 cm

23/7-95 no suprapubic mass, avw bulging into vagina, the bladder overdistended (EUO/BW 17 cm) but not overfilled, urine < 500 ml, no elevation after drainage, EUO/B 3 cm
increased bladder capacity (longitudinal diameter 17-3 = 14 cm)

21.08 + 04.09.95 not leaking at all cath removed bladder drill
18.09.95 not leaking at all, no incontinence, normal miction
insp/ healed, good elevation, no stress incontinence
16.10.95 idem
19.12.95 not leaking at all, no incontinence, normal miction healed, no stress



1x0.5 cm

dimk (kano city)

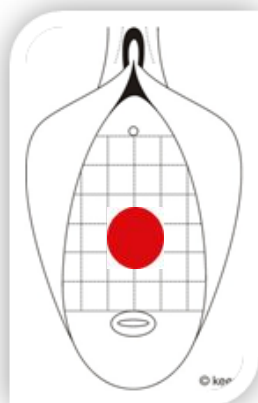
female 15 yr

14/08-95

diagnosis: PI, ± 3 cm 0 necrotic urethrovesicovaginal fistula **IIAa** at midline, **leaking urine for 12 days which started 2 days** following an obstructed labor of 4 days, in hospital SB male, married 2 yr ago pre(menarche 1 mth later), still living with husband, no menstruation, drop foot R (grade 4) and L (grade 3), no RVF; narrow pubic arch
 EUO/F 4 cm, F/C 2 cm 145.0 cm

14/8-95 FOLEY Ch 18 already in situ for 5 days; free urine flow, EUO/BW 15 cm, moderate elevation, EUO/B 4 cm
 increased bladder capacity (long diameter 15-4 = 11 cm, atonic bladder??)

17.09.95 catheter out x 1/7 not leaking at all bladder drill
 02.10.95 not leaking at all, no incontinence, normal miction
 insp/ healed, good elevation, no stress incontinence
 30.10 + 09.01.96 idem
 11.03.96 not leaking at all, no incontinence, normal miction healed, no stress



3 cm

bmss (kano city)

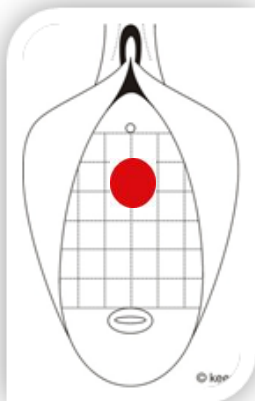
female 17 yr

14/08-95

diagnosis: PI, \pm 2.5 cm necrotic urethrovesicovaginal fistula **IIAa** at midline, **leaking urine for 5 days which started 16 days** following an obstructed labor for 2 days, in hospital a SB male, married 4 yr ago pre(menarche 3 mth later), not living with husband, no RVF, drop foot R (grade 2) and L (grade 2); narrow pubic arch
 EUO/F 2 cm, F/C 6 cm 152.0 cm

14/8-95 FOLEY Ch 18; free urine flow, EUO/BW 14 cm, moderate elevation, EUO/B 4 cm
 normal bladder capacity (longitudinal diameter 14-4 = 10 cm)

11.09.95 did not report until now gv: **no** leakage, still 1 cm avw trauma
 25.09.95 not leaking at all insp_gv/ healed cath removed bladder drill
 16/10-95 not leaking at all, no incontinence, normal miction
 insp/ healed, good elevation, no stress incontinence



2.5 cm

KANO

cath 385
rvf

fsamt (kano city) female 20 yr 14/08-95

diagnosis: PIV (3 alive), extensive necrotic **IIBa** avw/pvw trauma, **leaking urine for 5 days which started 5 days** (upon catheter removal) following CS b.c.o. obstructed last labor for 1 day, SB male, married 8 yr ago pre(menarche 1 yr later), still living at husband, no (h/o) a drop foot; normal pubic angle EUO/C 12 cm, EUO/AVWT 0 cm, AVWT/C 0 cm 155.0 cm

14/8-95 suprapubic mass, avw bulging into vagina, bladder overdistended (EUO/BW 16 cm), urine > 1500 ml, moderate elevation after draining, EUO/B 2.5 cm FOLEY Ch 18
increased bladder capacity (long diameter of 16-2.5 = 13.5 cm, atonic bladder)
will it heal or will it become a fistula

04/09-95 ± 1.5 cm avw defect R bladder neck **IIAa**, EUO/AVWD 3 cm, AVWD/C 6 cm; and ± 1 cm pvw defect, I/PVWD 10 cm, PVWD/C 2 cm; not leaking!

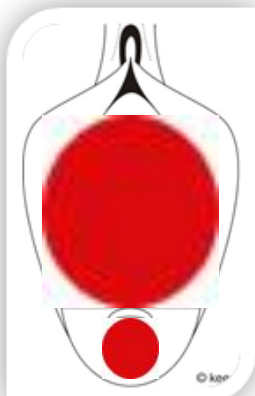
26/9-95 0.5 cm 0 urethrovesicovaginal fistula R bladder neck; incision at fistula edge, sharp dissection, a transverse bladder/urethra closure by inverting chromic catgut, transverse avw closure by everting chromic catgut/3x supramid, FOLEY Ch 18, pack; free urine flow, EUO/BW 13 cm, good elevation, EUO/B 3 cm anesthetic
normal bladder capacity (longitudinal diameter 13-3 = 10 cm)

08.10 + 24.10.95 not leaking at all cath removed bladder drill

30.10.95 not leaking at all, no incontinence, normal miction insp/ healed, moderate elevation, no stress incontinence

13.11 + 19.12.95 idem

13.02.96 not leaking at all, no incontinence, normal miction healed, no stress



total avw/pvw trauma

rssmt (kano city)

female

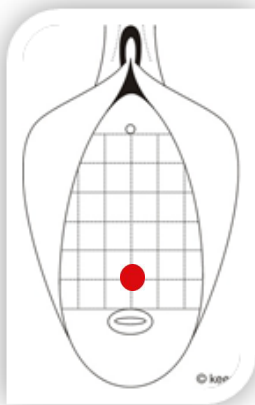
21 yr

03/09-95

diagnosis: PIII (2 alive), \pm 5 mm 0 avw trauma I midline bladder base with seeping thru, **leaking urine of 10 days** that started immediately following obstructed last labor for 4 days, in hospital a live female, married 10 yr ago pre(menarche 1 yr later), not living at her husband, drop foot R (grade 2) and L (grade 4), no RVF; normal pubic arch, pressure ulcers over patella (due to squatting at traditional childbirth)
 EUO/AVWT 7 cm, AVWT/C 1 cm 146.0 cm

03.09.95 FOLEY Ch 18; free urine flow, EUO/BW 11 cm, moderate elevation, EUO/B 4 cm; probably it will heal spontaneously
 normal bladder capacity (longitudinal diameter 11-4 = 7 cm)

18.09 + 08.10.95 not leaking at all cath removed bladder drill
 16/10-95 not leaking at all, no incontinence, normal miction
 insp/ healed, moderate elevation, no stress incontinence



0.5 cm

KANO
fistula and atonic bladder

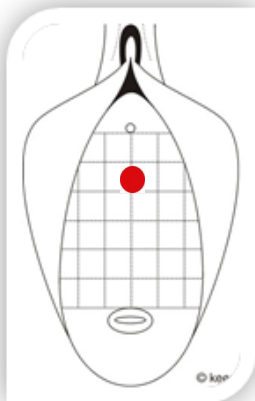
cath 387

fssk (jigawa) female 15 yr 04/09-95

diagnosis: PI, \pm 1 cm 0 urethrovesicovaginal fistula **IIAa** midline, **leaking urine for 60 days (2 mth)** which started 1 day following obstructed labor for 3 days, in hospital live male, married 2 yr ago pre(menarche 5 mth later), not living with husband, no menstruation, drop foot R (grade 2) and L (grade 4), no RVF; a borderline pubic arch, no suprapubic mass, bladder not overfilled
EUO/F 2 cm, F/C 6 cm 158.0 cm

04/09-95 incision at fistula edge, sharp dissection of avw, transverse bladder/urethra closure by inverting chromic catgut, transverse avw closure by everting chromic catgut/3x supramid, FOLEY Ch 18, vagina pack; free urine flow, good elevation, EUO/B 2 cm anesthetic increased bladder capacity (long diameter 16-2 = 14 cm, atonic bladder!)

24.09 + 16.10.95 not leaking at all cath removed bladder drill
24.10.95 not leaking at all, no incontinence, normal miction
insp/ healed, good elevation, no stress incontinence
30.10 + 27.11.95 idem
04.03.96 not leaking at all, no incontinence, normal miction healed, no stress



1 cm

KANO
nb atonic bladder for 2 years!!

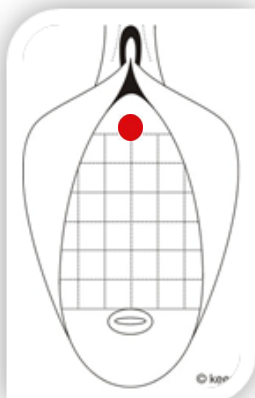
cath 388

hitw (kano city) female 17 yr 08/10-95

diagnosis: PII (2 alive), overflow incontinence (no micturition!!!) due to atonic bladder, leaking urine for 2 yr that started 2 days following obstructed first labor for 2 days, at home live female, marroied 4 yr ago post(menarche 3 mth earlier), still living at husband, normal menstruation, no RVF, drop foot R (grade 4) and L (grade 4); normal pubic arch 160.0 cm

8/10-95 suprapubic mass, avw indurated/bulging into the vagina, bladder overdistended, EUO/BW 18 cm, no elevation after draining >1,000 ml urine, EUO/B 2 cm
increased bladder capacity (long diameter 18-2 = 16 cm)
photographic documentation!

29.10 + 26.11.95 not leaking at all cath removed bladder drill
18.12.95 not leaking at all, no incontinence, normal miction
insp/ healed, moderate elevation, no stress incontinence
29.12.95 not leaking at all, no incontinence, normal miction healed, no stress



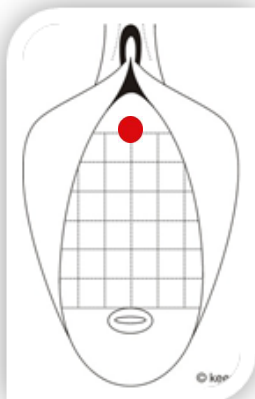
atonic bladder 2 mth before delivery???

bht (kano) female 18 yr 08/10-95

diagnosis: PI, overflow incontinence due to atonic bladder (also spontaneous micturition), **leaking urine now for 40 days** that started 30 days following labor for 1 day, at home live female, married 4 yr ago post (menarche 7 mth earlier), not living at husband, no menstruation, drop foot R (grade 4) and L (grade 4) and no RVF; normal pubic arch 156.0 cm
N.B. total period of leaking urine now 4 mth which started when she was 7 mth pregnant; it subsided after delivery and returned 30 days after delivery

8/10-95 small suprapubic mass, avw indurated/bulging into vagina, bladder overdistended, EUO/BW 15 cm, moderate elevation after draining > 500 ml urine, EUO/B 3 cm
increased bladder capacity (longitudinal diameter 15-3 = 12 cm)

29.10 + 29.11.95 not leaking at all cath removed bladder drill
28/11-95 not leaking at all, no incontinence, normal miction
insp/ healed, good elevation, no stress incontinence
06/05-97 not leaking at all, no incontinence, normal miction
insp/ healed, good elevation, no stress incontinence



atonic bladder in spontaneous healing phase??

unks (kano city) female 15 yr 29/10-95

diagnosis: PI, stress incontinence +, **leaking urine only on standing/walking for 14 days** which started immediately following vacuum extraction b.c.o. obstructed labor for 1 day, SB female, married 2 yr ago pre(menarche 3 mth later), still living with husband, no menstruation, no (h/o) drop foot, no RVF; a borderline pubic arch, ± 5 mm 0 superficial avw trauma **IIAa**, no suprapubic mass; pat had indwelling catheter for 7 days, eclampsia
EUO/AVWT 4 cm, AVWT/C 4 cm 159.0 cm

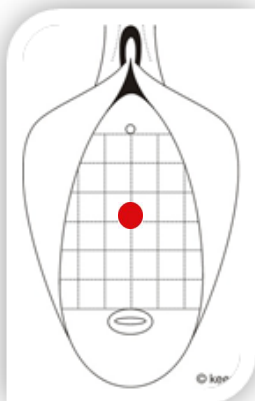
29/10-95 FOLEY Ch 18; free flow of urine, EUO/BW 10 cm, no elevation/avw bulging into vagina, EUO/B 2 cm
normal bladder capacity (longitudinal diameter 10-2 = 8 cm)

13.11 not drinking + 26.11.96 not leaking at all cath removed bladder drill

28.11.96 not leaking at all, no incontinence, normal miction
insp/ healed, good elevation, no stress incontinence

19.12 + 15.01 + 26.02.96 idem

24.04.96 not leaking at all, no incontinence, normal miction healed, no stress



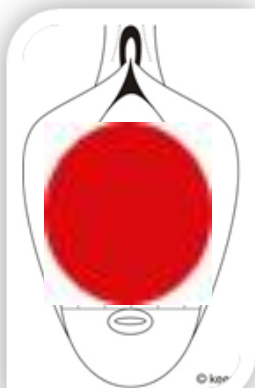0.5 cm

kmsr (jigawa) female 42 yr 31/10-95

diagnosis: PVIII (3 alive), overflow incontinence due to atonic bladder and necrotic 3E perineum tear, **leaking urine/stool incontinence for 3 days** which started immediately following obstructed last labor for 1 day, in hospital (hanging breech) SB male, married 30 yr ago pre(menarche 1 yr later), still living with husband, no menstruation, drop foot R (grade 2) and L (grade 2); normal pubic arch, total avw/pvw trauma **IIBa** (necrosis??), obesity +++++
EUO/AVWT 0 cm, AVWT/C 0 cm, EUO/C 12 cm 164.0 cm

31/10-95 suprapubic mass?? (obesity +++++), avw not bulging into vagina (too early??), bladder overdistended (EUO/BW 25 cm!!) and overfilled (>1500 ml urine), moderate elevation after draining and EUO/B 2.5 cm; FOLEY Ch 18, free urine flow
increased bladder capacity (long diameter 25-2.5 = 22.5 cm!!!, atonic bladder) probably it will not become fistula
full photographic documentation

- 05.11.95 not leaking at all it will become fistula **documentation**
- 12.11.95 not leaking at all looks far better except for laterally **documentation**
- 20.11.95 not leaking at all almost healed, no fistula
- 26.11 + 07.01.96 not leaking at all cath removed bladder drill
- 28/01-96 not leaking at all, no incontinence, normal miction
insp/ healed, good elevation, no stress incontinence



total avw trauma

hhk (kano city)

female

15 yr

12/11-95

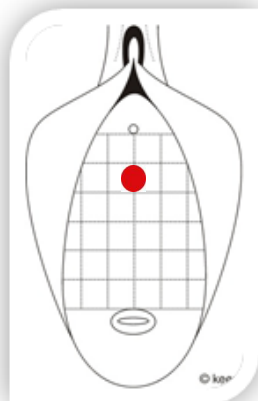
diagnosis: PI, ± 1 cm 0 urethrovesicovaginal fistula **IIAa** midline, **leaking urine for 16 days which started 2 days** following obstructed labor for 3 days, in hospital SB female, married 2.5 yr ago pre(menarche 5 mth later), not living with husband, no menstruation, no h/o drop foot (but R grade 4-5), no RVF; normal pubic arch, when seen 29/10-95 balloon in necrotic fistula

EUO/F 1.5 cm, F/C 5 cm

157.0 cm

12/11-95 incision at fistula edge, sharp dissection of avw, transverse bladder/ urethra closure by inverting chromic catgut, transverse avw closure by everting chromic catgut/3x supramid, FOLEY Ch 18 vagina pack; free urine flow, EUO/BW 10 cm, good elevation and EUO/B 2 cm anesthetic normal bladder capacity (longitudinal diameter 10-2 = 8 cm)

- 19.12 + 02.01.96 not leaking at all cath removed bladder drill
- 07.01.96 not leaking at all, no incontinence, normal miction insp/ healed, good elevation, no stress incontinence
- 04.03.96 idem
- 20.05.96 not leaking at all, no incontinence, normal miction



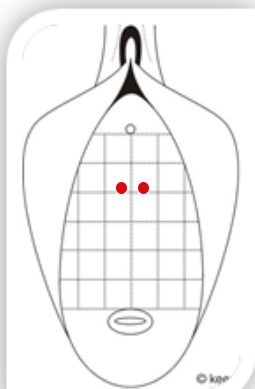
1 cm

hsit (kano) female 16 yr 18/12-95

diagnosis: PI, two minute \pm 1 mm 0 urethrovesicovaginal fistulas? **IIAa** midline, **lea-king urine for 4 days that started 7 days** following obstructed labor for 2 days, in hospital SB female, married 3 yr ago pre(menarche 2 mth later), not living with husband, no h/o drop foot (but L grade 4), no menstruation, no RVF; no stress incontinence, vulva wet; normal pubic arch; eclampsia EUO/F 3 cm, F/C 6 cm 158.0 cm

18/12-95 FOLEY Ch 18; free urine flow, EUO/BW 14 cm, moderate elevation, EUO/B 4 cm
normal bladder capacity (longitudinal diameter 14-4 = 10 cm)

29.01.96 not leaking at all healed cath removed bladder drill
12.02.96 not leaking at all, no incontinence, normal miction
insp/ healed, good elevation, no stress incontinence
11.03 + 06.05.96 idem
02.06.96 not leaking at all, no incontinence, normal miction healed, no stress



multiple fistulas

KANO

cath 396

askw (kano)

female

30 yr

02/01-96

diagnosis: PVIII (4 alive), ± 2 cm 0 necrotic urethrovesicovaginal fistula midline **IIAa**, **leaking urine for 2 days which started 10 days** following an obstructed last labor for 2 days, in hospital live male, married 20 yr ago pre(menarche 3 yr later), still living with husband, no menstruation, drop foot R (grade 2) and L (grade 3) no RVF; normal pubic arch
EUO/F 2.5 cm, F/C 4 cm 150.0 cm

02/01-96 FOLEY Ch 18; free urine flow, EUO/BW 11 cm, moderate elevation, EUO/B 4 cm will it heal spontaneously??
normal bladder capacity (longitudinal diameter 11-4 = 7 cm)

29/1-96 still leaking; insp/ 1 cm 0 UVVF; EUO/F 2.5 cm, F/C 4 cm

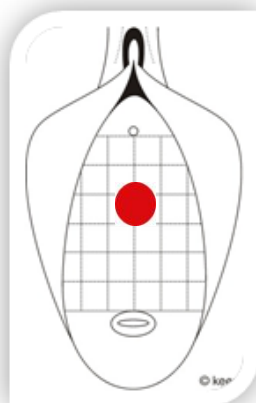
30/1-96 incision at fistula edge, sharp dissection, transverse bladder/urethra closure with inverting chromic catgut, a transverse avw closure with everting chromic catgut/3x supramid, FOLEY Ch 18, vagina pack; free urine flow, EUO/BW 11 cm, moderate elevation, EUO/B 3 cm anesthetic
normal bladder capacity (longitudinal diameter 11-3 = 8 cm)

13.02 + 26.02.96 not leaking at all cath removed bladder drill

03.03.96 not leaking at all, no incontinence, normal miction
insp/ healed, good elevation, no stress incontinence

25.03.96 idem

25.06.96 not leaking at all, no incontinence, normal miction healed, no stress



2 cm

KANO

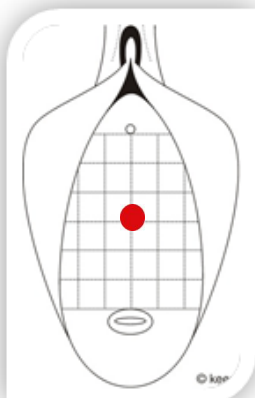
cath 397

hub (kano) female 41 yr 08/01-96

diagnosis: PIX (6 alive), \pm 5 mm 0 avw **IIAa** defect (with seeping thru?) midline **leaking urine for 34 days** which started immediately following a CS b.c.o. obstructed last labor for 3 days, SB male, married 30 yr ago pre(menarche 2 yr later), still living with husband, no h/o drop foot (but L grade 4), no menstruation, no RVF; normal pubic arch
EUO/AVWT 4 cm, AVWT/C 4 cm 157.0 cm

08/01-96 FOLEY Ch 18; free urine flow, EUO/BW 13 cm, moderate elevation, EUO/B 4 cm
normal bladder capacity (longitudinal diameter 13-4 = 9 cm)

29/1-96 leaking; 100 ml gv: no leakage cave ureter fistula!!
05.02.96 not leaking, incontinence cath removed bladder drill
12.02 + 26.02.96 leaking \pm & miction healed, no stress vaginal discharge
11.03.96 not leaking at all, no incontinence, normal miction after bladder drill
insp/ healed, moderate elevation, no stress incontinence
06.05.96 idem
02.06.96 not leaking at all, no incontinence, normal miction healed, no stress



0.5 cm

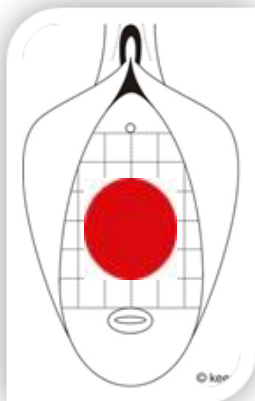
mmfl (kano city) female 32 yr 08/01-96

diagnosis: PIX (6 alive), overflow incontinence due to atonic bladder, **leaking urine for 16 days** that started 1 day following obstructed last labor for 2 days, in hospital SB female, married 21 yr ago pre(menarche 2 yr later), not living with husband, no menstruation, drop foot R (grade 2), no RVF; normal pubic arch, an extensive 5 cm 0 avw **IIAa** trauma (but no fistula yet!)
EUO/AVWT 2 cm, AVWT/C 1 cm 168.0 cm

08/01-96 suprapubic mass, avw bulging into vagina, bladder overdistended (EUO/BW 17 cm), no elevation after draining > 1,000 ml urine, EUO/B 3 cm
will it become fistula??
increased bladder capacity (long diameter 17-3 = 14 cm)

29/1-96 not leaking at all; insp/ still ± 4 cm 0 healing avw trauma; it will probably heal spontaneously, photographic **documentation!**
EUO/AVWT 3 cm, AVWT/C 4 cm

06.02 + 26.02.96 **documented** not leaking at all cath removed
10.03.96 not leaking, incontinence ±, normal miction healed, no stress
25.03.96 not leaking at all, no incontinence, normal miction
insp/ healed, moderate elevation, no stress incontinence
02.06.96 not leaking at all, no incontinence, normal miction healed, no stress



5 cm

hmmr (kano city)

female

16 yr

30/01-96

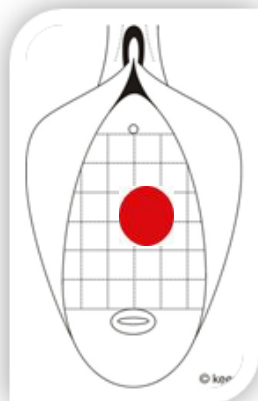
diagnosis: PII (0 alive), extensive \pm 1.5 cm 0 urethrovesicovaginal fistula **IIAa** midline/L, **leaking of urine for 22 days** which started 7 days (upon catheter removal) following a repeat CS b.c.o. obstructed last labor for 3 days, SB female, married 3 yr ago pre(menarche 2 mth later), still living with husband, drop foot R (grade 3) and L (grade 4), no RVF; narrow pubic arch

EUO/F 1.5 cm, F/C 1.5 cm

145.0 cm

30/01-96 incision at fistula edge, sharp dissection of avw, completely tension-free transverse bladder/urethra closure with a single layer of inverting chromic catgut, FOLEY Ch 18, transverse avw closure with everting chromic catgut/3x supramid, vagina pack; free flow of urine, EUO/BW 11 cm, good elevation, EUO/B 2.5 cm anesthetic normal bladder capacity (longitudinal diameter 11-2.5 = 8.5 cm)

- 13.02 +26.02.96 not leaking at all cath removed bladder drill
- 03.03.96 not leaking at all, no incontinence, normal miction
insp/ healed, good elevation, no stress incontinence
- 06.05 + 02.06.96 idem
- 22.07.96 not leaking at all, no incontinence, normal miction healed, no stress



1.5 cm

KANO

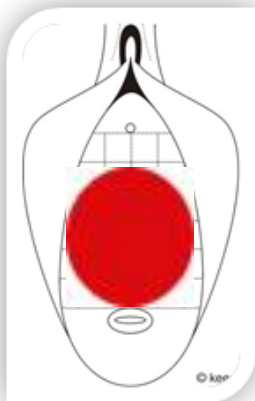
cath 400

bkgd (kano) female 15 yr 09/01-96

diagnosis: PI, overflow incontinence due to atonic bladder, **leaking urine for 10 days** which started 1 day following obstructed labor for 1 day, at home SB female, married 3 yr ago pre(menarche 10 mth later), still living with husband, no menstruation, no h/o drop foot (but both grade 4), no RVF; narrow pubic arch, 6 cm 0 "**necrotic**" avw **IIAa** trauma but no fistula (yet) EUO/AVWN 2 cm, AVWN/C 0 cm 155.0 cm

09/01-96 suprapubic mass, avw bulging into vagina, bladder overdistended (EUO/BW 19 cm), no elevation after draining > 1000 ml urine and EUO/B 3 cm; FOLEY Ch 18 will it become fistula? increased bladder capacity (longitudinal diameter 19-3 = 16 cm)

29.01 not leaking + 12.02.96 cath out x 1/7 not leaking at all, normal miction
28.02.96 not leaking at all, no incontinence, normal miction
insp/ healed, good elevation, no stress incontinence
11.03 + 13.05.96 idem
15.06.96 not leaking at all, no incontinence, normal miction healed, no stress



6 cm

KANO
age at menarche: 13 yr

cath 401

zabg (kano city) female 15 yr 27/11-95

diagnosis: PI, overflow incontinence due to atonic bladder, **leaking urine for 60 days (2 mth)** that started immediately following obstructed labor for 1 day, at home SB female, no menstruation, no RVF no (h/o) drop foot; narrow pubic arch, ± 4 cm 0 avw trauma type **IIAa**
EUO/AVWT 2 cm, AVWT/C 4 cm 153.0 cm

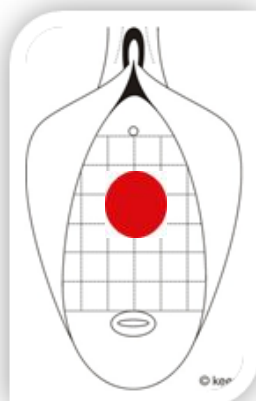
27/11-95 suprapubic mass, avw bulging into vagina, bladder overdistended (EUO/BW 17 cm, no/moderate elevation after draining > 1000 ml urine EUO/B 3 cm
increased bladder capacity (longitudinal diameter 17-3 = 14 cm, **atonic bladder**)

15.12 + 30.12 + 15.01.96 not leaking at all cath removed bladder drill

22.01.96 not leaking at all, no incontinence, normal miction
insp/ healed, good elevation, no stress incontinence

05.02 + 13.02 + 26.02 + 25.03.96 idem

13.05.96 not leaking at all, no incontinence, normal miction healed, no stress



4 cm

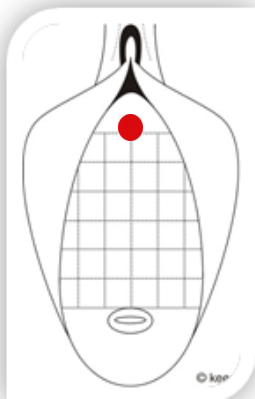
atonic bladder in spontaneous healing phase

swhd (kano city) female 16 yr 12/02-96

diagnosis: PII (1 alive), overflow incontinence due to an atonic bladder, **leaking urine for 25 days** (in the beginning continuously, for the last few days only at night and at daytime when coughing) which started 1 day following obstructed last labor for 1 day, at home a live male, married 4 yr ago pre(menarche 1 yr later), still living with husband, no menstruation, no h/o drop foot (but R grade 4) no RVF; borderline pubic arch
no avw trauma 165.0 cm

12/2-96 no suprapubic arch, avw bulging into vagina but not traumatized bladder overdistended (EUO/BW 16 cm) but not overfilled, no/moderate elevation after draining 500 ml urine, EUO/B 2.5 cm
increased bladder capacity (long diameter 16-2.5 = 13.5 cm, so atonic bladder definitely!, also from the other signs)

25.02 + 25.03.96 not leaking at all cath removed bladder drill
31.03.96 not leaking at all, no incontinence, normal miction
insp/ healed, good elevation, no stress incontinence
10.04 + 13.05.96 idem
08.07.96 not leaking at all, no incontinence, normal miction healed, no stress



matw (kano city)

female

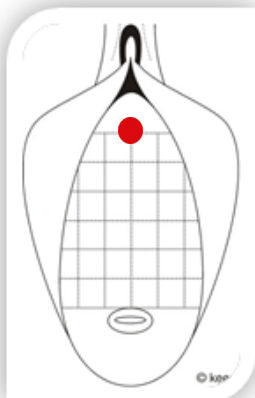
19 yr

04/03-96

diagnosis: PIII (0 alive), stress incontinence grade II, **leaking urine for 28 day** that started immediately following obstructed last labor for 2 days, in hospital SB male, married 6 yr ago post(menarche 1 mth earlier), not living with husband, no menstruation, drop foot R (grade 4), no RVF; normal pubic arch 160.0 cm

04.03.96 foley ch 18; free urine flow, EUO/BW 10 cm, no elevation, EUO/B 2.5 cm normal bladder capacity (longitudinal diameter 10-2.5 = 7.5 cm)

17.03 + 31.03.96 not leaking at all cath removed bladder drill
13/05-96 leaking whilst sitting, no incontinence, normal miction
insp/ healed, poor elevation, no stress incontinence



smhs (kano city)

female 28 yr

04/03-96

diagnosis: PX (1 alive), ± 2.5x1 cm necrotic vesicovaginal **IIAa** fistula, **leaking urine for 9 days** which started 3 days following obstructed last labor for 1 day, in hospital an SB male, married 15 yr ago pre(menarche 2 mth later), still living with husband, drop foot R (grade 4), no menstruation, no RVF; normal pubic arch
EUO/F 5 cm, F/C 3 cm 147.0 cm

04.03.96 FOLEY Ch 18; free flow of urine, EUO/BW 11 cm, good elevation and EUO/B 4 cm **it looks like it will heal spontaneously!**
normal bladder capacity (longitudinal diameter 11-4 = 7 cm)

17.03 + 30.03 + 09.04.96 not leaking at all cath removed bladder drill
15.04.96 not leaking at all, no incontinence, normal miction

insp/ healed, good elevation, no stress incontinence

06.05 + 20.05 + 30.06.96 idem

09.09.96 not leaking at all, no incontinence, normal miction healed, no stress

second obstetric fistula completely ok until PXI (2 alive) live male by cs

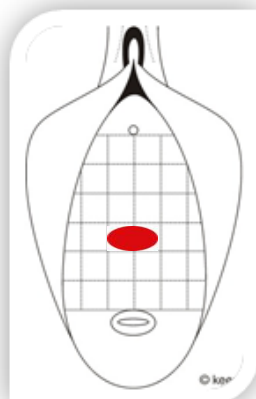
29/10-01 operation: UVVF-repair minimum surgery vvf 2376

24/03-02 leaking & miction insp/ healed, good elevation, stress +

09.06.05 operation: dilatation uv-stricture + uvvf-repair vvf 3374

11.07.07 operation: paraurethra_euo pcf fixation vvf 3920

10.02.08 leaking



2.5x1 cm

KANO
age at menarche: 13 yr

cath 405

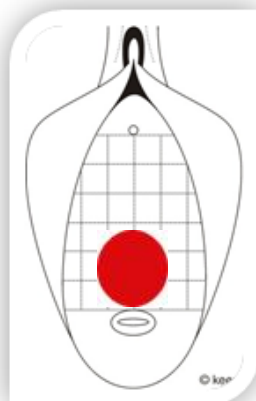
aus (kano city) female 14 yr 24/03-96

diagnosis: PI, \pm 3 cm 0 necrotic avw trauma **IIAa** (not yet fistula?), **leaking of urine for 11 days** that started immediately following obstructed labor of 2 days, in hospital SB male, married 2 yr ago pre(menarche 7 mth later), not living at her husband, no menstruation, drop foot R (grade 0), also pvw trauma but no RVF; narrow pubic arch
EUO/F 4 cm, F/C 0 cm 150.0 cm

24/03-96 FOLEY Ch 18; free urine flow, EUO/BW 11 cm, moderate elevation, EUO/B 3 cm will it heal spontaneously?
normal bladder capacity (longitudinal diameter 11-3 = 8 cm)

20.05.96 cath out x 14/7 not leaking at all, no incontinence, normal miction
Insp/ healed, good elevation, no stress incontinence

30/06-96 not leaking at all, no incontinence, normal miction
insp/ healed, good elevation, no stress incontinence



3 cm

KANO

cath 406

mkmb (kano)

female

15 yr

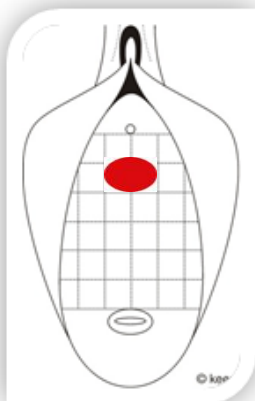
31/03-96

diagnosis: PI, ± 1.5x1 cm necrotic urethrovesicovaginal **IIBa** fistula, **leaking urine for 24 days** which started 6 days following obstructed labor for 1 day, in hospital SB female, married 2 yr ago pre(menarche 3 mth later), not living at her husband, no menstruation, drop foot R (grade 3-4) and L (grade 3-4), no RVF; narrow pubic arch
 EUO/F 1 cm, F/C 4 cm 156.0 cm

31.03.96 FOLEY Ch 18; free urine flow, EUO/BW 11 cm, moderate elevation, EUO/B 2 cm will it heal spontaneously?
 normal bladder capacity (longitudinal diameter 11-2 = 9 cm)

31/05-96 not leaking at all, no incontinence, normal miction

03/06-96 leaking & normal miction 1.5x1 cmfistula **??early sex??**
04/06-96 operation: UVVF-repair **vvf 1296**
 23.06 + 30.06.96 not leaking at all cath removed bladder drill
 08.07.96 not leaking at all, no incontinence, normal miction
 insp/ healed, good elevation, no stress incontinence
 22.07 + 26.08 + 15.10.96 idem
 11.11.96 not leaking at all, no incontinence, normal miction healed, no stress



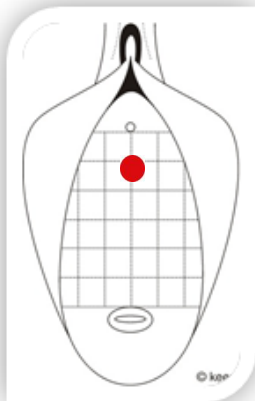
1.5x1 cm

rli (kaduna) female 14 yr 31/03-96

diagnosis: PI, almost healed \pm 0.5 cm 0 urethrovesicovaginal fistula midline, **leaking urine for 60 days** which started 3 days following obstructed labor for 2 days, at home SB male, married 2 yr ago pre(menarche 6 mth later), not living with husband, no menstruation, no h/o drop foot (but R grade 4 and L grade 4), no RVF; narrow pubic arch type **IIAa**
EUO/F 1.5 cm, F/C 5 cm 154.5 cm

31.03.96 FOLEY Ch 18; free urine flow, EUO/BW 10 cm, moderate elevation, EUO/B 2.5 cm **spontaneous healing!**
normal bladder capacity (longitudinal diameter 10-2.5 = 7.5 cm)

20.05.96 not leaking at all insp_gv/ fistula for op
21.05.96 not leaking at all, no incontinence, normal miction
insp/ healed, good elevation, no stress incontinence
10.06 + 15.07.96 idem
16.09.96 not leaking at all, no incontinence, normal miction healed, no stress



0.5 cm

hssk (kano city)

female

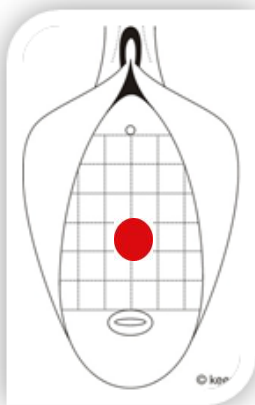
14 yr

31/03-96

diagnosis: PI, \pm 0.3 cm 0 urethrovesicovaginal fistula within \pm 2 cm 0 avw trauma
IIAa with scarring +, **leaking urine for 6 days which started 25 days**
 following obstructed labor for 2 days, in hospital a SB female, married 1 yr
 ago post(menarche 1 mth earlier), still at husband, no menstruation, drop
 foot R (grade 3) and L (grade 3) no RVF; narrow pubic arch
 EUO/F 4 cm, F/C 2 cm 153.0 cm

31/3-96 FOLEY Ch 18; free urine flow, EUO/BW 11 cm, moderate elevation,
 EUO/B 3 cm will it heal spontaneously?
 normal bladder capacity (longitudinal diameter 11-3 = 8 cm)

20.05.96 not leaking at all insp_gv/ still fistula for op
21/05-96 "operation": 140 ml gv: no leakage vvf 1278
so overnight fistula closed spontaneously
 01.07.96 not leaking at all, no incontinence, normal miction
 insp/ healed, good elevation, no stress incontinence
 26.08.96 idem
 24.12.96 not leaking at all, no incontinence, normal miction healed, no stress



2 cm

hygg (kano)

female

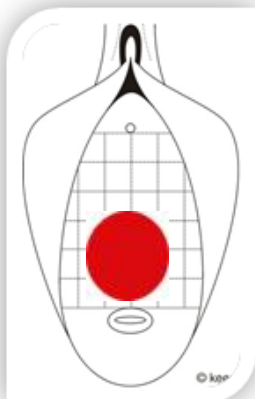
14 yr

06/05-96

diagnosis: PI, **necrotic** ± 4 cm 0 urethrovesicovaginal fistula **IIAa** with seeping thru, **leaking urine for 15 days** that started 1 day following an obstructed labor for 2 days, in hospital SB male, married 1 yr ago pre(menarche 1 mth later), still living at husband, no menstruation, drop foot L (grade 2) no RVF; narrow pubic arch; **necrosis does not seem to be too deep**
EUO/F 4 cm, F/C 0 cm 147.0 cm

06.05.96 FOLEY Ch 18; free urine flow, EUO/BW 12 cm, good elevation and EUO/B 4 cm will it heal spontaneously?
normal bladder capacity (longitudinal diameter 12-4 = 8 cm)

19.05 + 09.06.96 not leaking at all cath removed bladder drill
23.06.96 not leaking at all, no incontinence, normal miction
insp/ healed, good elevation, no stress incontinence
28.07.96 idem
21.10.96 not leaking at all, no incontinence, normal miction healed, no stress



4 cm

KANO

cath 410

jag (kano)

female

15 yr

06/05-96

diagnosis: PI, necrotic \pm 2 cm 0 urethrovesicovaginal **IIAa** fistula L, **leaking urine for 2 days** which started immediately following obstructed labor of 3 days, in hospital SB male, married 2 yr ago pre(menarche 2 mth later), still living with husband, no menstruation, drop foot R (grade 4) and L (grade 4), no RVF; borderline pubic arch; **necrosis does not seem to be too deep**
EUO/F 1.5 cm, F/C 6 cm 152.0 cm

06.05.96 foley ch 18; free urine flow, euo/bw 11 cm, good elevation, euo/b 2 cm
will it heal spontaneously?
normal bladder capacity (longitudinal diameter 11-2 = 9 cm)

02/06-96 0.5 cm fistula

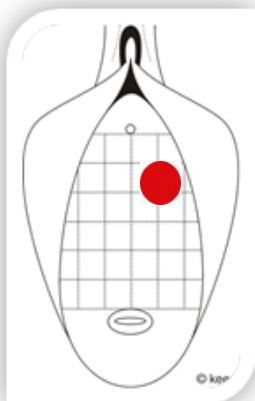
04/06-96 operation: UVVF-repair vvf 1297

23.06 + 30.06.96 not leaking at all cath removed bladder drill

06.07 + 22.07 + 29.08 not leaking at all, no incontinence, miction healed, stress +

15.10.96 not leaking at all, no incontinence, normal miction
insp/ healed, good elevation, no stress incontinence

11.11.96 not leaking at all, no incontinence, normal miction healed, no stress



2 cm

Ismb (kano) female 15 yr 13/05-96

diagnosis: PI, healing \pm 1 cm 0 urethrovesicovaginal fistula **IIAa** midline, **leaking urine for 28 days** which started immediately following obstructed labor for 1 day, in hospital SB female, married 1 yr ago post(menarche 7 mth earlier), not living with husband, no menstruation, no (h/o) drop foot, no RVF; narrow pubic arch
EUO/F 2 cm, F/C 4 cm 151.0 cm

13/05-96 FOLEY Ch 18; free urine flow, EUO/BW 11 cm, good elevation and EUO/B 3 cm it will heal spontaneously
normal bladder capacity (longitudinal diameter 11-3 = 8 cm)

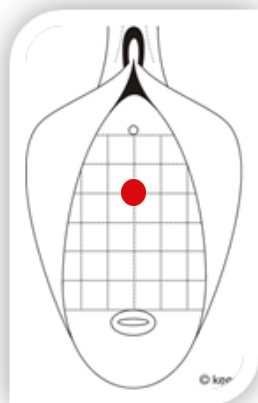
19.05 + 09.06.96 not leaking at all cath removed bladder drill

23.06.96 not leaking at all, no incontinence, normal miction
insp/ healed, good elevation, no stress incontinence

28.07 + 08.10.96 idem

05.11.96 not leaking at all, no incontinence, normal miction healed, no stress

14/07-97 **amenorrhea** for 3 mth not leaking at all **instructions**



1 cm

smda (kano)

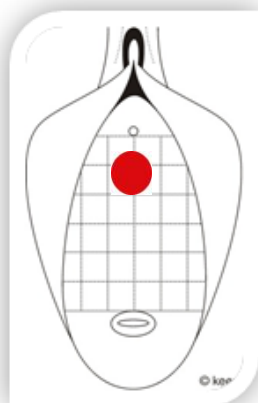
female 16 yr

20/05-96

diagnosis: PI, \pm 2 cm 0 urethrovesicovaginal fistula **IIAb** midline with circumferential defect, **leaking urine for 33 days** that started 8 days following obstructed labor for 1 day, in hospital live female who died same day, married 2 yr ago post(menarche 1 yr earlier) not living with husband, no menstruation, drop foot R (grade 4) no RVF; borderline pubic arch, when seen at 7-day duration on 24/4-96 necrotic fistula and catheter was inserted
 EUO/F 1 cm, F/C 6 cm, AU/AB 0.5 cm 157.0 cm

20/5-96 incision, dissection, transverse bladder/"urethra" closure with anterior adaptation with inverting chromic catgut, FOLEY Ch 18, transverse avw closure by everting chromic catgut/5x supramid, vagina pack; free urine flow, EUO/BW 12 cm, moderate elevation, EUO/B 2 cm anesthetic normal bladder capacity (longitudinal diameter 12-2 = 10 cm)

- 02.06 + 16.06.96 not leaking at all cath removed bladder drill
- 24.06.96 not leaking, incontinence \pm , normal miction healed, stress +
- 08.07 + 28.07.96 idem
- 30.09.96 not leaking at all, no incontinence, normal miction
insp/ healed, moderate elevation, no stress incontinence
- 03.12.96 not leaking at all, no incontinence, normal miction healed, no stress



2 cm

ribj (kano city) female 27 yr 09/04-96

diagnosis: PVI (1 alive), necrotic ± 3 cm 0 vesicovaginal fistula **IIAa, leaking urine for 7 days** which started 6 days following obstructed last labor for 3 days, in hospital SB female, married 16 yr ago post (menarche 2 yr later), still living at husband, no menstruation drop foot R (grade 4) and L (grade 4) and no RVF; normal pubic arch, **necrosis does not seem to be too deep type IIAa see vvf 1293**
EUO/F 6 cm, F/C 0 cm 150.0 cm

09.04.96 FOLEY Ch 18; free urine flow, EUO/BW 12 cm, moderate elevation, EUO/B 3 cm will it heal spontaneously?
normal bladder capacity (longitudinal diameter 12-3 = 9 cm)

20/5-96 not leaking at all; gv: no leakage; insp/ avw not yet completely healed catheter removed

02/06-96 leaking & normal miction insp/ minute fistula **??early sex??**

03/06-96 operation: VVF-repair vvf 1293

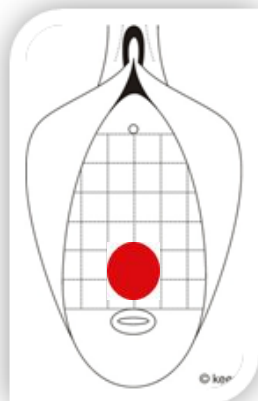
17.06 + 30.06.96 not leaking at all cath removed bladder drill

08.07.96 not leaking at all, no incontinence, normal miction healed, stress ±

22.07.96 not leaking at all, no incontinence, normal miction
insp/ healed, good elevation, no stress incontinence

09.09 + 05.11.96 idem

03.12.96 not leaking at all, no incontinence, normal miction healed, no stress



3 cm

zhg (kano)

female

14 yr

24/04-96

diagnosis: PI, ± 1 cm 0 avw trauma **IIAa** with total urine incontinence, **leaking urine for 19 days** that started immediately following obstructed labor for 1 day, in hospital SB male, married 1 yr ago pre(menarche 1 mth later), not living with husband, no menstruation, no (h/o) drop foot, no RVF; narrow pubic arch

EUO/AVWT 3 cm, AVWT/C 5 cm

145.0 cm

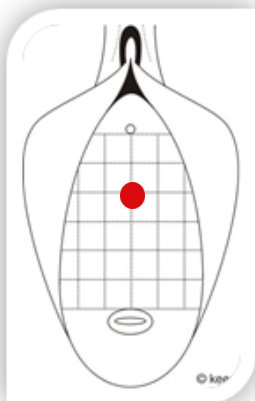
24/4-96 FOLEY Ch 18; free urine flow, EUO/BW 12 cm, moderate elevation, EUO/B 3.5 cm
normal bladder capacity (longitudinal diameter 12-3.5 = 8.5 cm)

20/05-96 not leaking at all; insp_gv: no leakage, completely healed
catheter removed

02.06.96 not leaking at all, no incontinence, normal miction
insp/ healed, good elevation, no stress incontinence

30.06 + 26.08 + 29.10.96 idem

24.02.97 not leaking at all, no incontinence, normal miction healed, no stress



1 cm

valve mechanism keeps pat dry despite uvvf!!!

ulkh (kano city) female 16 yr 09/04-96

diagnosis: PI, necrotic ± 4 cm 0 urethrovesicovaginal fistula L, **leaking urine for 16 days** which started 2 days following obstructed labor for 2 days, in hospital SB male, married 3 yr ago pre(menarche 2 mth later), still living with husband, no menstruation, drop foot R (grade 2) and L (grade 2), no RVF; pubic arch normal but small AP diameter
EUO/F 4 cm, F/C 0 cm 152.0 cm

09.04.96 FOLEY Ch 18; free urine flow, EUO/BW 12 cm, good elevation and EUO/B 3 cm
normal bladder capacity (longitudinal diameter 12-3 = 9 cm)

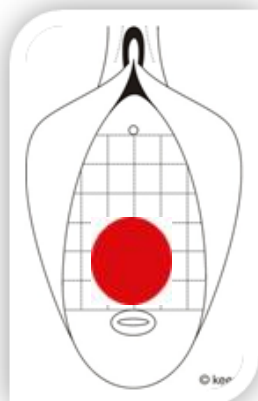
20/5-96 not leaking at all; insp/ still 3x1 cm deep avw trauma; gv test shows 0.5 cm urethrovesicovaginal fistula at distal tip
catheter removed; prepare for operation

21/5-96 not leaking at all, no incontinence, normal miction
insp/ **completely dry, still fistula with valve mechanism**

10.06.96 not leaking at all no fistula but deep avw trauma, no stress

01.07.96 not leaking at all avw healing, no stress

26/09-96 katsina not leaking at all, no incontinence, normal miction
insp/ **completely** healed, good elevation, no stress incontinence
pat lives now in katsina with parents



4 cm

htdb (kano) female 19 yr 26/05-96

diagnosis: PIII (1 alive), necrotic ± 1 cm 0 vesicovaginal fistula midline just in front of cervix, **leaking urine for 4 days** which started 7 days following obstructed labor for 3 days, at home SB male, married 8 yr ago pre (menarche 2 yr later), still living at her husband, no menstruation, drop foot R (grade 4) and L (grade 4) no RVF; normal pubic arch
EUO/F 7 cm, F/C 0 cm 149.0 cm

26/5-96 FOLEY Ch 18; free urine flow, EUO/BW 10 cm, moderate elevation, EUO/B 3 cm will it heal spontaneously?
normal bladder capacity (longitudinal diameter 10-3 = 7 cm)

03.06.96 leaking; /fistula

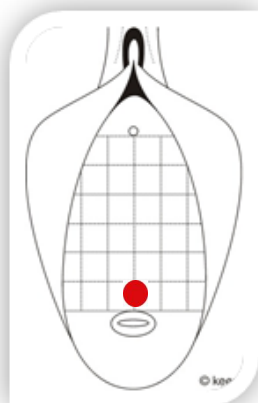
04/06-96 primary suturing anesthetic
incision, dissection, transverse bladder closure with inverting chromic catgut, FOLEY Ch 18, transverse avw closure by everting chromic catgut/3x supramid, vagina pack; free urine flow, EUO/ BW 10 cm, moderate levation, EUO/B 3 cm

23.06 + 30.06.96 not leaking at all cath removed bladder drill

08.07.96 not leaking at all, no incontinence, normal miction
insp/ healed, good elevation, no stress incontinence

22.07 + 19.08 + 21.10.96 idem

24.11.96 not leaking at all, no incontinence, normal miction healed, no stress



1 cm

KANO

cath 417

mjs (kano city)

female

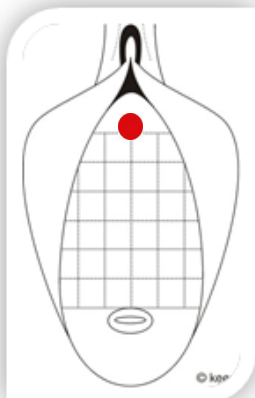
14 yr

27/05-96

diagnosis: **PI, leaking urine (with spontaneous miction) for 31 days** which started 15 days following obstructed labor for 2 days, in hospital live female, married 1 yr ago pre(menarche 2 mth later), not living with husband, no menstruation, no h/o drop foot but R (grade 4), no RVF; normal pubic arch 164.0 cm

27/5-96 FOLEY Ch 18; free urine flow, EUO/BW 12 cm, moderate elevation, EUO/B 3 cm, no stress incontence
normal bladder capacity (longitudinal diameter 12-3 = 9 cm)

09.06 + 25.06.96 not leaking at all cath removed bladder drill
01.07.96 not leaking at all, no incontence, normal miction
insp/ healed, moderate elevation, no stress incontence
22.07.96 not leaking at all, no incontence, normal miction healed, no stress



hydk (kano city)

female

14 yr

02/06-96

diagnosis: PI, necrotic \pm 1 cm 0 urethrovesicovaginal fistula **IIAa** at midline, **leaking urine for 10 days** which started immediately following obstructed labor for 2 days, in hospital SB male, married 1 yr ago post(menarche 3 mth earlier), still living with husband, no menstruation, no (h/o) drop foot, no RVF; narrow pubic arch and open episiotomy L
 EUO/F 4 cm, F/C 3 cm 153.0 cm

02.06.96 FOLEY Ch 18; free urine flow, EUO/BW 13 cm, moderate/good elevation, EUO/B 4 cm **will it heal spontaneously?**
 normal bladder capacity (longitudinal diameter 13-4 = 9 cm)

09/06-96 1 cm fistula

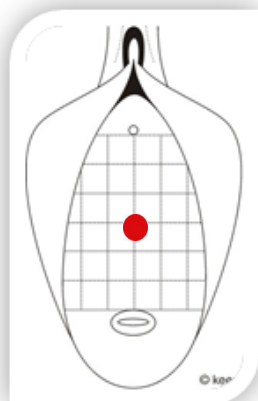
10/06-96 operation: UVVF-repair **vvf 1300**

24.06 + 07.07.96 not leaking at all cath removed bladder drill

15.07.96 not leaking at all, no incontinence, normal miction
 insp/ healed, good elevation, no stress incontinence

30.07 + 02.09 + 30.09.96 idem

24.11.96 not leaking at all, no incontinence, normal miction healed, no stress



1 cm

hak (kano city)

female

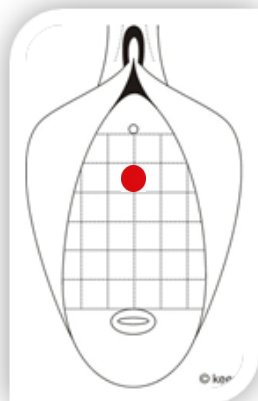
15 yr

17/06-96

diagnosis: PI, \pm 0.5 cm 0 urethrovesicovaginal fistula **IIAa** midline, **leaking of urine for 7 days** that started 8 days following obstructed labor for 1 day, in hospital SB male, married 1 yr ago post(menarche 6 mth earlier), not living with husband, no menstruation, drop foot R (grade 4) and L (grade 4), no RVF; normal pubic arch
 EUO/F 2 cm, F/C 5 cm 157.0 cm

17/6-96 incision, dissection, transverse bladder/urethra closure by inverting chromic catgut, FOLEY Ch 18, transverse avw closure by 3x supramid, pack; free urine flow, EUO/BW 11 cm, good elevation, EUO/B 2 cm normal bladder capacity (longitudinal diameter 11-2 = 9 cm) anesthetic

01.07 + 14.07 not leaking at all cath removed bladder drill
 22.07.96 not leaking at all, no incontinence, normal miction
 insp/ healed, good elevation, no stress incontinence
 09.08.96 idem
 16.09.96 not leaking at all, no incontinence, normal miction healed, no stress



0.5 cm

KANO
age at menarche: 13 yr

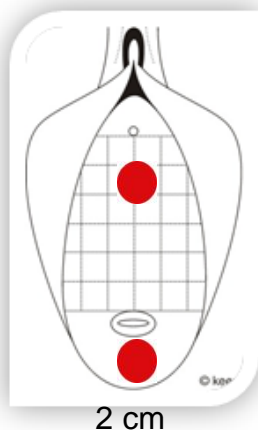
cath 420
RVF

lytw (kano city) female 14 yr 23/06-96

diagnosis: PI, necrotic \pm 2 cm 0 urethrovesicovaginal fistula at midline type **IIAa**, **leaking urine for 9 days** that started immediately following obstructed labor for 2 days, at home SB male, married 1 yr ago pre(menarche 2 mth later), not living with husband, no menstruation, no h/o drop foot (but both grade 4); narrow pubic arch, necrosis/slough lateral vagina walls, stool incontinence due to deep pvw necrosis but no RVF; **stress incontinence ++**
EUO/F 2 cm, F/C 6 cm 158.0 cm

23/6-96 FOLEY Ch 18; free urine flow, EUO/BW 12 cm, moderate elevation, EUO/B 2 cm **will it heal spontaneously?**
normal bladder capacity (longitudinal diameter 12-2 = 10 cm)
documented 25/6 + 7/7 + 14/7 + 21/7 + 9/9

25.06 + 14.07 + 28.07.96 not leaking cath removed bladder drill
12.08.96 not leaking at all, no incontinence, normal miction
insp/ healed, good elevation, no stress incontinence
09.09.96 idem
11.11.96 not leaking at all, no incontinence, normal miction healed, no stress



KANO

cath 421

smag (kano)

female

14 yr

26/05-96

diagnosis: PI, leaking urine for 3 mth which started immediately following obstructed labor for 3 days, in hospital SB male, married 1 yr ago pre(menarche 3 mth later), not living with husband, no menstruation, postpoliomyelitis syndrome L > R, drop foot R (grade 3), no stool per vaginam; narrow pubic arch, **vagina only 1 cm deep**, not leaking at all since FOLEY Ch 18 in situ for 18 days at **leaking urine for 72 days**
"vaginal" examination not possible 148.0 cm

26/05-96 leave catheter in for 4-6 weeks, then gv examination

10/06-96 not leaking at all

25/06-96 not leaking at all **documented 25/6!**

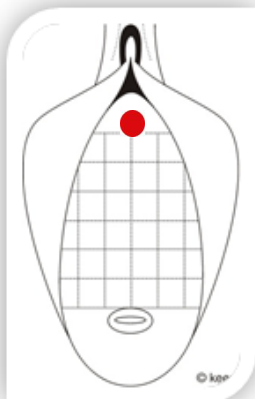
01/07-96 insp_gv/ no leakage catheter removed **bladder drill!**

16.07.96 not leaking at all, no incontinence, normal miction

insp/ healed, no stress incontinence

16.09 + 11.11.96 idem

20.01.97 not leaking at all, no incontinence, normal miction healed, no stress



KANO

cath 422

nhk (kano)

female

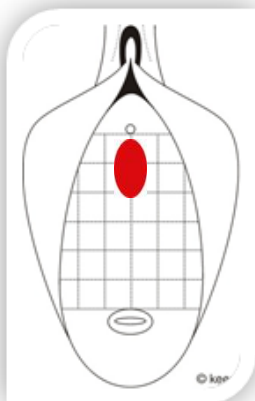
13 yr

24/06-96

diagnosis: P0, ± 4x1 cm deep avw trauma over urethra/bladder neck (without fistula?), **leaking urine for 8 days** which started immediately following yankan gishiri by wanzami b.c.o. "ba hanya" (grandmother said so!) to remove beli, no native medicine, married 2x for first time 3 mth ago pre(menarche 1 mth later), then second time with this "problem", not living with husband, **stress +++**; normal pubic arch; pat herself: **no** problem with sex!
 EUO/AVWT 0.5 cm, AVWT/C 3 cm 159.0 cm

24/6-96 FOLEY Ch 18; free urine flow, EUO/BW 11 cm, good elevation and EUO/B 3.5 cm **will it heal or become fistula??**
 normal bladder capacity (longitudinal diameter 11-3.5 = 7.5 cm)
documented 25/6!

14/07-96 leaking balloon inside fistula **we should have closed avw!!**
15/07-96 operation: urethra reconstruction VVF 1348
 06.08 + 12.08.96 not leaking at all cath removed bladder drill
 20.08.96 not leaking at all, no incontinence, normal miction
 insp/ healed, good elevation, no stress incontinence
 02.09 + 21.10 + 24.12.96 idem
 06.01.97 not leaking at all, no incontinence, normal miction healed, no stress



2.5x1 cm

KANO

cath 423

aar (kano)

female

34 yr

07/07-96

diagnosis: PXI (4 alive), \pm 2 cm 0 "healing" UVVF at R, **leaking urine for 10 days** which started 20 days following obstructed last labor for 2 days, in hospital SB male, married 22 yr ago pre(menarche 1 yr later), not living at husband, no menstruation, drop foot R (grade 3) and L (grade 4), no RVF; normal pubic arch, catheter in situ for 5 days type **IIAa**
EUO/F 4 cm, F/C 2 cm 152.0 cm

07.07.96 foley ch 18; free urine flow, euo/bw 12 cm, good elevation, euo/f 4 cm
normal bladder capacity (longitudinal diameter 12-4 = 8 cm)
probably it will heal spontaneously **documented 7/7-96**

21/07-96 not leaking at all 0.3 cm fistula

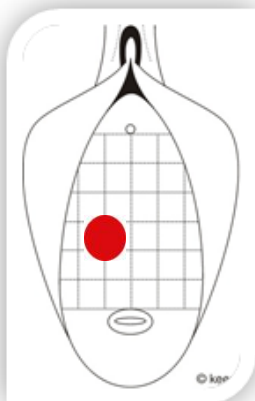
22/07-96 operation: UVVF-repair vvf 1352

06.08 + 19.08.96 not leaking at all cath removed bladder drill

14.10.96 not leaking, incontinence $\pm\pm$, normal miction
insp/ healed, good elevation, stress incontinence +

05.11 + 17.02.96 idem pat happy

01.06.97 not leaking at all, no incontinence, normal miction healed, no stress



2 cm

KANO
classic atonic bladder

cath 424

zhk (kano city) female 15 yr 07/07-96

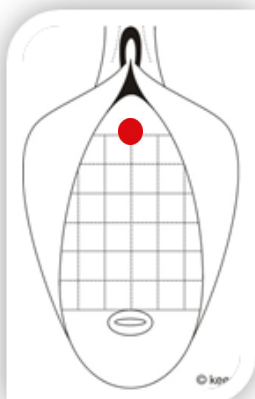
diagnosis: PI, overflow incontinence due to atonic bladder (**no** spontaneous miction), **leaking urine for 15 days** that started 4 days following obstructed labor for 1 day, in hospital live male, married 1 yr ago post(menarche 6 mth earlier), not living with husband, no menstruation, no (h/o) drop foot, no RVF; a borderline pubic arch 150.0 cm

7/7-96 suprapubic mass, avw bulging into vagina, bladder overdistended (EUO/BW 21 cm), moderate elevation after draining 1500 ml urine and EUO/B 2 cm, mild avw trauma

increased bladder capacity (longitudinal diameter 21-2 = 19 cm, **atonic bladder**)

suprapubic mass/uterine sound/urine documented 7/7-96!

21.07 + 19.08.96	not leaking at all	cath removed	bladder drill
26/08-96	urine retention/fever/headache/vomiting	?again atonic bladder?	ch 18
16.09 + 23.09.96	not leaking at all	cath removed	bladder drill
21.10.96	not leaking at all, no incontinence, normal miction		
	insp/ healed, good elevation, no stress incontinence		
11.11.96	idem		
20.01.97	not leaking at all, no incontinence, normal miction		healed, no stress



hmrl (kano city)

female

15 yr

07/07-96

diagnosis: PI, overflow incontinence due to atonic bladder, **leaking urine for 13 days** which started 5 days following obstructed labor for 2 days, in hospital a SB male, married 1 yr ago post(menarche 7 mth earlier), not living with husband, no menstruation, a drop foot L (grade 3), no RVF; narrow pubic arch 156.0 cm

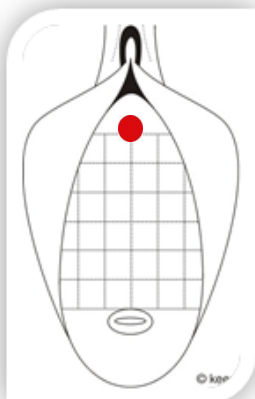
07.07.96 suprapubic mass, avw bulging into vagina, bladder overdistended (eu/bw 16 cm), good elevation after draining 1000 ml of urine, EUO/B 2 cm increased bladder capacity (longitudinal diameter 16-2 = 14 cm, **atonic bladder**)

21.07 + 19.08.96 not leaking at all cath removed bladder drill

02.09.96 not leaking at all, no incontinence, normal miction insp/ healed, moderate elevation, no stress incontinence

16.09 + 15.10 + 10.12.96 idem

20.01.97 not leaking at all, no incontinence, normal miction healed, no stress



rsykj (kano city)

female

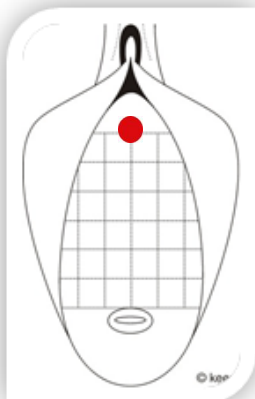
16 yr

07/07-96

diagnosis: PI, overflow incontinence due to atonic bladder, **leaking urine for 35 days** that started immediately following obstructed labor for 3 days, in hospital SB male, married 1 yr ago post(menarche 2 yr earlier), not living with husband, no menstruation, a drop foot R (grade 4) and L (grade 4), no RVF; narrow pubic arch, no avw trauma, catheter in situ for 4 days

7/7-96 FOLEY Ch 18; free flow of urine, EUO/BW 16 cm, **no** elevation and EUO/B 2 cm, avw hanging totally loose 163.0 cm
increased bladder capacity (longitudinal diameter 16-2 = 14 cm, **atonic bladder**)

15.07 + 13.08.96	not leaking at all	cath removed	bladder drill
26.08.96	not leaking, incontinence +, normal miction	healed,	no stress
24.09.96	not leaking at all, no incontinence, normal miction		
	insp/	healed, good elevation,	no stress incontinence
16.12.96	not leaking at all, no incontinence, normal miction	healed,	no stress



KANO

cath 427

asjkt (kano city)

female

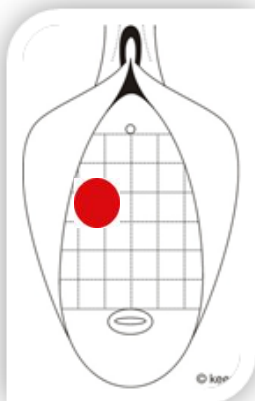
14 yr

21/07-96

diagnosis: PI, \pm 2.5 cm 0 **necrotic** urethrovesicovaginal fistula R, **leaking urine for 14 days** that started immediately following obstructed labor x 1 day, in hospital SB male, married 3 yr ago pre(menarche 2 yr later), not living with husband, no menstruation, drop foot R (grade 4) and L (grade 2), no RVF; normal pubic arch
EUO/F 4 cm, F/C 2 cm 162.0 cm

21/7-96 FOLEY Ch 18; free urine flow, EUO/BW 11 cm, moderate elevation, EUO/B 4 cm will it heal spontaneously?
normal bladder capacity (longitudinal diameter 11-4 0 7 cm)

06.08 + 19.08.96 not leaking at all cath removed bladder drill
02.09.96 not leaking at all, no incontinence, normal miction
insp/ healed, good elevation, no stress incontinence
09.09 + 11.11 + 24.11.96 idem
20.01.97 not leaking at all, no incontinence, normal miction healed, no stress



2.5 cm

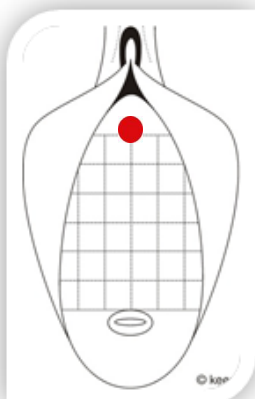
**atonic bladder in spontaneous healing phase
(resulting in intrinsic_stress incontinence 09.05.13)**

dst (kano) female 16 yr 21/07-96

diagnosis: PI, overflow incontinence due to **atonic bladder, leaking urine for 20 days** that started immediately following obstructed labor for 2 days, in hospital (1/7-96) SB male, married 3 yr ago pre(menarche 3 mth later), not living at husband, no menstruation, no (h/o) drop foot, no RVF; borderline pubic arch, spontaneous micturition?, demonstrable **stress incontinence** 150.0 cm

21/7-96 small suprapubic mass, avw "bulging" into vagina, bladder overdistended (EUO/BW 16 cm) but not overfilled??, moderate elevation after draining 500 ml urine, EUO/B 2 cm increased bladder capacity (longitudinal diameter 16-2 = 14 cm, **atonic bladder in spontaneous healing phase!!**)

13.08 + 26.08.96 not leaking at all cath removed bladder drill
16/09-96 not leaking at all, no incontinence, normal miction
insp/ healed, good elevation, no stress incontinence



KANO

cath 430

uihs (kano city)

female

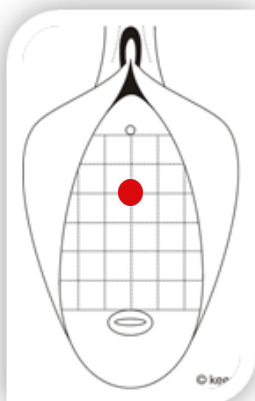
16 yr

08/09-96

diagnosis: PI, \pm 1 cm **deep** 0 avw trauma type **IIAa** midline UV-junction, **leaking urine for 10 days** only when standing/walking/coughing which started 2 days following an obstructed labor for 1 day, in hospital live male, married 16 mth ago post(menarche 2 yr earlier), not living with husband, no menstruation, drop foot R (grade 4), no RVF; a normal pubic arch; **objectively demonstrable stress incontinence**
EUO/AVWT 2.5 cm, AVWT/C 5 cm 151.0 cm

08.09.96 FOLEY 18; free urine flow, EUO/BW 12 cm, good elevation, EUO/B 3 cm **it will heal spontaneously!**
normal bladder capacity (longitudinal diameter 12-3 = 9 cm)
documented **8/9-96**

22.09 + 07.10.96 not leaking at all cath removed bladder drill
15.10.96 not leaking at all, no incontinence, normal miction
insp/ healed, good elevation, no stress incontinence
17.02.97 not leaking at all, no incontinence, normal miction healed, no stress



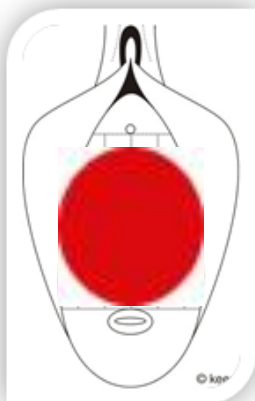
1 cm

ldbp (plateau) female 15 yr 08/09-96

diagnosis: PI, ± 6 cm 0 avw **necrosis, leaking urine urine for 8 days** which started 1 day following obstructed labor of 3 days, in hospital SB female, married 1 yr ago post(menarche 1 yr earlier), not at husband, no menstruation, drop foot R (grade 1) and L (grade 4) no RVF; narrow pubic arch, open median rupture
EUO/F 1 cm, F/C 0 cm 160.5 cm

8/9-96 FOLEY Ch 18; free urine flow, EUO/BW 11 cm, moderate elevation, EUO/B 3 cm
will it heal spontaneously?
normal bladder capacity (longitudinal diameter 11-3 = 8 cm)

22/09-96 leaking **fistula**
14/10-96 operation: UVVF-repair VVF 1389
29.10 + 10.11.96 not leaking at all cath removed bladder drill
18.11.96 not leaking at all, no incontinence, normal miction
insp/ healed, good elevation, no stress incontinence



6 cm

aatn (kano)

female

41 yr

15/09-96

diagnosis: PIX (6 alive), overflow incontinence due to an atonic bladder, **leaking urine for 5 days** which started immediately following an obstructed last labor for 3 days, in hospital SB male, married 30 yr ago pre(menarche 2 yr later), still living with husband, no menstruation, drop foot R (grade 2) and L (grade 2), normal pubic arch, avw trauma **IIAa** 154.0 cm

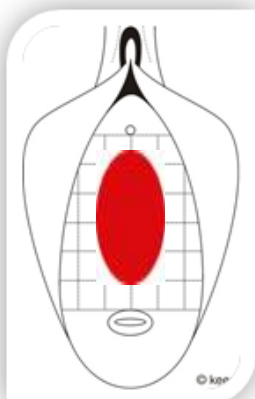
15/9-96 suprapubic mass, avw "bulging" into vagina vagina, bladder over distended (EUO/BW 18 cm), moderate elevation after draining of > 1,000 ml urine, EUO/B 3 cm
increased bladder capacity (longitudinal diameter 18-3 = 15 cm, **atonic bladder**)

30.09 + 13.10 avw healed + 28.10.96 not leaking cath removed bl drill

04.11.96 not leaking at all, no incontinence, normal miction
insp/ healed, good elevation, no stress incontinence

24.11.96 idem

24.02.97 not leaking at all, no incontinence,normal miction healed, no stress



avw trauma

KANO
age at menarche: 13 yr

cath 434
RVF

adkdk (kano city) female 16 yr 15/09-96

diagnosis: PI, \pm 4 cm 0 "necrotic" urethrovesicovaginal **IIAb "fistula"**, **leaking urine for 7 days** which started immediately following obstructed labor for 1 day, in hospital SB male, married 3 yr ago pre(menarche 3 mth later), still living with husband, no menstruation, drop foot R (grade 4) and L (grade 4), \pm 4 cm 0 necrotic pvw at proximal vagina; normal pubic arch, **objectively demonstrable stress incontinence ++**
EUO/"F" 4 cm, "F"/C 0 cm 148.0 cm

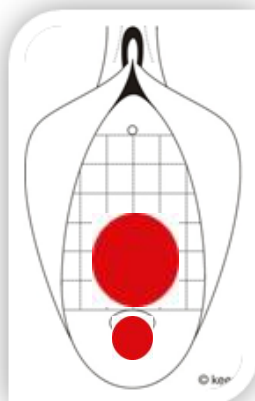
15/9-96 FOLEY Ch 18; free flow of urine, EUO/BW 12 cm, good elevation, EUO/B 3 cm
will it heal spontaneously?
normal bladder capacity (longitudinal diameter 12-3 = 9 cm)

22/09-96 leaking **fistula**

14/10-96 operation: ureters/circumf UVVF-repair VVF 1390

28.10 + 11.11.96 not leaking cath removed bladder drill

18.11 + 10.12 +17.02.97 not leaking, incontinence \pm , miction healed, stress +
08.04.97 not leaking at all, no incontinence, normal miction
insp/ healed, good elevation, no stress incontinence
06.05.97 not leaking at all, no incontinence, normal miction healed, no stress



4 cm

KANO
age at menarche: 13 yr

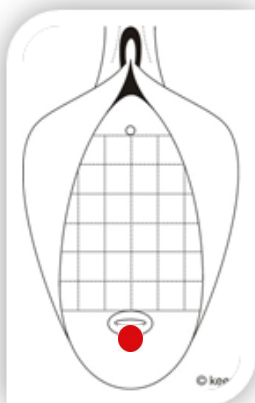
cath 436
RVF

amiss (kano city) female 27 yr 29/09-96

diagnosis: PVI (5 alive), small? CS-vesicocervicovaginal fistula, **leaking urine for 11 days** which started 3 days (upon catheter removal!) following CS after failed forceps b.c.o. obstructed last labor for 2 days, SB femal, married 15 yr ago pre(menarche 10 mth later), **still** in hospital, no menstruation, no h/o drop foot (but both grade 4), **± 2 cm 0 proximal pwv necrosis**; normal pubic arch, FOLEY Ch 18 in situ for 6 days; **copiuos purulent discharge from vault or cervix, further inspection not possible**
EUO/"F" 10 cm, "F"/"CV" 0 cm, I/F 10 cm, F/V 3 cm 153.5 cm

29/09-96 free urine flow thru catheter, EUO/BW 12 cm, moderate elevation and EUO/B 4 cm **will it heal spontaneously?**
normal bladder capacity (longitudinal diameter 12-4 = 8 cm)

06.10 + 03.11 + 10.11.96 not leaking at all gv: **no** leakage
24.11.96 cath out x 5/7 not leaking at all, no incontinence, normal mictiom
insp/ **both** healed, good elevation, no stress incontinence
10.12.96 idem "anterior cs lip" healed
18/03-97 not leaking at all, no incontinence, normal miction
insp/ **both** healed, good elevation, no stress incontinence



hnsz (kano city)

female

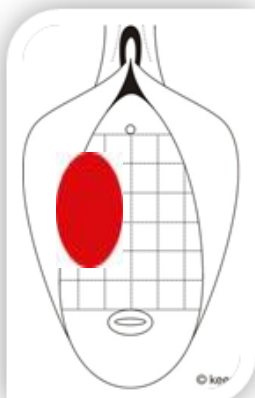
17 yr

14/10-96

diagnosis: PI, overflow incontinence due to atonic bladder, **leaking urine for 11 days** (and spontaneous miction) which started immediately following an obstructed labor for 6 days, at home an SB female, married 2 yr ago post(menarche 2 yr earlier), still living with husband, no menstruation, no RVF, a drop foot R (grade 4) and L (grade 4), no RVF; **extensive avw trauma with ± 5x3 cm necrosis (fistula??) over R bladder neck type IIAa_b**; normal pubic arch
 EUO/F 1.5 cm, F/C 2 cm 156.0 cm

14/10-96 suprapubic "mass", avw "bulging" into vagina, bladder overdistended (EUO/BW 22 cm, tip of uterine sound cephalad from umbilicus!!), good elevation after draining > 1,500 ml urine, EUO/B 3 cm **probably it will become fistula!**
 increased bladder capacity (longitudinal diameter **22-3 = 19 cm, atonic bladder!!**)

- 27.10 + 10.11.96 not leaking at all gv: **no** leakage
- 18.11.96 not leaking at all cath removed bladder drill
- 24.11.96 not leaking at all, no incontinence, normal miction
 insp/ healed, good elevation, no stress incontinence
- 10.12 + 10.02.97 idem
- 18.03.97 not leaking at all, no incontinence, normal miction healed, no stress



5x3 cm

KANO
history of yankan gishiri: yes/no

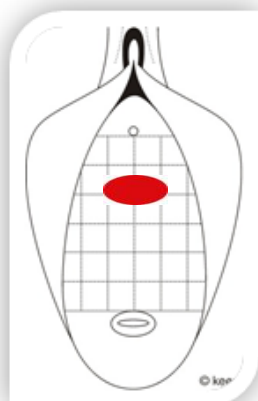
cath 439

srig (kano) female 22 yr 20/10-96

diagnosis: PIII (0 alive), \pm 2.5x1 cm fresh scar uv-junction fixed to symphysis **IIAa**, **leaking urine for 20 days** which started 2 days following obstructed last labor for 2 days, in hospital SB male, married 9 yr ago pre(menarche 5 mth later), not living at husband, no menstruation, drop foot R (grade 2) and L (grade 0), no RVF; normal pubic arch, **stress after spontaneous healing or still minute fistula**, no yankan gishiri; gv: **spilling from EUO**
EUO/S 2 cm, S/C 5 cm 143.0 cm

20/10-96 FOLEY Ch 18; free urine flow, EUO/BW 10 cm, moderate elevation (urethra fixed to symphysis), EUO/B 2 cm
normal bladder capacity (longitudinal diameter 10-2 = 8 cm)
ulcer L buttock (with abscess?) and R buttock, **documented!**

03.11 + 18.11.96 leaking insp_gv/ healed cath removed bladder drill
24.11.96 not leaking, incontinence +, normal miction healed, no stress
10.12 + 17.02.97 idem
15/04-97 not leaking at all, no incontinence, normal miction
insp/ healed, good elevation, no stress incontinence



2.5x1 cm

KANO

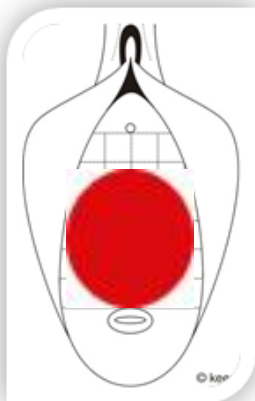
cath 441

hmtu (kano) female 24 yr 11/11-96

diagnosis: PII (0 alive), extensive \pm 6 cm "necrotic" avw trauma with already small fistula in the middle, **leaking of urine for 4 days** which started immediately following obstructed last labor for 1 day, in hospital an SB female, married 12 yr ago pre(menarche 6 mth later), still living at husband, no menstruation, drop foot R (grade 4), no RVF; narrow pubic arch, no yankan gishiri
EUO/F 2 cm, F/C 0 cm 159.0 cm

11/11-96 FOLEY Ch 18; free urine flow, EUO/BW 12 cm, moderate/no elevation, EUO/B 2 cm **will it heal spontaneously?**
normal bladder capacity (longitudinal diameter 12-2 = 10 cm)
at least the greater part of the necrotic trauma will heal!

24.11 + 02.12.96 fistula
03/12-96 operation (MMSH_Im): UVVF-repair



6 cm

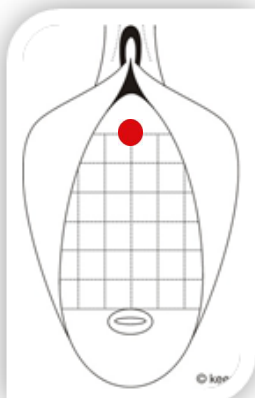
long-standing atonic bladder???
total intrinsic_stress incontinence as “healing phase”

zig (kano city) female 20 yr 17/11-96

diagnosis: PIV (2 alive), **overflow incontinence due to an atonic bladder?**, leaking urine for **3 yr** which started immediately following obstructed **third** labor for 1 day, at home live female, married 8 yr ago pre(menarche 7 mth later), not living with husband, normal menstruation, drop foot L (grade 4), no RVF; normal pubic arch, yankan gishiri by ungozoma for delivery I

17/11-96 **no** suprapubic mass, **indurated** avw **bulging** into vagina, EUO/BW 12 cm, **no** elevation after draining 300 ml **foul-smelling milky** urine, EUO/B 1 cm gv: **no** leakage! 147.0 cm
increased? bladder capacity (long diameter 12-1 = 11 cm)
nb strange rough bladder lining as felt by sound!

24.11 + 16.12 + 30.12.96 not leaking at all cath removed bladder drill
06.01.97 not leaking at all, no incontinence, normal miction
insp/ healed, good elevation, no stress incontinence
13.01.97 not leaking at all, no incontinence, normal miction healed, no stress



hsu (kano city)

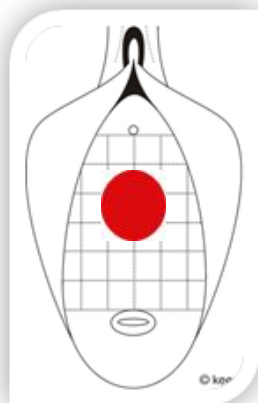
female

15 yr

17/11-96

diagnosis: PI, \pm 3 cm 0 deep necrotic avw **IIAa_b** trauma, **leaking urine for 7 days** that started immediately following cs bco. obstructed labor for 3 days, live female, married 2 yr ago pre(menarche 2 mth later), still on admission, no menstruation, drop foot R (grade 4) and L (grade 3), no RVF; narrow pubic arch, no yankan gishiri, **pus ++ from infected abdominal wound!**
EUO/F 2 cm, F/C 3 cm 168.0 cm

17/11-96 FOLEY Ch 18; free flow of urine, EUO/BW 12 cm, good elevation, EUO/B 2 cm **probably it will become fistula!**
normal bladder capacity (longitudinal diameter 12-2 = 10 cm)



3 cm

KANO

cath 444
rvf

bask (kano) female 15 yr 17/11-96

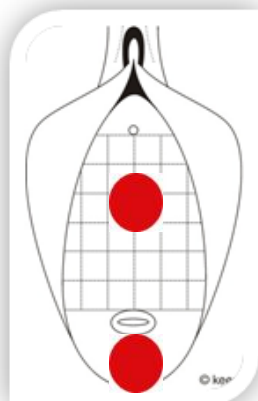
diagnosis: PI, \pm 3 cm 0 deep necrotic urethrovesicovaginal fistula type **IIAa_b**, **leaking urine for 6 days** which started immediately following an obstructed labor of 3 days, in hospital SB male, married 2 yr ago pre(menarche 1 mth later), not living with husband, no menstruation, drop foot R (grade 2) and L (grade 4), **stool incontinence due to "necrotic" pvw trauma but no RVF**; narrow pubic arch, no yankan gishiri
EUO/F 2 cm, F/C 4 cm 152.0 cm

17/11-96 FOLEY Ch 18; free flow of urine, EUO/BW 11 cm, good elevation, EUO/B 2 cm
probably it will become fistula!
normal bladder capacity (longitudinal diameter 11-2 = 9 cm)

20/01-97 leaking **fistula**

21/01-97 operation (MMSH_Im): UVVF-repair

06/05-97 not leaking at all, no incontinence, normal miction
insp/ healed, good elevation, no stress incontinence



3 cm

ramn (bauchi)

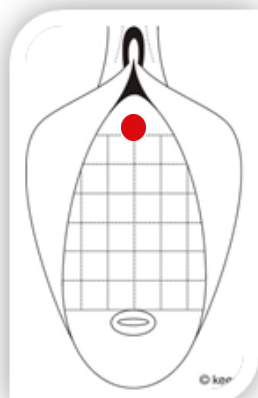
female

16 yr

18/11-96

diagnosis: PI, ureter fistula??, leaking urine for 1 yr which started immediately following CS b.c.o. obstructed labor for 2 days, SB female, married 3 yr ago pre(menarche 5 mth later), not living with husband, no menstruation, drop foot L (grade 4), no RVF; narrow pubic arch, **NB road traffic accident** 6 mth ago, no yankan gishiri 155.0 cm

18/11-96 FOLEY Ch 18; free urine flow, EUO/BW 12 cm, good elevation and EUO/B 4 cm
normal bladder capacity (longitudinal diameter 12-4 = 8 cm)
150 ml gv: no leakage but cloudy fluid in vaginae!



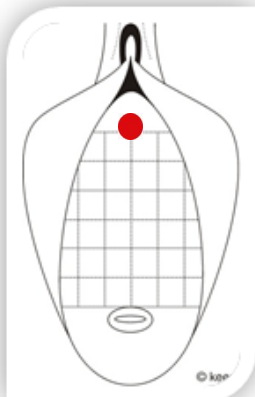
atonic bladder??? no: postrepair incontinence

hiu (kano) female 22 yr 18/11-96

diagnosis: PV (2 alive), overflow incontinence due to atonic bladder after successful **early closure d.d. 22/1-96 (MMSH_Id)??**, leaking urine for 11 mth which started immediately following an obstructed last labor for 3 days, at home an SB male, normal menstruation, drop foot R (grade 5 against 3) and L (grade 1), no RVF; narrow pubic arch, no yankan gishiri 144.0 cm

18/11-96 **no** suprapubic mass, avw bulging into vagina, bladder "overdistended" (EUO/BW 13 cm), no elevation after draining 400 ml urine, EUO/B 1.5 cm increased? bladder capacity (long diameter 13-1.5 = 11.5 cm)

- 02.12 + 24.12.97 not leaking at all cath removed bladder drill
- 06.01.97 not leaking at all, no incontinence, normal miction healed, stress +
- 20.01 + 17.02 + 04.03.97 idem **bladder drill**
- 09/06-97 not leaking at all, no incontinence, normal miction insp/ healed, moderate elevation, no stress incontinence



absm (katsina)

female

38 yr

30/12-96

diagnosis: PVI (3 alive), \pm 1 cm 0 necrotic vesicovaginal fistula I midline, **leaking of urine for 8 days** which started 9 days (upon catheter removal) following CS b.c.o. obstructed last labor for 2 days, SB female, married 25 yr ago pre(menarche 4 mth later), still living with husband, no menstruation, drop foot R (grade 4), no RVF, no h/o yankan gishiri; normal pubic arch
 EUO/F 8 cm, F/C 0 cm 150.0 cm

30/12-96 FOLEY Ch 18; free urine flow, EUO/BW 11 cm, moderate elevation, EUO/B 3 cm will it heal spontaneously?
 normal bladder capacity (longitudinal diameter 11-3 = 8 cm)

13.01 + 27.01.97 not leaking at all healing

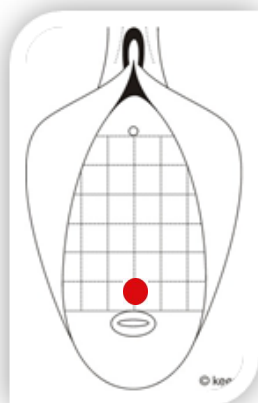
17.02.97 not leaking at all insp_gv/ healed cath removed bladder drill

24.02.97 not leaking at all, no incontinence, normal miction

insp/ healed, good elevation, no stress incontinence

10.03.97 idem

02.06.97 not leaking at all, no incontinence, normal miction healed, no stress



1 cm

KANO

cath 448

szkb (kano city)

female

14 yr

06/01-97

diagnosis: PI, ± 1 cm 0 necrotic urethrovesicovaginal fistula **IIAa** at R bladder neck, **leaking urine for 15 days** which started 10 days (upon catheter removal) following CS b.c.o. obstructed last labor for 3 days, SB male, married 1 yr ago pre(menarche 2 mth later), not living with husband, no menstruation, drop foot R (grade 4) and L (grade 4), no RVF, no h/o yankan gishiri; narrow pubic arch
EUO/F 2 cm, F/C 6 cm 151.0 cm

06.01.97 FOLEY Ch 18; free urine flow, EUO/BW 10 cm, good elevation and EUO/B 2.5 cm will it heal spontaneously?
normal bladder capacity (longitudinal diameter 10-2.5 = 7.5 cm)

20.01 + 03.02 not leaking at all

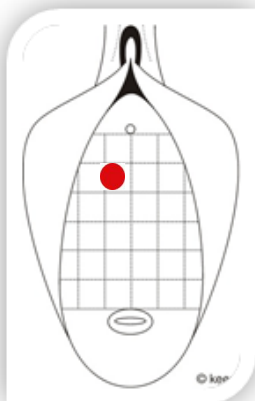
17.02.97 not leaking insp_gv/ healed cath removed bladder drill

24.02.97 not leaking at all, no incontinence, normal miction

insp/ healed, good elevation, no stress incontinence

10.03 + 06.05.97 idem

01.06.97 not leaking at all, no incontinence, normal miction healed, no stress



1 cm

agg (kano city) female 27 yr 20/01-97

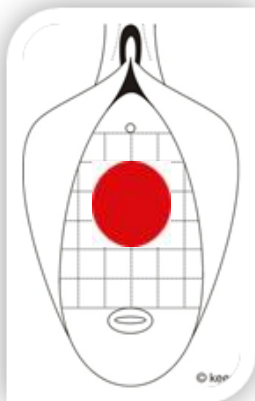
diagnosis: PVII (0 alive), overflow incontinence due to atonic bladder and \pm 6 cm 0 necrotic avw trauma **IIAa, leaking urine for 17 days** which started immediately following obstructed last labor for 2 days, in hospital SB male, married 15 yr ago pre(menarche 7 mth later), not living with her husband, no menstruation, drop foot R (grade 4), no RVF, no h/o yankan gishiri; normal pubic arch
EUO/AVWN 2 cm, AVWN/C 4 cm 145.0 cm

20/1-97 suprapubic mass, avw bulging into vagina, bladder overdistended (EUO/BW 18 cm), moderate elevation after draining > 1,500 ml of urine, EUO/B 2 cm will it heal spontaneously?
increased bladder capacity (longitudinal diameter 18-2 = 16 cm, **atonic bladder**) FOLEY Ch 18; free urine flow

09/02-97 not leaking at all avw healing

29.02.97 cath out x 4/7 not leaking at all, no incontinence, normal miction insp/ healed, good elevation, no stress incontinence

24/03-97 not leaking at all, no incontinence, normal miction insp/ healed, good elevation, no stress incontinence



6 cm

bsrl (kano city)

female

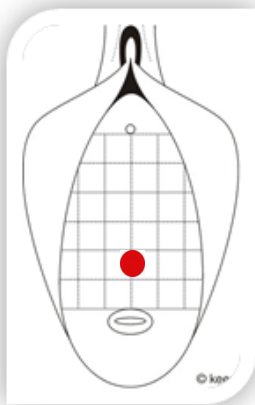
18 yr

23/01-97

diagnosis: PI, \pm 2 cm 0 necrotic urethrovesicovaginal fistula at midline, **leaking urine for 14 days** which started immediately following obstructed labor for 3 days, in hospital SB male, married 5 yr ago post(menarche 2 mth earlier), not living with husband, no menstruation, drop foot R (grade 3) and L (grade 4), no RVF, no h/o yankan gishiri; normal pubic arch, necrotic pvw trauma with flatus incontinence
 EUO/F 2 cm, F/C 6 cm 155.0 cm

23/01-97 FOLEY Ch 18; free urine flow, EUO/BW 11 cm, good elevation and EUO/B 2.5 cm will it heal spontaneously?
 normal bladder capacity (longitudinal diameter 11-2.5 = 8.5 cm)

09.02 healing + 23.02.97 not leaking healed cath removed bladder drill
 04.03.97 not leaking at all, no incontinence, normal miction
 insp/ healed, good elevation, no stress incontinence
 08.04 + 10.06.97 idem
 04.08.97 not leaking at all, no incontinence, normal miction healed, no stress



2 cm

mgs (kano city)

female

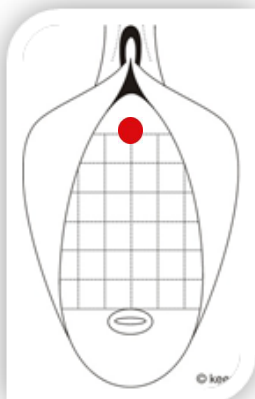
18 yr

27/01-97

diagnosis: PII (1 alive), overflow incontinence due to an atonic bladder, **leaking urine for 7 days (also miction at passing stools)** which started 2 days following an obstructed last labor for 1 day, in hospital a SB female, married 4 yr ago post(menarche 7 mth earlier), still living with husband, no menstruation, drop foot L (grade 2), no RVF, no h/o yankan gishiri; normal pubic arch, **no** avw trauma 152.0 cm

27/1-97 suprapubic mass, avw bulging into vagina, bladder overdistended (**EUO/BW 30 cm!!**, **the whole uterine sound went in**), no elevation after draining > 3,000 ml urine, EUO/B 2 cm increased bladder capacity (longitudinal diameter **30-2 = 28 cm**, **atonic bladder**) FOLEY Ch 18; free urine flow

09.02 + 19.03.97 not leaking at all cath removed bladder drill
24.03.97 not leaking at all, no incontinence, normal miction
insp/ healed, good elevation, no stress incontinence
14.07.97 not leaking at all, no incontinence, normal miction healed, no stress



fsrg (kano city)

female

14 yr

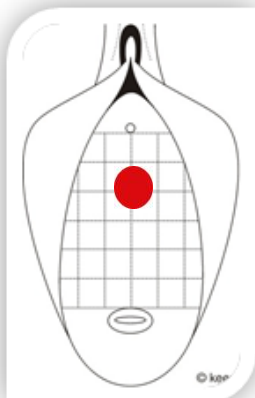
03/02-97

diagnosis: PI, \pm 2 cm 0 necrotic UVVF slightly to the R, **leaking urine for 7 days** which started immediately following obstructed labor for 1 day, at home an SB female, married 2 yr ago pre(menarche 1 yr later), not living at her husband, no menstruation, no h/o drop foot (R grade 4 and L grade 4), no RVF, no h/o yankan gishiri; borderline pubic arch
 EUO/F 2 cm, F/C 6 cm 155.0 cm

03.02.97 FOLEY Ch 18; free urine flow, EUO/BW 12 cm, good elevation and EUO/B 2 cm will it heal spontaneously?
 normal bladder capacity (longitudinal diameter 12-2 = 10 cm)

23.02 + 09.03.97 not leaking at all cath removed bladder drill
 18.03.97 not leaking at all, no incontinence, normal miction
 insp/ healed, good elevation, no stress incontinence

03.04 + 06.05.97 idem
 04.08.97 not leaking at all, no incontinence, normal miction healed, no stress



2 cm

KANO

cath 453

rhrg (kano)

female

23 yr

03/02-97

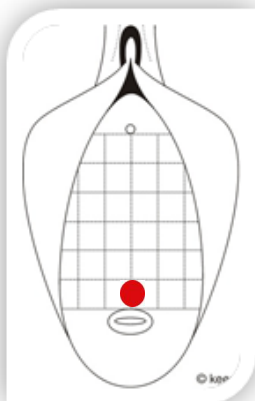
diagnosis: PVI (0 alive), 1 cm 0 necrotic vesicovaginal fistula type I midline, **leaking urine for 6 days** which started 4 days following an obstructed labor for 2 days, in hospital SB male, married 10 yr ago pre(menarche 2 mth later), not living with husband, no menstruation, no (h/o) drop foot, no RVF, no h/o yankan gishiri; normal pubic arch
EUO/F 7 cm, F/C 0 cm 159.0 cm

03.02.97 FOLEY Ch 18; free urine flow, EUO/BW 12 cm, moderate elevation, EUO/B 4 cm will it heal spontaneously?
normal bladder capacity (longitudinal diameter 12-4 = 8 cm)

09.02.97 not leaking at all; insp/ healing

03.03 + 09.03.97 not leaking at all cath removed bladder drill

14/07-97 not leaking at all, no incontinence, normal miction
insp/ healed, moderate elevation, no stress incontinence



1 cm

KANO

cath 454

mzb (kano)

female

16 yr

16/12-97

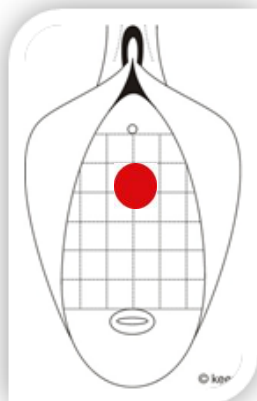
diagnosis: PI, \pm 2 cm 0 necrotic urethrovesicovaginal fistula at midline, **leaking urine for 8 days** that started 2 days following obstructed labor for 4 days, in hospital (eclampsia) SB male, married 4 yr ago pre(menarche 4 mth later), not with husband, no menstruation, drop foot R (grade 3) and L (grade 4), no RVF, no h/o yankan gishiri; narrow pubic arch
EUO/F 2 cm, F/C 6 cm 152.0 cm

16/12-96 FOLEY Ch 18; free urine flow, EUO/BW 11 cm, good elevation and EUO/B 2 cm will it heal spontaneously?
normal bladder capacity (longitudinal diameter 11-2 = 9 cm)

30/12-96 not leaking at all; insp/ seems healing

13/01-97 not leaking at all healed cath removed bladder drill

26/01-97 not leaking at all, no incontinence, normal miction
insp/ healed, good elevation, no stress incontinence



2 cm

ask (katsina)

female

38 yr

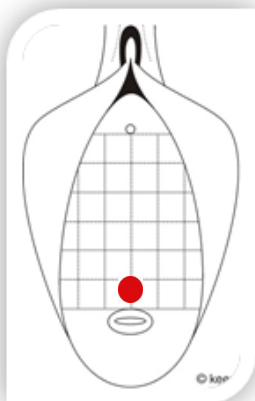
30/12-96

diagnosis: PVI (3 alive), 1 cm 0 necrotic vesicovaginal fistula type **I** midline, **leaking urine for 10 days** which started 4 days (upon catheter removal) following CS b.c.o. obstructed last labor for 2 days, SB female, married 25 yr ago pre(menarche 4 mth later), still living with husband, no menstruation, drop foot R (grade 3), no RVF, no h/o yankan gishiri; normal pubic arch
 EUO/F 8 cm, F/C 0 cm 150.0 cm

30/12-96 FOLEY Ch 18; free urine flow, EUO/BW 10 cm, moderate elevation, EUO/B 3 cm will it heal spontaneously?
 normal bladder capacity (longitudinal diameter 10-3 = 7 cm)

13/1-97 not leaking at all; insp/ seems healing

26/1-97 not leaking at all healed cath removed bladder drill



1 cm

KANO

cath 456

adzu (kano city)

female

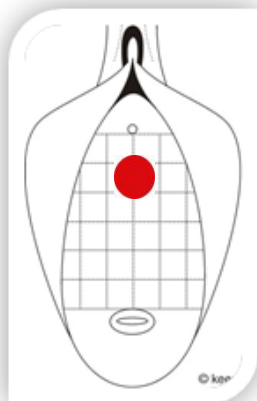
16 yr

10/02-97

diagnosis: PI, \pm 1.5 cm 0 urethrovesicovaginal fistula with circumferential defect type **IIA_Bb, leaking urine for 51 days** which started immediately following obstructed labor of 2 days, in hospital SB male, married 4 yr ago pre(menarche 8 mth later), not living at husband, no menstruation, drop foot R (grade 4) and L (grade 4), no RVF, yankan gishiri by ungozoma during labor; narrow pubic arch, moderate vagina stenosis
 EUO/F 1 cm, F/C 4 cm, AU/AB 0.5 cm 151.0 cm

10/2-97 dissection, caudad fixation of anterior bladder wall to symphysis/"urethra", transverse bladder/"urethra" closure by inverting chromic catgut, FOLEY Ch 18, transverse avw closure with 5x everting supramid, vagina pack; free urine flow, EUO/BW 11 cm, good elevation, EUO/B 1.5 cm
 normal bladder capacity (longitudinal diameter 11-1.5 = 9.5 cm)
difficult due to poor accessibility **anesthetic**

23.02 + 09.03.97 not leaking at all cath removed bladder drill
 17.03.97 leaking 6 ?miction? healed, stress +++
 26.05 + 16.11.97 not leaking, incontinence +, miction healed, stress
 15/12-97 not leaking at all, no incontinence, normal miction after bladder drill
 insp/ healed, moderate elevation, no stress incontinence



1.5 cm

hadgn (kano)

female

29 yr

07/01-97

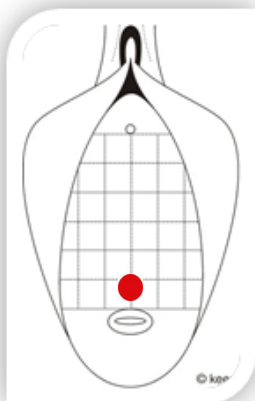
diagnosis: PII (all alive), necrotic \pm 1 cm 0 vesicovaginal fistula **IIAa** midline, **leaking urine for 7 days** which started 5 days (upon catheter removal) following CS b.c.o. an obstructed last labor for 3 day, live female, married 6 yr ago post(menarche 10 yr earlier) still living with husband, no menstruation, no (h/o) drop foot, no RVF, no h/o yankan gishiri; normal pubic arch
EUO/F 8 cm, F/C 0 cm 158.0 cm

07.01.97 FOLEY Ch 18; free urine flow, EUO/BW 12 cm, good elevation and EUO/B 4 cm
normal bladder capacity (longitudinal diameter 12-4 = 8 cm)

21/01-97 not leaking at all; insp/ healing

03.02.97 not leaking at all; insp/ healed; catheter removed

03/03-97 not leaking at all, no incontinence, normal miction
insp/ healed, good elevation, no stress incontinence



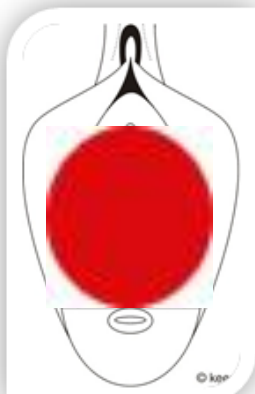1 cm

hsrg (kano) female 16 yr 16/02-97

diagnosis: **PI, totally indurated avw (no fistula/no stress incontinence), leaking urine for 16 days** which started immediately following obstructed labor for 2 days, in hospital a live female, married 2 yr ago post(menarche 1 yr earlier), not living with husband, no menstruation, no (h/o) drop foot, no RVF, no h/o yankan gishiri; borderline pubic arch 144.0 cm

16.02.97 FOLEY Ch 18; free flow of urine, EUO/BW 9 cm, **no** elevation and EUO/B 2 cm
normal bladder capacity (longitudinal diameter 9-2 = 7 cm)
if leakage continues for gv testing!

02.03 + 09.03.97 not leaking at all healed cath removed bladder drill
24/03-97 not leaking at all, no incontinence, normal miction
insp/ healed, good elevation, no stress incontinence



total avw induration

KANO

cath 459

awsrz (kano city)

female

15 yr

23/02-97

diagnosis: PI, necrotic \pm 2 cm 0 urethrovesicovaginal fistula at midline, **leaking of urine for 7 days** which started immediately following obstructed labor of 2 days, in hospital a SB male, married 2 yr ago post(menarche 3 mth earlier), not living at her husband, no menstruation, drop foot R (grade 3), no RVF, no h/o yankan gishiri, borderline pubic arch
 EUO/F 2 cm, F/C 4 cm 160.0 cm

23/2-97 FOLEY Ch 18; free urine flow, EUO/BW 12 cm, moderate elevation, EUO/B 2.5 cm seems to be deep necrosis!
 normal bladder capacity (longitudinal diameter 12-2.5 = 9.5 cm)

09.03.97 not leaking at all fistula

10.03 + 17.03.97 pat not ready for ps

24/03-97 operation: UVVF-repair

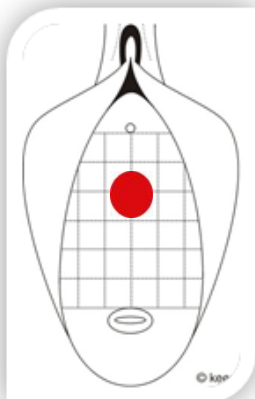
vvf 1478

08.04 + 21.04.97 not leaking at all cath removed bladder drill

08.05.97 not leaking, incontinence \pm , normal miction healed, stress +

20/05-97 not leaking at all, no incontinence, normal miction

insp/ healed, good elevation, no stress incontinence



2 cm

asm (kano)

female

15 yr

02/03-97

diagnosis: PI, ± 1x0.2 cm longitudinal necrotic urethrovesicovaginal fistula slightly to R, **leaking urine for 4 days** which started 11 days following obstructed labor for 1 day, in hospital (eclampsia) SB male, married 2 yr ago post(menarche 2 mth earlier), no living with husband, no h/odrop foot (but L grade 4), no RVF, no h/o yankan gishiri; narrow pubic arch
 EUO/F 3 cm, F/C 3 cm 146.0 cm

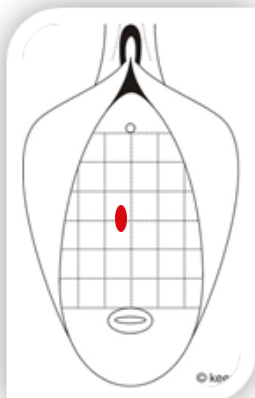
02.03.97 FOLEY Ch 18; free urine flow, EUO/BW 10 cm, poor elevation and EUO/B 2.5 cm probably it will heal spontaneously
 normal bladder capacity (longitudinal diameter 10-2.5 = 7.5 cm)

16.03 healing + 30.03.97 not leaking at all cath removed bladder drill

08.04.97 not leaking at all, no incontinence, normal miction
 insp/ healed, good elevation, no stress incontinence

08.05 + 07.07.97 idem

01.09.97 not leaking at all, no incontinence, normal miction healed, no stress



1x0.2 cm

mirk (kano city) female 16 yr 02/03-97

diagnosis: PI, ± 2.5 cm 0 necrotic urethrovesicovaginal fistula **IIAa**, necrotic pvw, **leaking urine/incontinence of stools and flatus for 6 days** which started 6 days following obstructed labor for 2 days, in hospital SB female, married 3 yr ago pre(menarche 5 mth later), not living with husband, no menstruation, drop foot R (grade 4) and L (grade 2-3), no h/o yankan gishiri; narrow pubic arch
EUO/F 1.5 cm, F/C 4 cm, I/PVWN 0 cm, PVWN/C 0 cm 154.0 cm

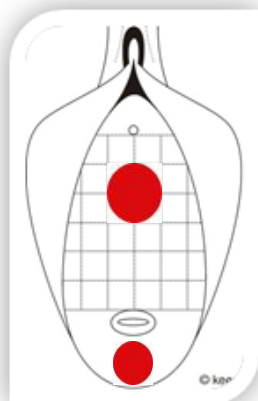
02.03.97 FOLEY Ch 18; free urine flow, EUO/BW 10 cm, poor elevation and EUO/B 2 cm seems to be deep necrosis!
normal bladder capacity (longitudinal diameter 10-2 = 8 cm)

25.03.97 distal urethra loss (due to catheter) in 3 cm fistula now type **IIBa**
25/03-97 operation: urethra/avw reconstruction vvf 1483

08.04 + 21.04.97 not leaking at all cath removed bladder drill

28.04.97 not leaking at all, no incontinence, normal miction stools/flatus ok
insp/ **both** healed, good elevation, no stress incontinence

15.12.97 not leaking at all, no incontinence, normal miction healed, no stress



2.5 cm

traumatized continence mechanism: stress incontinence

fmsg (kano) female 14 yr 16/03-97

diagnosis: PI, ± 1.5 cm necrotic "urethrovesicovaginal fistula" **IIAa, leaking urine for 4 days** that started 9 days following obstructed labor of 2 days, in hospital SB male, married 1.5 yr ago pre(menarche 5 mth later), not living at her husband, no menstruation, drop foot R (grade 2) and L (grade 2), no RVF, no h/o yankan gishiri borderline pubic arch, **objective** stress incontinence as well
EUO/F 2 cm, F/C 5 cm 154.0 cm

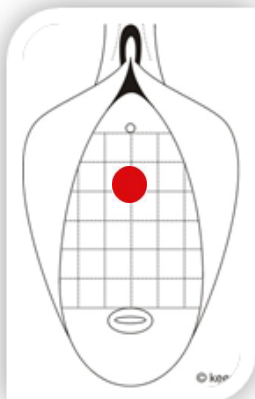
16/3-97 FOLEY Ch 18; free urine flow, EUO/BW 10 cm, moderate elevation, EUO/B 2.5 cm necrosis seems not too deep
normal bladder capacity (longitudinal diameter 10-2.5 = 7.5 cm)
probably it will heal **spontaneously**

30.03 healed + 14.04.97 not leaking at all cath removed bladder drill

22.04.97 not leaking at all, no incontinence, normal miction
insp/ healed, good elevation, no stress incontinence

20.05.97 idem

30.06.97 not leaking at all, no incontinence, normal miction healed, no stress



1.5 cm

zyk (kano city)

female

28 yr

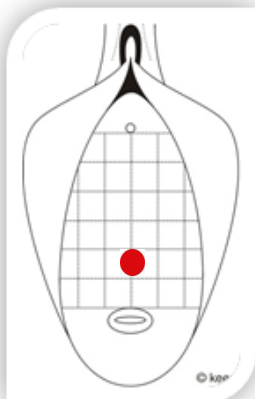
16/03-97

diagnosis: PIX (6 alive), **leaking urine always day/night for 6 days** which started 14 days following obstructed last labor for 3 days, at home SB male, married 16 yr ago pre(menarche 1 yr later), still living at husband, no menstruation, no (h/o) drop foot, no RVF, no h/o yankan gishiri; normal pubic arch 160.0 cm
no cooperation whatsoever so examination not possible

16/3-97 FOLEY Ch 18; free urine flow, EUO/BW 12 cm, no elevation (avw bulging into vagina), EUO/B 3 cm
normal bladder capacity (longitudinal diameter 12-3 = 9 cm)

17/3-97 not leaking at all; 80 ml gv: **no** leakage
30.03 + 14.04.97 not leaking at all

06/05-97 catheter out not leaking, incontinence +, normal miction
insp/ healed, poor elevation, stress ++



KANO
fistula and ?atonic bladder??

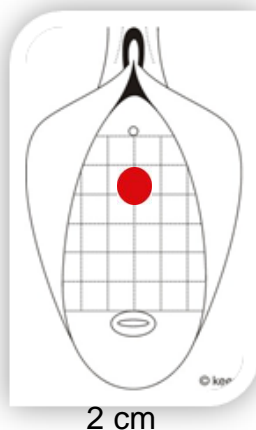
cath 464

amdw (kano) female 15 yr 23/03-97

diagnosis: Pl, \pm 2 cm 0 **necrotic** urethrovesicovaginal fistula **IIAa, leaking of urine for 9 days** which started 1 day following obstructed labor for 5 days, at home SB male, married 3 yr ago pre(menarche 1 yr later), not living at her husband, no menstruation, drop foot R (grade 3) and L (grade 4), no RVF, yankan gishiri during labor by ungozoma; borderline pubic arch
EUO/F 2 cm, F/C 7 cm 165.0 cm

23/3-97 no suprapubic mass, avw bulging into vagina, **objective** stress incontinence, bladder overdistended (EUO/BW 15 cm), poor elevation after draining 300 ml of urine; FOLEY Ch 18, free flow of urine, EUO/B 3 cm increased bladder capacity (longitudinal diameter 15-3 = 12 cm, **atonic bladder??**)
deep necrosis, will it still heal spontaneously?
photographic documentation on 23/3-97

30.03 **seems to be healing** + 08.04.97 not leaking, incontinence +
25.04.97 not leaking at all cath removed bladder drill



aidg (kano city)

female

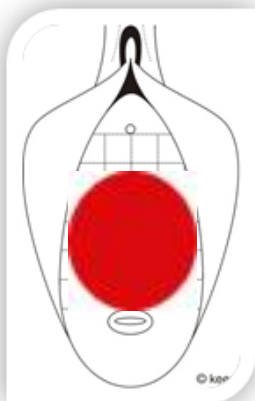
15 yr

09/06-97

diagnosis: PI, **extensive** \pm 6 cm 0 avw **IIAa** trauma, **leaking of urine for 4 days** which started 27 days?? following obstructed labor for 3 days, in hospital an SB male, married 1.5 yr ago post(menarche 3 mth earlier), still living with husband, no menstruation, drop foot R (grade 2) and L (grade 4), no RVF, no yankan gishiri; borderline pubic arch, spontaneous miction \pm , **objective stress incontinence**
 EUO/AVWT 2 cm, AVWT/C 0 cm 147.0 cm

09/06-97 FOLEY Ch 18; free urine flow, EUO/BW 10 cm, poor elevation and EUO/B 2.5 cm
 normal bladder capacity (longitudinal diameter 10-2.5 = 7.5 cm)
 "acceptable" position UV-junction **not** against middle third symphysis
documented 10/6-97

23.06 documented + 07.07.97 insp_gv: healed cath removed bladder drill
 24.07.97 not leaking at all, no incontinence, normal miction
 insp/ healed, good elevation, no stress incontinence
 25.08 + 09.11.97 idem
 15.12.97 not leaking at all, no incontinence, normal miction healed, no stress



6 cm

KANO

cath 466

mtrg (kano)

female

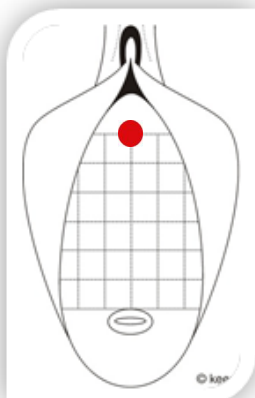
10 yr

09/06-97

diagnosis: P0, leaking urine for 10 yr which started immediately following yankan beli by ungozoma at 4 days of age; breast buds \pm , a few pubic "hairs", still **premenarche** it is not possible to examine her properly, tight hymen urine from euo at coughing

09/06-97 FOLEY Ch 12; free urine flow, EUO/BW 10 cm, good elevation and EUO/B 2.5 cm
normal bladder capacity (longitudinal diameter 10-2.5 = 7.5 cm)
catheter for 4 wk; then **gv examination!!**

30.06 + 07.07.97 not leaking at all cath removed bladder drill
08.07.97 not leaking at all, no incontinence, normal miction



ahgr (jigawa)

female

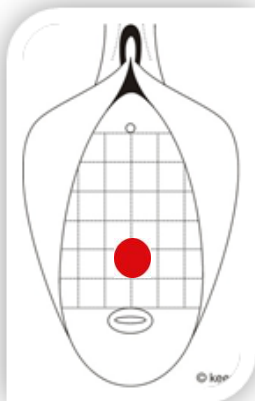
15 yr

15/06-97

diagnosis: PI, objective stress incontinence ++ (and spontaneous miction), **leaking of urine for 7 days** which started 9 days following an obstructed labor for 2 days, in hospital live female, married 3 yr ago pre(menarche 1 yr later) not living with her husband, no menstruation, drop foot R (grade 4) and L (grade 4), no RVF, yankan gishiri 2x by ungozoma during pregnancy (no leakage); normal pubic arch, **healed \pm 1 cm 0 avw trauma IIAa midline**
 EUO/AVWT 4 cm, AVWT/C 1 cm 160.0 cm

15/06-97 FOLEY Ch 18; free urine flow, EUO/BW 10 cm, moderate elevation, EUO/B 2 cm
 normal bladder capacity (longitudinal diameter 10-2 = 8 cm)
 "acceptable" position of UV-junction not completely against the middle third of symphysis

30.06 + 14.07.97 not leaking at all cath removed bladder drill
 24/07-97 not leaking at all, no incontinence, normal miction
 insp/ healed, moderate elevation, no stress incontinence



1 cm

nmhg (kano city)

female

15 yr

22/06-97

diagnosis: PII (0 alive), \pm 2 cm 0 necrotic urethrovesicovaginal fistula **IIAa, leaking urine for 2 days** which started 4 days following an obstructed last labor for 3 days, in hospital an SB male, married 2 yr ago post(menarche 4 mth earlier), not living with husband, no menstruation, drop foot R (grade 4) and L (grade 4), no RVF, yankan gishiri no; narrow pubic arch
EUO/F 2 cm, F/C 6 cm 158.0 cm

22/6-97 FOLEY Ch 18; free urine flow, EUO/BW 11 cm, good elevation and EUO/B 2 cm
normal bladder capacity (longitudinal diameter 11-2 = 9 cm)
acceptable position of UV-junction **against** middle/caudad third of symphysis
documented 23/6-97

30.06 + 14.07.97 not leaking, incontinence 0.2 cm fistula

15/07-97 operation: UVVF-repair

vvf 1537

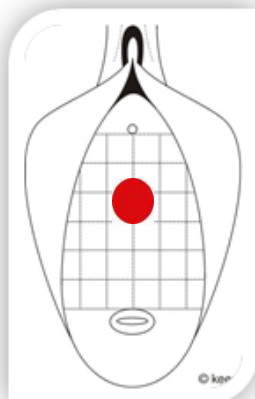
04.08 + 11.08.97 not leaking at all cath removed bladder drill

08.12.97 not leaking at all, no incontinence, normal miction

insp/ healed, good elevation, no stress incontinence

22.12.97 not leaking at all, no incontinence, normal miction

healed, no stress



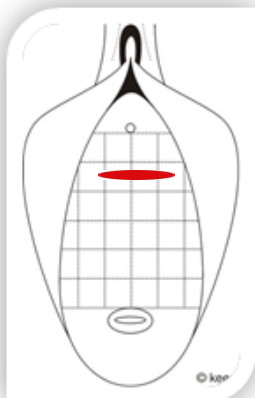
2 cm

rmsd (kano) female 14 yr 19/05-97

diagnosis: P0, overflow incontinence?? due to urethra stricture?? (transverse avw scar over proximal urethra fixed to symphysis), leaking urine for 1 yr which started 7 days following yankan gishiri by wanzami because "gishiri" she run away from husband (pat afraid of him) native medicine, married 1 yr ago post(menarche 1 mth earlier), not living with husband, normal menstruation; normal pubic arch, she says **no** operation
EUO/S 1.5 cm, S/C 5 cm 163.0 cm

19/5-97 gradual easy dilatation, FOLEY Ch 18; free urine flow, EUO/BW 12 cm, good elevation, EUO/B 2 cm
normal bladder capacity (longitudinal diameter 12-2 = 10 cm)
acceptable position of UV-junction **against** middle third of symphysis

23.06.97 not leaking at all cath removed bladder drill
14.07.97 not leaking at all, no incontinence, normal miction
insp/ healed, good elevation, no stress incontinence
11.08.97 idem
01.11.97 not leaking at all, no incontinence, normal miction healed, no stress

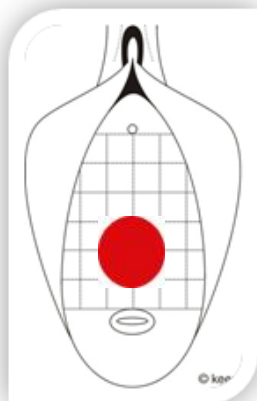


mag (jigawa) female 25 yr 25/04-97

diagnosis: PII (1 alive), \pm 3 cm 0 avw trauma over bladder neck/base, **leaking of urine for 12 days** (spontaneous miction) which started 15 days following obstructed last labor for 2 days, in hospital SB male, married 12 yr ago post(menarche 1 mth earlier), still living with husband, no menstruation, drop foot R (grade 3), no RVF, no yankan gishiri; normal pubic arch, seeping thru
EUO/AVWT 4 cm, AVWT/C 1 cm 157.0 cm

25/4-97 FOLEY CH 18; free urin flow, EUO/BW 12 cm, moderate elevation, EUO/B 4 cm "necrosis" not too deep
normal bladder capacity (longitudinal diameter 12-4 = 8 cm)
good position of UV-junction but **not completely** against cephalad/middle third of symphysis

06.05 + 19.05.97 not leaking at all healed cath removed bladder drill
28.05.97 not leaking at all, no incontinence, normal miction
insp/ healed, good elevation, no stress incontinence
30.06 + 14.07 + 08.09 + 07.10.97 idem
05/01-98 not leaking at all, no incontinence, normal miction perineum pain
insp/ healed, good elevation, no stress incontinence



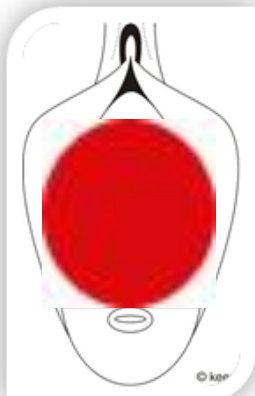
3 cm 0

smkhh (kano city) female 15 yr 12/05-97

diagnosis: PI, stress incontinence grade III, healing extensive avw trauma **IIBa** (total avw), **leaking urine for 28 days** which started immediately following obstructed labor for 2 days, in hospital SB male, married 2 yr ago pre(menarche 1 day later), not living with her husband, no menstruation, no (h/o) drop foot, also pvw trauma but no RVF and no yankan gishiri; normal pubic arch, objective stress incontinence +++
EUO/AVWT 0 cm, AVWT/C 0 cm, EUO/C 10 cm 158.0 cm

12/5-97 FOLEY Ch 18; free urine flow, EUO/BW 12 cm, poor elevation and EUO/B 3 cm
normal bladder capacity (longitudinal diameter 12-3 = 9 cm)
poor position UV-junction **away** from middle third of symphysis

03.06 + 10.06.97 not leaking at all cath removed bladder drill
30/06-97 not leaking at all, no incontinence, normal miction
insp/ healed, good elevation, no stress incontinence



extensive avw trauma

ahmm (kano)

female

15 yr

30/06-97

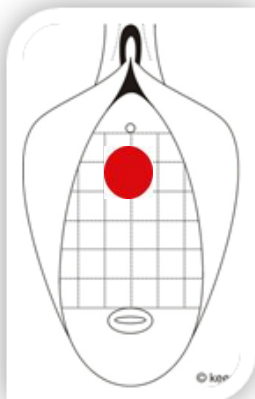
diagnosis: PI, \pm 2 cm 0 "necrotic" urethrovesicovaginal fistula? **IIAa, leaking urine for 3 days** which started immediately following obstructed labor of 2 days, on her way to hospital live male, married 1 yr 4 mth ago post(menarche 3 mth earlier), still living with husband, no menstruation, drop foot R (grade 4), no RVF, no yankan gishiri; narrow pubic arch, objective stress incontinence +

EUO/AVWN 1 cm, AVWN/C 5 cm

148.0 cm

30/6-97 FOLEY Ch 18; free urine flow, EUO/BW 12 cm, poor elevation (avw bulging into vagina), EUO/B 2 cm
normal bladder capacity (longitudinal diameter 12-2 = 10 cm)
poor position UV-junction **away from** middle/caudad third of symphysis
documented 30/6-97

15.07 documented + 28.07.97 not leaking at all cath removed blad drill
25/08-97 not leaking at all, no incontinence, normal miction
insp/ healed, good elevation, no stress incontinence



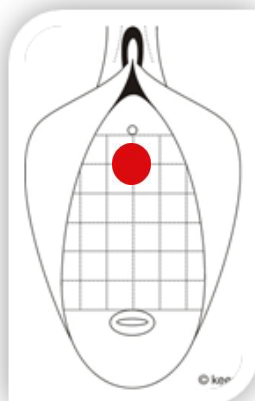
2 cm

ynum (kano) female 15 yr 30/06-97

diagnosis: PI, overflow incontinence due to atonic bladder, ± 2 cm 0 "necrotic" avw trauma **IIB_Aa** over UV-junction, **leaking urine for 8 days** which started immediately following obstructed labor of 2 days, in hospital SB male, married 2 yr ago pre(menarche 5 mth later) still living with husband, no menstruation, no (h/o) drop foot, no RVF, no yankan gishiri; borderline pubic arch
EUO/AVWT 1 cm, AVWT/C 8 cm 159.0 cm

30/6-97 suprapubic mass, avw bulging into vagina, bladder overdistended (EUO/BW 22 cm!, sound reaches cephalad from umbilicus), moderate elevation after draining > 750 ml of concentrated urine and EUO/B 2 cm **increased** bladder capacity (longitudinal diameter 22-2 = 20 cm, **atonic bladder**)
acceptable position of UV-junction but **not completely** against middle third of symphysis

13.07 + 28.07.97 not leaking at all cath removed bladder drill
04.08.97 not leaking at all, no incontinence, normal miction
insp/ healed, good elevation, no stress incontinence
18.08.97 idem
09.11.97 not leaking at all, no incontinence, normal miction healed, no shress



2 cm

rsdn (kano city)

female

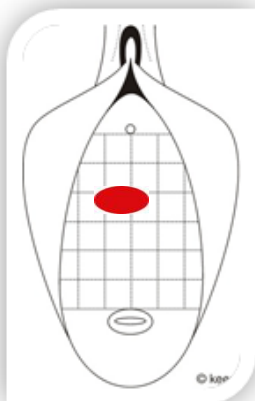
15 yr

30/06-97

diagnosis: PI, \pm 2x1 cm healing urethrovesicovaginal fistula **IIAa** at midline/R, **leaking urine for 35 days** which started immediately following obstructed labor for 2 days, in hospital SB male, married 1 yr 4 mth ago post(menarche 4 mth earlier), still living with husband, no menstruation, no (h/o) drop foot, no RVF, no yankan gishiri; normal pubic arch, still seeping thru \pm
 EUO/F 3 cm, F/C 5 cm 153.0 cm

30/6-97 FOLEY Ch 18; free urine flow, EUO/BW 11 cm, good elevation and EUO/B 3 cm
 normal bladder capacity (longitudinal diameter 11-3 = 8 cm)
 good position of UV-junction **against** cephalad/middle third of symphysis

14.07 + 28.07.97 not leaking at all cath removed bladder drill
 11.08.97 not leaking at all, no incontinence, normal miction
 insp/ healed, good elevation, no stress incontinence
 08.09 + 07.10.97 idem
 01.02.98 not leaking at all, no incontinence, normal miction healed, no stress



2x1 cm

mhrd (kano city)

female

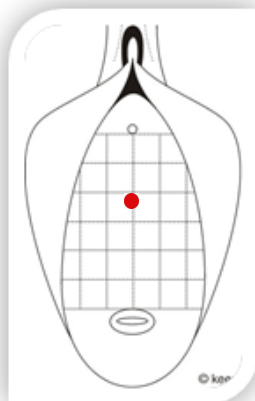
17 yr

01/07-97

diagnosis: PI, \pm 0.2 cm 0 urethrovesicovaginal fistula **IIAa** midline, **leaking of urine for 28 days** which started 13 days following an obstructed labor for 1 day, in hospital live male, married 1 yr ago post(menarche 3 yr earlier), not living with husband, no menstruation, no (h/o) drop foot, no RVF, no yankan gishiri; narrow pubic arch
EUO/F 3 cm, F/C 5 cm 159.0 cm

01/07-97 transverse incision thru fistula, dissection, transverse bladder/urethra closure by inverting chromic catgut, FOLEY Ch 18, transvrse avw closure by everting chromic catgut/3x supramid, vagina pack; free urine flow, EUO/BW 12 cm, good elevation and EUO/B 3 cm anesthetic
normal bladder capacity (longitudinal diameter 12-3 = 9 cm)
good position of UV-junction **against** cephalad/middle third of symphysis

16.07 + 24.07 + 28.07.97 not leaking at all cath removed bladder drill
04.08.97 not leaking at all, no incontinence, normal miction
insp/ healed, good elevation, no stress incontinence
18.08.97 not leaking at all, no incontinence, normal miction healed, no stress



0.2 cm

mrmrk (kano city)

female

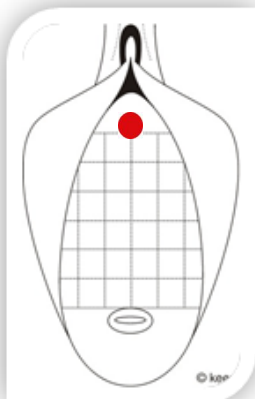
16 yr

07/07-97

diagnosis: PI, overflow incontinence due to **atonic bladder** (no spontaneous miction), **leaking of urine for 8 days** which started immediately following obstructed labor for 1 day, in hospital SB male, married 2 yr ago post(menarche 7 mth earlier), still living with husband, no menstruation, no (h/0) drop foot, no RVF, no yankan gishiri; normal pubic arch, no avw trauma
174.0 cm

07/07-97 suprapubic mass, avw bulging into vagina, bladder overdistended (EUO/BW 20 cm), moderate elevation after draining > 1,000 ml of urine, EUO/B 3 cm
increased bladder capacity (longitudinal diameter 20-3 = 17 cm, **atonic bladder**)
poor position UV-junction away from middle third of symphysis

20.07 + 04.08 + 11.08.97 not leaking at all cath removed bladder drill
18.08.97 not leaking at all, no incontinence, normal miction
insp/ healed, good elevation, no stress incontinence
01.09 + 29.09.97 idem
16.11.97 not leaking at all, no incon, normal miction healed, no stress R=5 L=4-5

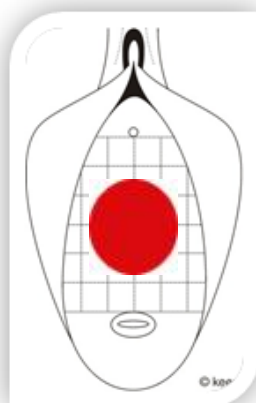


askt (kano) female 20 yr 13/07-97

diagnosis: PIV (2 alive), \pm 5 cm 0 **deep** necrotic avw trauma, overflow incontinence due to **atonic bladder, leaking urine for 6 days** that started immediately following obstructed last labor for 7 days, in hospital SB male, married 8 yr ago pre(menarche 1 yr later), not living with husband, no menstruation, drop foot R (grade 2) and L (grade 0), no RVF, no yankan gishiri; normal pubic arch
EUO/AVWN 2.5 cm, AVWN/C 2 cm 151.0 cm

13/7-97 suprapubic mass, avw bulging into vagina, bladder overdistended (EUO/BW 25 cm, tip cephalad from umbilicus), poor elevation after draining > 1,500 ml concentrated urine, EUO/B 2 cm)
increased bladder capacity (longitudinal diameter 25-2 = 23 cm, **atonic bladder**)
poor position UV-junction **away** from middle third of symphysis
full photographic documentation (uterus R after urine draining)

24.07 + 04.08 + 18.08.97 leaking fistula
02-09-97 operation (im): UVVF-repair
total incontinence
26/10-98 operation: anterior colposuspension vvf 1781
11.07.99 not leaking at all, no incontinence, normal miction
Insp/ healed, good elevation, no stress incontinence
05.10.99 now leaking & miction **no compliance**
insp_gv/ good elevation, no stress incontinence, no obstruction



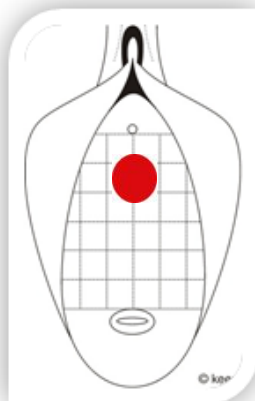
5 cm

rim (jigawa) female 19 yr 14/07-97

diagnosis: PIII (1 alive), \pm 2 cm 0 **obstetric necrotic** urethrovesicovaginal fistula **IIBb** with circumferential defect, **leaking urine for 21 days** which started immediately following obstructed last labor for 2 days, at home SB male, married 7 yr ago pre(menarche 1 yr later), not living with husband, no menstruation, drop foot R (grade 0) and L (grade 0), no RVF, yankan gishiri by ungozoma during last labor; normal pubic arch, **N.B. pat cannot stand or walk**
EUO/F 1 cm, F/C 5 cm, AU/AB 1 cm ?? cm

14/7-97 incision, dissection, suturing loose anterior bladder wall onto caudad symphysis/"urethra", circumferential UVVF-repair by end-to-end vesicourethrostomy by inverting chromic catgut, FOLEY Ch 18, transverse avw closure by everting chromic catgut/5x supramid, vagina pack; free urine flow, EUO/BW 12 cm, moderate elevation, EUO/B 1.5 cm)
first stage anesthetic
normal bladder capacity (long diameter 12-1.5 = 10.5 cm)
poor position UV-junction against middle/caudad third symphysis

28.07 + 04.08 + 11.08.97 not leaking at all cath removed bladder drill
18/08-97 not leaking, incontinence +, normal miction condition fair
insp/ healed, moderate elevation, stress incontinence +



2 cm

KANO

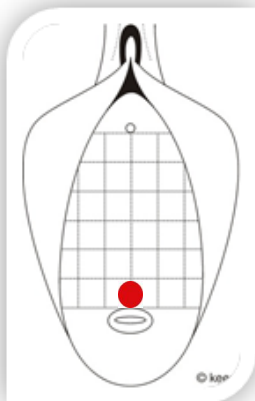
cath 479

zngm (kano) female 32 yr 20/07-97

diagnosis: PXI (4 alive), \pm 1 cm necrotic vesicovaginal fistula I in front of R cervix, **leaking of urine for 22 days** which started 2 days (upon catheter removal) following CS b.c.o. an obstructed last labor for 2 days, live female, married 20 yr ago pre(menarche 1 yr later), still living with her husband, no menstruation, drop foot R (grade 4) and L (grade 4), no RVF, yankan gishiri by ungozoma during first delivery 18 yr ago (no leakage); normal pubic arch
EUO/F 9 cm, F/C 0 cm 152.0 cm

20/7-97 FOLEY Ch 18; free urine flow, EUO/BW 12 cm, poor elevation and EUO/B 2 cm
normal bladder capacity (longitudinal diameter 12-2 = 10 cm)
poor position UV-junction **away** from middle/caudad third symphysis
will it heal spontaneously??

04.08 + 11.08 leaking + 18.08.97 not leaking at all cath removed bl drill
01/09-97 not leaking at all, no incontinence, normal miction
insp/ healed, good elevation, no stress incontinence



1 cm

hlnyd (kano)

female

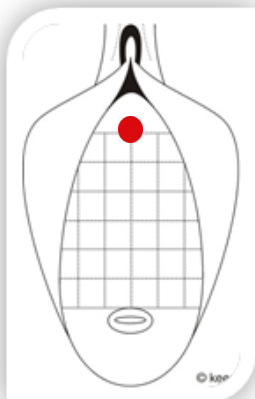
15 yr

04/08-97

diagnosis: PI, stress incontinence grade III, **leaking urine whilst lying/sitting/standing/walking for 10 days (spontaneous miction)** that started 2 days following obstructed labor of 2 day, in hospital SB male, married 3 yr ago pre(menarche 1 yr later), still living with husband, no menstruation, drop foot R (grade 4) and L (grade 4), no RVF, yankan gishiri during labor by ungozoma; pubic arch borderline, no fistula seen 146.0 cm

04/08-97 FOLEY Ch 18; free urine flow, EUO/BW 10 cm, moderate elevation, EUO/B 2 cm
normal bladder capacity (longitudinal diameter 10-2 = 8 cm)
poor position UV-junction **away** from middle/caudad third of symphysis

02.09.97 not leaking at all cath removed bladder drill
28/09-97 not leaking at all, no incontinence, normal miction
insp/ healed, moderate elevation, no stress incontinence



zagj (kano city)

female

14 yr

28/09-97

diagnosis: PI, ± 6 cm 0 avw trauma **IIAa** with multiple seeping through at distal tip, **leaking urine for 4 days** which started immediately following obstructed labor for 2 days, in hospital SB female, married 1 yr ago pre(menarche 2 mth later), not living with husband, no menstruation, drop foot R (grade 4) and L (grade 4), no RVF, no yankan gishiri; narrow pubic arch
EUO/AVWT 2 cm, AVWT/C 0 cm 159.0 cm

28/9-97 FOLEY Ch 18; free urine flow, EUO/BW 12 cm, moderate elevation, EUO/B 2 cm **will it heal spontaneously?**
normal bladder capacity (longitudinal diameter 12-2 = 10 cm)
acceptable position of UV-junction **against** middle third of symphysis

20.11.97 not leaking at all 1 cm fistula

R=4 L=4

21/10-97 operation: UVVF-repair

vvf 1587

17.11 + 23.11 + 01.12.97 not leaking at all cath removed bladder drill

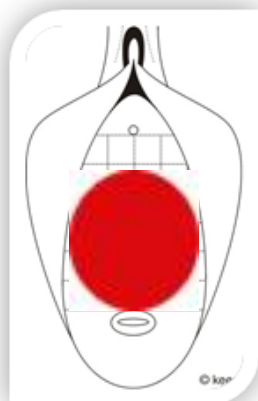
09.12.97 not leaking at all, no incontinence, normal miction

Insp/ healed, good elevation, no stress incontinence

22.12.97 idem

16.02.98 not leaking at all, no incontinence, normal miction

healed, no stress



6 cm

pogm (kano)

female

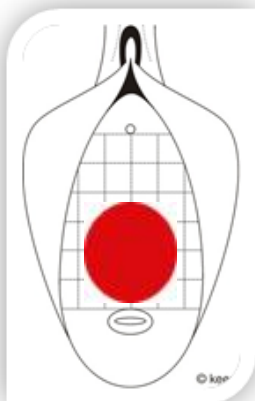
18 yr

05/10-97

diagnosis: PI, \pm 4 cm 0 avw trauma **IIAa** midline/L with seeping thru, **leaking urine for 14 days** that started immediately following obstructed labor for 3 days, in hospital a SB male, married 2 yr ago post(menarche 3 yr earlier), still living with husband, no menstruation, no (h/o) drop foot, no RVF, no yankan gishiri; a normal pubic arch
 EUO/AVWT 3 cm, AVWT/C 0 cm 168.0 cm

5/10-97 FOLEY Ch 18; free urine flow, EUO/BW 10 cm, moderate elevation, EUO/B 3 cm **probably it will heal spontaneously!**
 normal bladder capacity (longitudinal diameter 10-3 = 7 cm)
 "acceptable" position UV-junction **away** from middle third symphysis

20.10 healing + 03.11.97 not leaking at all cath removed bladder drill
 16.11.97 not leaking at all, no incontinence, normal miction
 insp/ healed, good elevation, no stress incontinence
 15.03.98 not leaking at all, no incontinence, normalmiction healed, no stress



4 cm

hur (kano city)

female

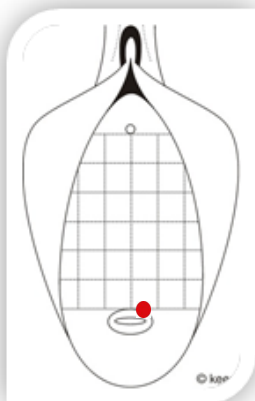
41 yr

05/10-97

diagnosis: PVI (3 alive), \pm 0.2 cm 0 CS vesico" cervico" vaginal I fistula L as demonstrated by gv, **leaking urine for 20 days** which started immediately following CS-(hysterectomy?) b.c.o. obstructed last labor for 3 days, SB male, married 30 yr ago pre(menarche 2 yr later), still living with husband, no menstruation, drop foot R (grade 4) and L (grade 4), no RVF, yankan gishiri by ungozoma during first labor; normal pubic arch
 EUO/F 8 cm, F/"CV" 0 cm 151.0 cm

5/10-97 FOLEY Ch 18; free urine flow, EUO/BW 11 cm, good elevation and EUO/B 3 cm
 normal bladder capacity (longitudinal diameter 11-3 = 8 cm)
 good position UV-junction **against** cephalad/middle third symphysis
 "cervix_vault" **fixed**, it is not possible now to see what exactly has been done but it seems like CS-hysterectomy

20.10 + 03.11.97 gv: no leakage catheter removed bladder drill
 09/11-97 not leaking at all, no incontinence, normal miction
 insp/ healed, good elevation, no stress incontinence



0.2 cm

zrikh (kano city)

female

14 yr

12/10-97

diagnosis: PI, overflow incontinence due to atonic bladder, \pm 2 cm 0 avw trauma, **leaking of urine for 15 days** which started immediately following an obstructed labor for 2 days, in hospital SB male, married 2 yr ago pre(menarche 8 mth later), still living with husband, no menstruation, drop foot R (grade 3) and L (grade 3) no RVF, no yankan gishiri; borderline pubic arch
 EUO/AVWT 1 cm, AVWT/C 8 cm 156.0 cm

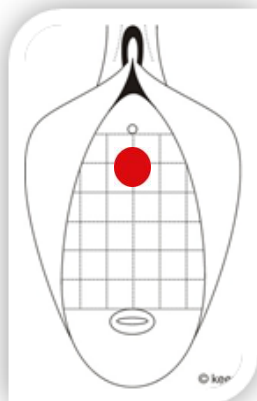
12/10-97 small suprapubic mass, avw bulging into vagina, bladder overdistended (EUO/BW 16 cm), poor elevation after draining 500 ml urine, EUO/B 2 cm **increased** bladder capacity (longitudinal diameter 16-2 = 14 cm, **atonic bladder**)
 poor position UV-junction **away from** middle/caudad third symphysis

27.10 + 03.11 + 24.11.97 not leaking at all cath removed bladder drill

08.12.97 not leaking at all, no incontinence, normal miction
 insp/ healed, good elevation, no stress incontinence

08.02.98 idem R=4 L=4

24.04.98 not leaking at all, no incontinence, normal miction healed, no stress



2 cm

KANO
atonic bladder with severe bladder distension (nursing neglect)

cath 485

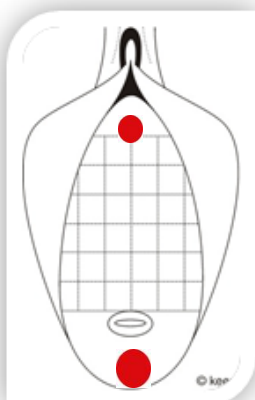
rvf

sar (Kano) female 16 yr 26/10-97

diagnosis: PI, overflow incontinence due to **atonic bladder, leaking urine for 4 days** which started 2 days following obstructed labor for 1 day, in hospital (eclampsia) live male, married 5 yr ago pre(menarche 2 yr later), not living with husband (still in hospital with cerebral palsy), no menstruation, a drop foot R (grade 4) and L (grade 4), no RVF but severe distal pvw trauma with 2-3E perineum rupture (**stool/flatus incontinence!**), no yankan gi-shiri; normal pubic arch, **no** avw trauma, large ulcers both buttocks (so though **not tested** ar must be negative with saddle anesthesia 09.05.13)

26/10-97 large suprapubic mass, avw bulging, bladder overdistended (EUO/ BW 25 cm, uterine sound goes completely in), moderate elevation after draining > 2,500 ml of urine, EUO/B 2 cm FOLEY Ch 18 160.0 cm **increased** bladder capacity (longitudinal diameter 25-2 = 23 cm, **atonic bladder**)
acceptable position of UV-junction **against** middle/caudad third of symphysis
full photographic documentation

23.11 documented R=4 L=4 + 08.12.97 not leaking cath removed bl drill
30.12.97 not leaking at all, no incontinence, normal miction
insp/ healed, good elevation, no stress incontinence
01.03.98 idem
31/05-98 not leaking at all, no incontinence, normal miction stools ok
insp/ healed, good elevation, no stress incontinence R=5 L=5



zbnck (kano city)

female

15 yr

20/09-97

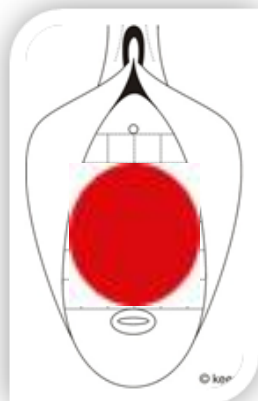
diagnosis: PI, extensive \pm 8 cm 0 necrotic avw trauma, **leaking urine for 4 days** which started immediately following obstructed labor for 2 days, in hospital SB male (pat still in eclampsia ward in poor condition), married 1.5 yr ago post(menarche 1 mth earlier), no menstruation, no RVF, no yankan gishiri; narrow pubic arch but further examination not possible EUO/AVWT 2 cm, AVWT/C 0 cm very poor condition

20/9-97 FOLEY Ch 18; free urine flow, EUO/BW 14 cm, moderate elevation, EUO/B 3 cm
normal bladder capacity (longitudinal diameter 14-3 = 11 cm)
good position UV-junction **not** against middle third of symphysis

2/11-97 catheter out since 2 days; not leaking, no incontinence, normal miction
general condition improved but still not o.k.
insp/ avw "healed", poor elevation, no stress incontinence
drop foot R (grade 0) and L (grade 2) 155.0 cm

16.02.98 idem condition ok

08/03-98 not leaking at all, no incontinence, normal miction R=1-2 L=5
insp/ healed, good elevation, no stress incontinence



8 cm

ahij (adamawa)

female

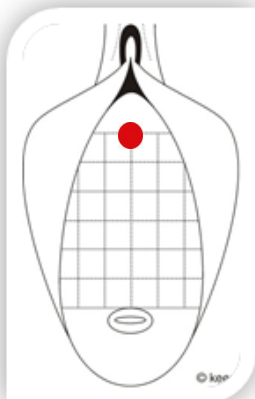
23 yr

09/11-97

diagnosis: PII (all alive), overflow incontinence due to **neurogenic? traumatic atonic bladder**, leaking urine for 5 mth which started immediately following road traffic accident with bilateral inferior/superior pubic rami fracture with moderate displacement of symphysis (conservatively treated), also spontaneous micturition with dysuria, married 10 yr ago pre(menarche 3 mth later), still living with husband, normal menstruation

9/11-97 suprapubic mass, avw bulging into vagina, bladder overdistended (EUO/BW 17 cm), poor elevation (only distal urethra fixed onto symphysis over 1.5 cm) after draining 750 ml of urine and EUO/B 2 cm foley ch18 **increased** bladder capacity (longitudinal diameter 17-2 = 15 cm, **atonic bladder**) 167.0 cm acceptable position of UV-junction **against** middle/caudad third of symphysis

23.1 + 21.12.97 not leaking at all cath removed bladder drill
12.01.98 not leaking at all, no incontinence, normal miction
insp/ healed, moderate elevation, no stress incontinence
10.08.98 not leaking at all, no incontinence, normal miction healed, no stress



KANO
age at menarche: 13 yr

cath 488
rvf

smrg (kano) female 18 yr 18/01-98

diagnosis: PI, **extensive** necrotic ± 6x4 cm avw, **extensive necrotic** total pvw trauma, **leaking urine for 2 days** which started 3 days following obstructed labor for 2 days, at home male SB, married 5 yr ago pre (menarche 3 mth later), still living with husband, no menstruation, drop foot R (grade 4) and L (grade 4), no yankan gishiri; **no** defecation yet, borderline pubic arch, **no fistula yet but objective stress incontinence ++ and intensive necrotic odor!**
EUO/AVWT 0 cm, AVWT/C 2 cm 169.0 cm

18/1-98 FOLEY Ch 18; free urine flow, EUO/BW 14 cm, moderate elevation, EUO/B 2 cm will it heal spontaneously?
normal bladder capacity (longitudinal diameter 14-2 = 12 cm but **certainly not an atonic bladder!!**) **documented 18/1-98**

02.02.98 not leaking 1 cm fistula **documented**
02/03-98 operation: UVVF-repair vvf 1665

17.03 + 04.05.98 not leaking at all cath removed bladder drill
21.06.98 not leaking at all, no incontinence, normal miction
insp/ healed, good elevation, no stress incontinence

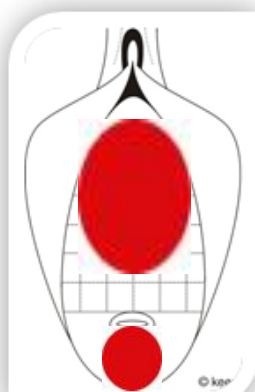
10.08.98 idem
04.10.98 not leaking at all, no incontinence, normal miction healed, no stress

25.09.01 "ba hanya" _severe introitus stenosis not leaking at all
15.07.02 operation: vaginoplasty vvf 2662

28.07.02 no complaints not leaking at all healed, no stress

10.03.03 amenorrhea for 5 mth not leaking at all **instructions**

28.10.03 PII (1 alive) live male by CS not leaking at all



6x4 cm

cause of obstruction/fistula from examination/operation findings

fmtb (kano city)

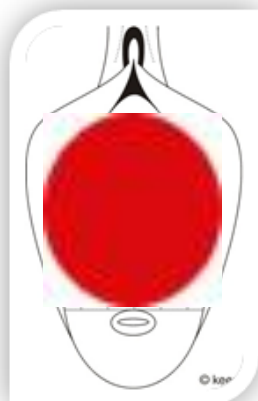female 27 yr

08/02-98

diagnosis: PIV (2 alive), **extensive** ± 8 cm 0 **necrotic** avw **IIBa** trauma, **leaking urine for 8 days** which started 6 days (upon catheter removal) following CS (**ruptured uterus**) b.c.o. obstructed last labor of 1 day, SB female, married 9 yr ago post(menarche 5 yr earlier), still admitted in hospital, no menstruation, drop foot R (grade 4-5), no RVF, no yankan gishiri; normal AP diameter/pubis arch, malpresentation/rotation
 EUO/AVWT 0 cm, AVWT/C 0 cm 163.0 cm

08/02-98 FOLEY Ch 18; free urine flow, EUO/BW 10 cm, poor elevation and EUO/B 2 cm probably it will become fistula!!
 normal bladder capacity (longitudinal diameter 10-2 = 8 cm)
 poor position UV-junction **away** from middle/caudad third symphysis

pat did not report for follow-up



8 cm

sgbd (kano city)

female

19 yr

20/01-98

diagnosis: PII (all alive), \pm 1 cm 0 necrotic urethrovesicovaginal fistula **IIAa** midline, **leaking urine for 10 days** which started 7 days following obstructed last labor for 1 day, at home live female, married 6 yr ago post(menarche 3 mth earlier), still living at her husband, no menstruation, no (h/o) drop foot, no RVF, no yankan gishiri; normal AP diameter/pubis arch, malrotation

EUO/F 4 cm, F/C 4 cm

159.0 cm

20/1-98 FOLEY Ch 18; free urine flow, EUO/BW 13 cm, moderate elevation, EUO/B 4 cm

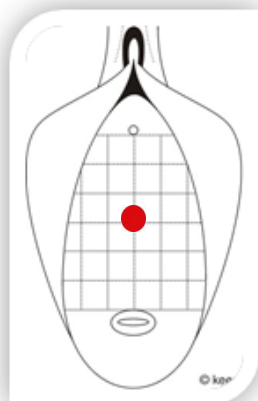
normal bladder capacity (longitudinal diameter 13-4 = 9 cm)

poor position UV-junction **away** from middle third of symphysis

08.02 + 02.03 + 22.03.98 not leaking at all cath removed bladder drill

24.04.98 not leaking at all, no incontinence, normal miction
insp/ healed, good elevation, no stress incontinence

28.06.98 not leaking at all, no incontinence, normal miction healed, no stress



1 cm

syaj (jigawa)

female

16 yr

15/02-98

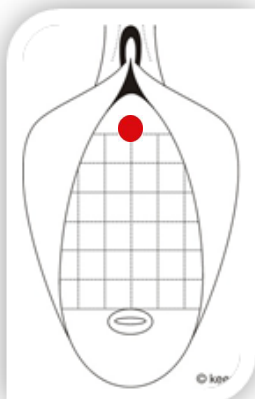
diagnosis: PI, overflow incontinence due to **atonic bladder, leaking urine for 25 days (no spontaneous miction)** which started 18 days following obstructed labor of 2 days, in hospital SB male, married 3 yr ago pre(menarche 3 mth later), still living with husband, no menstruation, no RVF, drop foot R (grade 4) and L (grade 4), no yankan gishiri; a normal AP diameter/pubis arch, healing avw trauma 165.0 cm

15/2-98 a small suprapubic mass, avw bulging into vagina, bladder overdistended (EUO/BW 17 cm), moderate elevation after draining 500 ml urine, EUO/B 2 cm (**vesiculization**) FOLEY Ch 18 **increased** bladder capacity (longitudinal diameter 17-2 = 15 cm, **atonic bladder**)
poor position UV-junction **not against** middle/caudad third symphysis

23.02 + 17.03 + 30.03.98 not leaking at all cath removed bladder drill

14.04.98 not leaking at all, no incontinence, normal miction
insp/ healed, goodelevation, no stress incontinence

07/06-98 not leaking at all, no incontinence, normal miction R=5 L=5
insp/ healed, good elevation, no stress incontinence



KANO

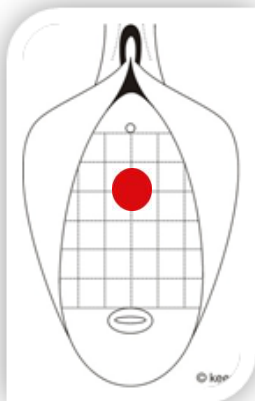
cath 492

huka (Kano) female 15 yr 15.02.98

diagnosis: PII (0 alive), ± 2 cm 0 necrotic urethrovesicovaginal fistula **IIAa** with already 0.5 cm defect, **leaking of urine for 21 days** which started immediately following obstructed last labor for 2 days, at home SB male, married 4 yr ago pre(menarche 2 yr later), not living with husband, no menstruation, drop foot R (grade 2) and L (grade 2), no RVF, no yankan gishiri; borderline AP diameter/ wide pubic arch
EUO/F 2 cm, F/C 5 cm 155.0 cm

15/2-98 FOLEY Ch 18; free urine flow, EUO/BW 12 cm, good elevation and EUO/B 2.5 cm **will it still heal??**
normal bladder capacity (longitudinal diameter 12-2.5 = 9.5 cm)
good position of UV-junction **against** middle third of symphysis
would have healed already by immediate indwelling catheter!!!!

23.03.98 not leaking at all cath removed bladder drill
30.03.98 not leaking, no incontinence, normal miction
insp/ healed, good elevation, no stress incontinence
14.04.98 not leaking at all, no incontinence, normal miction healed, no stress



2 cm

rdtr (jigawa)

female

25 yr

16/02-98

diagnosis: PV (3 alive), \pm 1 cm 0 vesicovaginal fistula **I** just in front of cervix, **leaking of urine for 29 days** which started immediately following obstructed last labor for 1 day, in hospital SB male, married 15 yr ago pre(menarche 2 yr later), not living with her husband, no menstruation, no (h/o) drop foot, no RVF, no yankan gishiri; normal AP diameter/pubis arch, malpresentation and/or rotation

EUO/F 5 cm, F/C 0 cm

158.0 cm

16/2-98 incision, sharp dissection, transverse bladder closure with inverting chromic catgut, FOLEY Ch 18, transverse avw closure by everting chromic catgut/ supramid and pack; free flow of urine, EUO/BW 11 cm, poor elevation, EUO/B 4 cm

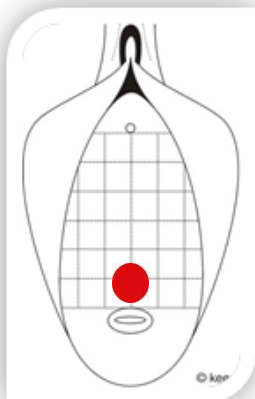
normal bladder capacity (longitudinal diameter 11-4 = 7 cm)

poor position UV-junction **away** from middle third of symphysis

02.03 + 17.03 + 30.03.98 not leaking at all cath removed bladder drill

04/05-98 not leaking at all, no incontinence, normal miction

insp/ healed, moderate elevation, no stress incontinence



1 cm

hakr (kano city)

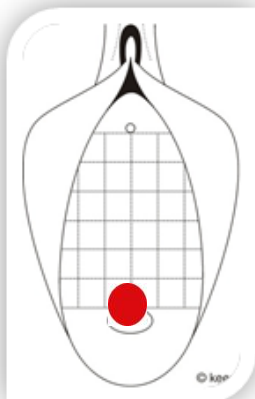
female 31 yr

22/02-98

diagnosis: PIII (2 alive), ?? cm necrotic CS-vesicocervicovaginal fistula I within totally necrotic cervix, **leaking urine for 7 days** which started 5 days (upon catheter removal) following CS b.c.o. obstructed last labor for 3 days, an SB female, married 20 yr ago pre(menarche 2 yr later), still with husband (coming from MMSH) no menstruation, drop foot L (grade 4), no RVF, no yankan gishiri; normal AP diameter/pubis arch
 EUO/F 8 cm, F/"C" 0 cm 138.0 cm

22/2-98 FOLEY Ch 18; free urine flow, EUO/BW 10 cm, moderate elevation, EUO/B 2 cm
 normal bladder capacity (longitudinal diameter 10-2 = 8 cm)
 poor position UV-junction **not against** middle/caudad third symphysis

08.03.98 not leaking at all nicely healing
 17.03 + 06.04.98 not leaking at all cath removed bladder drill
 14/04-98 not leaking at all, no incontinence, normal miction
 insp/ healed, moderate elevation, no stress incontinence



blssd (kano city)

female

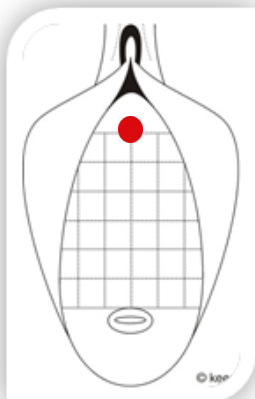
17 yr

01/03-98

diagnosis: PI, overflow incontinence due to **atonic bladder, leaking urine (no spontaneous miction) for 40 days** which started immediately following CS (20/12-98) b.c.o. obstructed labor for 2 days, SB male, married 1 yr ago post(menarche 3 yr earlier), not living with husband, no menstruation, drop foot L (grade 4), no RVF, no yankan gishiri; normal AP diameter/borderline pubic arch and almost healed avw trauma 161.0 cm

01/03-98 small suprapubic mass (obesity ++), avw "bulging" into vagina, bladder overdistended (EUO/BW 16 cm), good elevation after 400 ml urine drainage, EUO/B 3 cm FOLEY Ch 18
increased bladder capacity (longitudinal diameter 16-3 = 13 cm, **atonic bladder in spontaneous healing phase**)
 good position UV-junction **against** middle third of symphysis

30.03 + 06.04.98 not leaking at all cath removed bladder drill
 21.04.98 not leaking at all, no incontinence, normal miction
 insp/ healed, good elevation, no stress incontinence



balz (kano city)

female

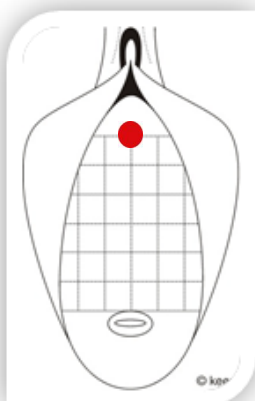
19 yr

22/03-97

diagnosis: PI, overflow incontinence due to **?atonic bladder?, leaking urine (no spontaneous miction) for 4 days** that started 3 days following obstructed labor for 1 day, at home live female, married 4 yr ago post (menarche 2 yr earlier), still living at husband, no menstruation, no (h/o) drop foot, no RVF, no yankan gishiri; normal AP diameter/pubis arch

22/3-97 no suprapubic mass, avw bulging into vagina, bladder "slightly" overdistended (EUO/BW 14 cm), poor elevation after draining 100 ml urine only, EUO/B 2 cm (**vesiculization**) FOLEY Ch 18 **increased** bladder capacity (longitudinal diameter 14-2 = 12 cm, **?atonic bladder?**) 157.5 cm poor position UV-junction **away from** middle/caudad third of symphysis **this would have probably healed spontaneously!**

- 14.04.98 cath out not leaking at all bladder drill
- 20.04.98 not leaking at all, no incontinence, normal miction
insp/ healed, good elevation, no stress incontinence
- 18.05.98 idem
- 12.07.98 not leaking at all, no incontinence, normal miction healed, no stress
- 23/06-03 **amenorrhea for 4 mth** not leaking at all **instructions**

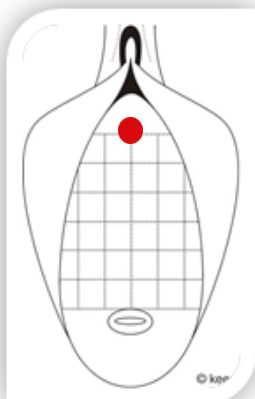


hyrl (kano city) female 14 yr 31/05-98

diagnosis: PI, overflow incontinence due to atonic bladder, **leaking urine for 3 days** which started 3 days following obstructed labor for 4 days, in hospital (eclampsia) an SB female, married 1 yr ago post(menarche 4 mth earlier), not living with husband, no menstruation, drop foot R (grade 4) and L (grade 4), no RVF, yankan gishiri no; narrow pubic arch/normal AP diameter, no trauma avw 159.0 cm

31/5-98 small suprapubic mass, avw "bulging" into vagina, bladder overdistended (EUO/BW 17 cm), moderate elevation after draining 400 ml urine, EUO/B 2 cm (**vesiculization**) FOLEY Ch 18 **increased** bladder capacity (longitudinal diameter 17-2 = 15 cm, **atonic bladder**) acceptable position of UV-junction **against** middle/caudad third of symphysis

14.06 + 30.06.98 not leaking at all cath removed bladder drill
12.07.98 not leaking at all, no incontinence, normal miction
insp/ healed, good elevation, no stress incontinence
07.09.98 idem
08.11.98 not leaking at all, no incontinence, normal miction healed, no stress
19/05-03 **amenorrhea for 6 mth** not leaking at all **instructions**



KANO

cath 499

zbaz (kano city)

female

14 yr

31/05-98

diagnosis: PI, ± 4 cm 0 **necrotic** urethrovesicovaginal **IIAa** fistula, **leaking of urine for 4 days** which started 1 day following obstructed labor for 2 days, in hospital SB female, married 1 yr ago pre(menarche 2 mth later), not living with husband, no menstruation, no RVF, drop foot R (grade 3) and L (grade 3), no yankan gishiri; normal AP diameter/narrow pubic arch
EUO/F 4 cm, F/C 4 cm 144.0 cm

31/5-98 FOLEY Ch 18; free urine flow, EUO/BW 9 cm, moderate elevation, EUO/B 3 cm **will it heal spontaneously?**
moderate bladder capacity (longitudinal diameter 9-3 = 6 cm)

14.06.98 leaking balloon in fistula

15/06-98 operation: UVVF-repair VVF 1710
0.5 cm fistula

22.02.99 operation: UVVF-repair VVF 1826

14.03.99 not leakinh at all cath removed bladder drill

16.05.99 not leaking at all, no incontinence, normal miction
insp/ healed, good elevation, no stress incontinence

11.07.99 idem

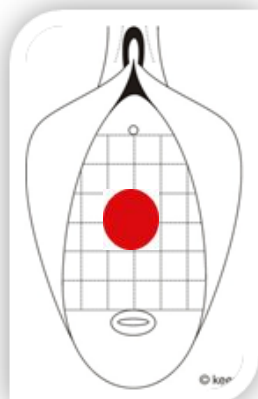
16.08.99 not leaking at all, no incontinence, normal miction healed, no stress

second obstetric leakage completely ok until PII (1 alive) live female in hosp

25.06.00 intrinsic incontinence III cath 562

28.08.00 not leaking at all cath removed bladder drill

24.09.00 not leaking at all, no incontinence, normal miction healed, no stress



4 cm

KANO
age at menarche: 13 yr

cath 500
 RVF 271

rilu (kano city) female 15 yr 02/06-98

diagnosis: PI, \pm 1 cm 0 urethrovesicovaginal fistula **IIAa** at midline, \pm 0.3 cm 0 rec
 tovaginal fistula midline at cervix, **leaking urine/passing flatus/soiling
 for 23 days** which started immediately following obstructed labor for 2
 days, at home SB male, married 2 yr ago post(menarche 3 mth earlier),
 not living with her husband, no menstruation. drop foot R (grade 4) and L
 (grade 4), no yankan gishiri; severe R convex scoliosis, normal AP
 diameter/pubis arch, malrotation/presentation
 EUO/F 1.5 cm, F/C 3 cm, I/F 12 cm, F/C 0 cm 147.0 cm

02/06-98 incision, dissection, transverse bladder/urethra closure by inverting
 chromic catgut, FOLEY Ch 18, transverse avw closure by 5x everting
 supramid; free urine flow, EUO/BW 11 cm, good elevation (rotational
 descent on catheter pull), EUO/B 1.5 cm anesthetic
 normal bladder capacity (longitudinal diameter 11-1.5 = 9.5 cm)
 good position UV-junction **against** middle/caudad third symphysis
 transverse cervix/pvw closure by 1x everting supramid; pack

- 05.05.98 leaking, stools ok cath removed bladder drill
 31.08.98 not leaking, incontinence \pm , normal miction stool ok
 insp/ **both** healed, good elevation, no stress incontinence
 22.11.98 idem R=4 L=4
 30.05.99 not leaking, incontinence \pm , miction healed, no stress R=5 L=5
 04/06-99 always leaking insp/ **fistula R lungu/avw traumatized midline**
what happened ??yankan gishiri??

